

# Harmine shows therapeutic activity on nicotine-induced liver failure in mice

Mohammad Reza Salahshoor<sup>1</sup>, Zahra Gholami mahmoudian<sup>1</sup>,  
Shiva Roshankhah<sup>1</sup>, Mehdi Farokhi<sup>1</sup> and Cyrus Jalili<sup>2</sup>

<sup>1</sup>Department of Anatomical Sciences, Medical School and <sup>2</sup>Medical Biology  
Research Center, Kermanshah University of Medical Sciences, Kermanshah, Iran

**Summary.** This experiment evaluated the effects of harmine against nicotine-induced damage to the liver of mice. Nicotine is a major toxic component of cigarette smoke and a major risk factor for functional disorders in the liver, because it induces oxidative stress. Harmine is a harmal-derived alkaloid with therapeutic and antioxidant properties. In this study, 80 male mice were randomly assigned to 10 groups: the normal control and nicotine control groups (2.5 mg/kg); the harmine groups (5, 10, 15, and 20 mg/kg), and the nicotine + harmine groups (5, 10, 15 and 20 mg/kg mg/kg). Treatments were administered intraperitoneally daily for 28 days. Nitric oxide (NO) level, aspartate aminotransferase (AST), alanine aminotransferase (ALT), and alkaline phosphatase (ALP) concentrations were determined. In addition, thiobarbituric acid reactive species, antioxidant capacity, and the diameters of the hepatocytes and central hepatic vein (CHV) were investigated. Nicotine administration significantly improved liver MDA and NO levels, CHV and hepatocyte diameters, and liver enzymes, and it decreased tissue FRAP levels compared to the normal control group ( $p < 0.05$ ). In the harmine and harmine + nicotine groups, in all dosages, all measured factors decreased significantly, while the FRAP tissue level increased compared with the nicotine control group ( $p < 0.05$ ). It seems that liver injury was improved by harmine administration in mice because of nicotine.

**Key words:** Harmine, Liver, Nicotine

## Introduction

Multiple complications related to the use of chemical drugs have shifted attention to natural and plant compounds that are effective in minimizing liver damages. Most plants leave very few side effects in patients (Salahshoor et al., 2016). *Peganum harmala*, called esband in Farsi, is a perennial and hairless plant from the Zygophyllacea family. In traditional medicine, numerous hypnotic, menstrual, appetizing, and anti-parasite effects have been reported for this plant (Herraiz et al., 2017). It contains various alkaloids, 12 types of which have been identified so far, including harmine, harmaline, harmalol, and peganin that are mainly observed in the root and seeds (Lamchouri et al., 2002). Harmine is a plant alkaloid from a beta-carboline family that is obtained from *Peganum harmala*. It has different pharmacologic effects on the nervous system as well as antioxidant and anticoagulant effects. It also affects the cardiovascular system with its vasodilatation properties (Im et al., 2009). The results of Cao et al. showed that harmine had cytotoxic activities against tumoral cells in humans (Cao et al., 2005). Nicotine is an alkaloid extracted from the dried leaves of the tobacco plant, and millions of people around the world are exposed to it through smoking (Jalili et al., 2017). Increased reactive oxygen species (ROS) can cause oxidative stress, which inactivates specific proteins by inducing DNA fragmentation, thereby destroying the biological membranes (Jalili et al., 2015). It seems that increased

Offprint requests to: Cyrus Jalili, PhD., Medical Biology Research Center, Kermanshah University of Medical Sciences, Daneshgah Ave, Taghbostan, Kermanshah, PO. Box 1568. Iran. e-mail: [cjalili@yahoo.com](mailto:cjalili@yahoo.com)

DOI: 10.14670/HH-18-122

oxidative stress plays a pivotal role in the pathology of liver diseases associated with smoking (Hattori et al., 2007). Salahshoor et al. reported that nicotine could induce oxidative stress in liver tissue (Salahshoor et al., 2016). The liver is known as the main site of nicotine biotransformation (Zhou et al., 2017). The toxicity caused by nicotine administration can induce inflammation, increase liver ulcers (fibrosis), and induce hepatitis C and hepatitis A (O'Brien et al., 2017). In addition, nicotine can damage liver cells by producing proinflammatory cytokines IL-1, IL-6, and TNF- $\alpha$  (Rahmioglu et al., 2009). It seems that oxidative stress plays a key role in toxic impairments of the liver (Martinez et al., 2017). Antioxidants found in food and the body can protect the body against different oxidative damages induced by oxygen free radicals (Roshankhah et al., 2017). Considering the effects of harmine and given that to date, no article has reported on the therapeutic activity of harmine against nicotine injuries in the liver, the present study was conducted to analyze the therapeutic role of harmine on damage induced by nicotine in the liver of Balb/c mice.

## Materials and methods

### Chemicals

In this experimental study, harmine (7-methoxy-1-methyl-9h-pyrido (C<sub>10</sub>H<sub>14</sub>N<sub>2</sub>)) powder was bought from Sigma (USA). The powder was diluted with saline (0.9%) to obtain the desired solution. Similarly, nicotine (CASName: 3-[(2S)-1-Methyl-2-pyrrolidinyl]pyridine) was purchased from Sigma (USA) and dissolved in saline (0.9%) for administration.

### Animals

Animal studies were conducted according to the guidelines for the care and handling of animals prepared by the Iranian Ministry of Health. A total of 64 Balb/c male mice (weighing 25-30 g) were purchased from Razi Institute (Iran). The animals were housed in standard cages (three per cage) and controlled conditions at 23±2°C and exposed to a 12/12 h light/dark cycle with free access to water and food in the Medical Sciences University's animal care facilities for a period of 1 week before testing (Najafi et al., 2015). All investigations conformed to the ethical and humane principles of research and were approved by the Ethics Committee of Medical Sciences (Ethics Certificate No.1395.203).

### Procedure design and treatments

The animals were randomly separated into 10 groups with 8 rats assigned to each group. The first group was investigated for salinity (the normal control group); the animals received normal saline through intraperitoneal injections equivalent to the number of injections received by the experimental groups. In the

second group, the Nicotine control group, each animal received a 2.5-mg/kg single-dose course of nicotine intraperitoneally once a day for 28 consecutive days (Salahshoor et al., 2016). The solvent of nicotine was normal saline. In the third, fourth, fifth and sixth groups, the harmine groups, each animal received 5, 10, 15, and 20 mg/kg, respectively, of harmine intraperitoneally daily for 4 weeks at 10 a.m. In the seventh to tenth groups, the nicotine + harmine groups, each animal received a single dose of 2.5 mg/kg nicotine in order to induce liver damage; then they respectively received (5, 10, 15, and 20 mg/kg) of harmine intraperitoneally for 4 weeks at 10 a.m. (Reus et al., 2010; Jalili et al., 2017).

### Dissection, sampling, and weight of liver

Twenty-four hours after the final injection, rats related to each group were placed one after another in a plastic container in a packet of cotton covered with ether. After a short time, due to inhalation of ether fumes, they were anesthetized. Venipuncture from the animals' hearts (right ventricle) was done using a 5-cc syringe. Blood samples were incubated for 15 min at 37°C so as to clot. Then, the clotted blood was centrifuged for 15 min at 3000 rpm until the serum was separated. The separated serum was stored at -70°C until some biochemical parameters of the liver, nitric oxide level, oxidative stress, and antioxidant capacity level were measured. Then, the animals' livers were removed and weighed on a microbalance sensitive to 0.001 mg (Precisa 125A, Switzerland), and mean weights were calculated and recorded. The livers were maintained in 10% formalin solution for histological and morphometric investigations (Jalili et al., 2017).

### Morphologic and histopathological examinations

For the histological evaluation of the hepatic buildings, transverse sections of the inferior 1-cm-long part of the right lobe of the liver were removed, washed in saline, and fixed in 10% formalin, dehydrated in ascending concentration ethanol, cleared in xylene, and then embedded in paraffin. Thin sections (4 mm) were cut using a microtome (Leica RM 2125, Germany) and marked with hematoxylin and eosin. For each hepatocyte, the full cellular area was measured. The hepatocyte outline was measured after capturing an image with a ×40 objective. The maximum and minimum axes were measured in the drawing of each hepatocyte to compute the mean axis. At least 50 hepatocytes from each zone were measured in each liver. A separate measurement for a central hepatic vein (CVH) was performed using the same assay. The planning was examined with an Olympus BX-51T-32E01 research microscope connected to a DP12 Camera with a resolution of 3.34 million pixels and Olysia Bio-software (Olympus Optical Co. LTD, Tokyo, Japan) (Salahshoor et al., 2016).

### Griess test

The Griess technique uses zinc sulfate powder to eliminate the serum protein in samples. Accordingly, zinc sulfate powder (6 mg) was mixed with serum samples (400  $\mu$ L) and vortexed for 1 min. The samples were centrifuged at 4°C for 10 min at 12,000 rpm, and the supernatant was used to measure the NO (Salahshoor et al., 2016).

### Biological factors

The liver was split and turned into a uniform solution. To separate the biological enzymes, the obtained solution was centrifuged at 10,000 rpm for 15 min twice. The supernatant was separated to measure the enzymes. Alanine aminotransferase (ALT) and aspartate aminotransferase (AST) actions were examined using the method of Reitman and Frankel. Alkaline phosphatase (ALP) actions were determined according to the procedure set out in the practical laboratory manual (Salahshoor et al., 2016).

### Oxidative stress

Oxidative stress was evaluated using colorimetric analysis. The thiobarbituric acid reactive species were measured by means of MDA as the last product of lipid peroxidation in liver tissue. The liver antioxidant capacity was measured by FRAP analysis. The FRAP substance contained 1.5 ml chloride ferric (Sigma, USA) and 30 ml of acetate buffer (Sigma, USA). Serial concentrations of  $\text{FeSO}_4 \cdot 7\text{H}_2\text{O}$  (Sigma, USA) were used as the external standard (Najafi et al., 2015).

### Statistical examination

After extracting the data, the Kolmogorov-Smirnov test was first conducted to confirm the data compliance

with normal distribution. One-way analysis of variance (one-way ANOVA) was used for statistical analysis, and the Tukey post hoc test was used to determine differences between the groups. Data was analyzed using SPSS 16; the results were expressed as mean  $\pm$  standard error, and  $p < 0.05$  was considered statistically significant.

## Results

### Liver weight

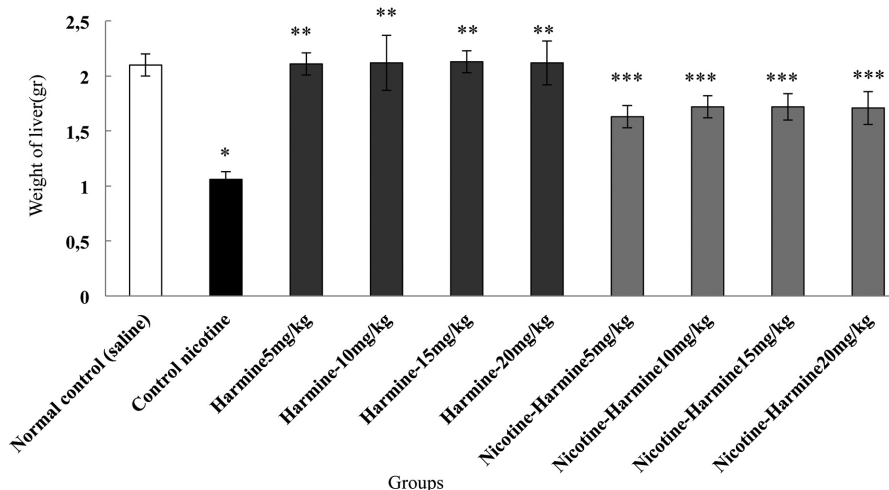
The effective dose of nicotine in the nicotine control group caused a significant reduction in the mean liver weight compared with the normal control group ( $p < 0.05$ ). The mean liver weight in all harmine groups was insignificant compared with the normal control group ( $p > 0.05$ ). Moreover, liver weight was augmented significantly in animals treated with harmine and harmine + nicotine in all doses compared with the nicotine control group (Fig. 1).

### Morphometric measurements

The mean diameter of hepatocytes and CHV in the experimental groups showed a significant increase between the normal control group and the nicotine control group ( $p < 0.05$ ). The mean diameter of hepatocytes and CHV was not significant in all harmine groups compared with the normal control group ( $p > 0.05$ ). Further, harmine and nicotine + harmine significantly reduced the mean diameter of hepatocytes and CHV in all treated groups compared with the nicotine control group ( $p < 0.05$ ) (Fig. 2).

### Histopathological changes

Histological analysis showed normal liver structures in the normal control and harmine groups. After



**Fig. 1.** Results of nicotine, harmine, and harmine + nicotine administration on liver weight; \*Significant reduction of weight in nicotine control group compared with control normal group ( $p < 0.05$ ); \*\*Significant growth in all harmine groups compared with the nicotine control group ( $p < 0.05$ ); \*\*\*Significant increase in all harmine + nicotine groups compared with the nicotine control group ( $p < 0.05$ ).

treatment with nicotine in the nicotine control group, the liver showed evident changes and injury. These anomalies included increased white blood cells (inflammation), increased irregularities, sinusoidal dilatation, and the vacuolization hepatocyte (necrosis). Treatment with nicotine + harmine at all doses reduced the liver damage caused by nicotine toxicity (Fig. 3).

## NO

The results of blood serum NO measurements showed a significant increase in the nicotine control group compared with the normal control group ( $p < 0.05$ ). The mean NO in the blood serum was insignificant in all harmine groups compared with the normal control group ( $p > 0.05$ ). Also, the mean NO in the blood serum was significantly reduced in all harmine and nicotine + harmine groups compared with the nicotine control group ( $p < 0.05$ ) (Fig. 4).

## Biological factors

Nicotine led to a significant increase in ALT, AST, and ALP enzymes compared with the normal control group ( $p < 0.05$ ). The mean ALT, AST, and ALP enzymes concentrations were insignificant in all harmine groups compared with the normal control group ( $p > 0.05$ ).

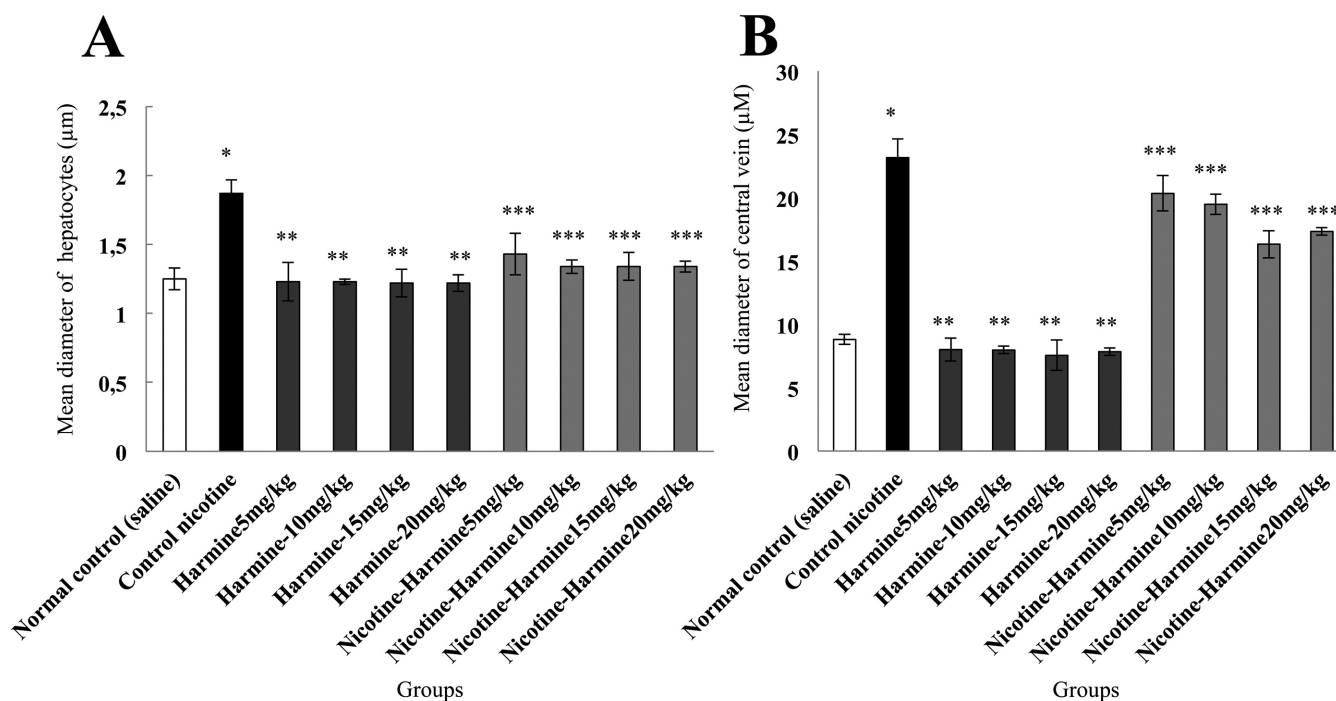
Furthermore, the mean ALT, AST, and ALP enzymes concentrations in all harmine and nicotine + harmine groups were significantly reduced compared with the nicotine control group ( $p < 0.05$ ) (Fig. 5).

## Oxidative stress

The results of oxidative stress testing showed that the liver MDA level was increased significantly in the nicotine control group compared with the normal control group ( $p < 0.05$ ), and the liver MDA level was significantly decreased in all nicotine + harmine groups compared with the nicotine control group ( $p < 0.05$ ). Similarly, nicotine significantly reduced the liver tissue FRAP level in the nicotine control group compared with the normal control group ( $p < 0.05$ ). Administration of harmine significantly increased the FRAP level in liver tissue in all nicotine + harmine groups compared with the nicotine control group ( $p < 0.05$ ). Treatment with harmine in all groups showed no significant differences in the liver tissue FRAPS and liver MDA levels compared with the normal control group ( $p > 0.05$ ) (Fig. 6).

## Discussion

Nicotine can increase hypertension, cardiovascular



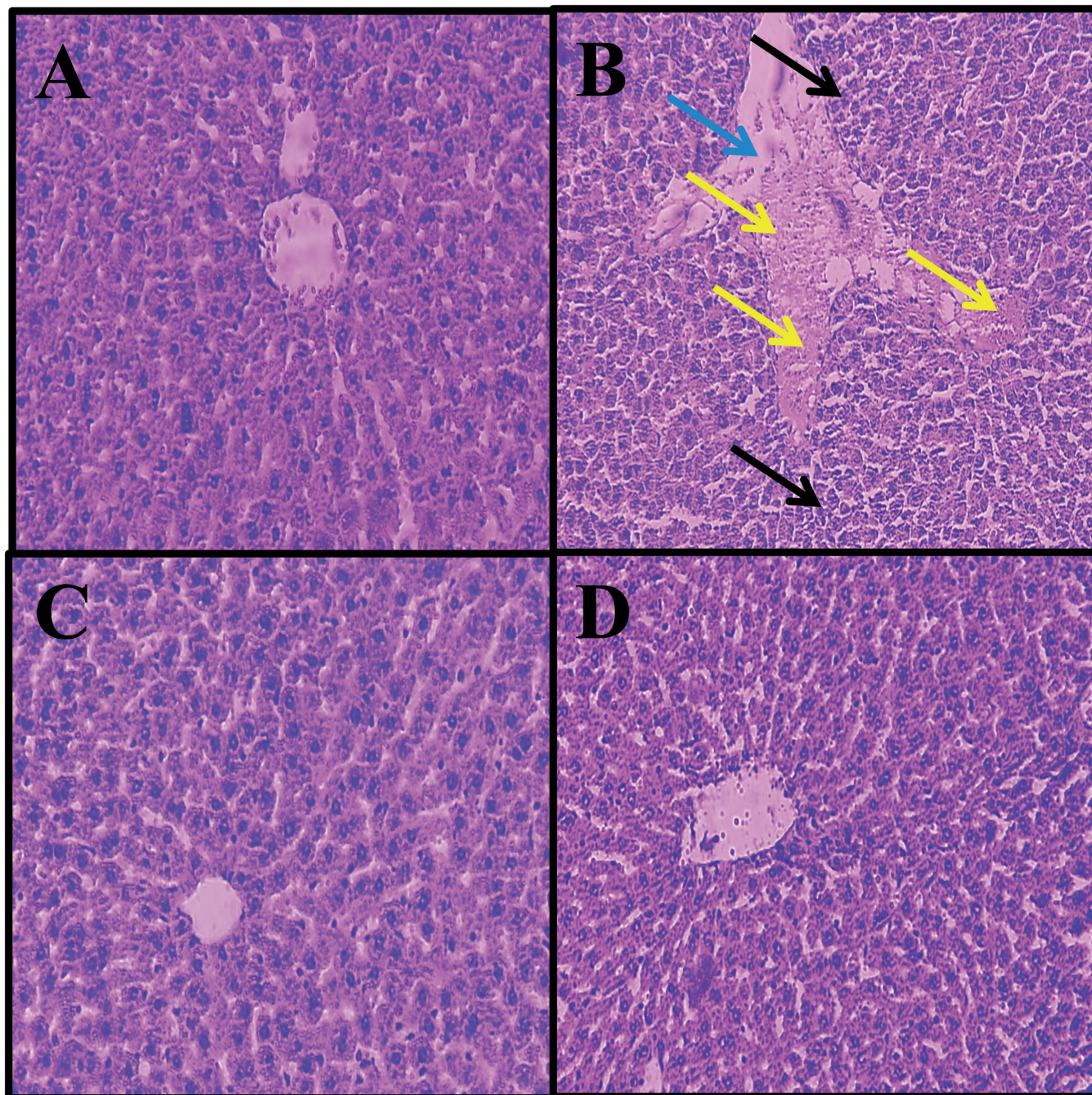
**Fig. 2.** Effects of nicotine, harmine, and harmine + nicotine administration on the diameter of hepatocyte (A) and CHV (B); \*Significant increase in the mean hepatocytes and CHV diameters in the nicotine control group compared with the normal control group ( $p < 0.05$ ); \*\*Significant decrease in all harmine groups compared with the nicotine control group ( $p < 0.05$ ); \*\*\*Significant decrease in all harmine + nicotine groups compared with the nicotine control group ( $p < 0.05$ ).



### *Harmine shows therapeutic activity on liver*

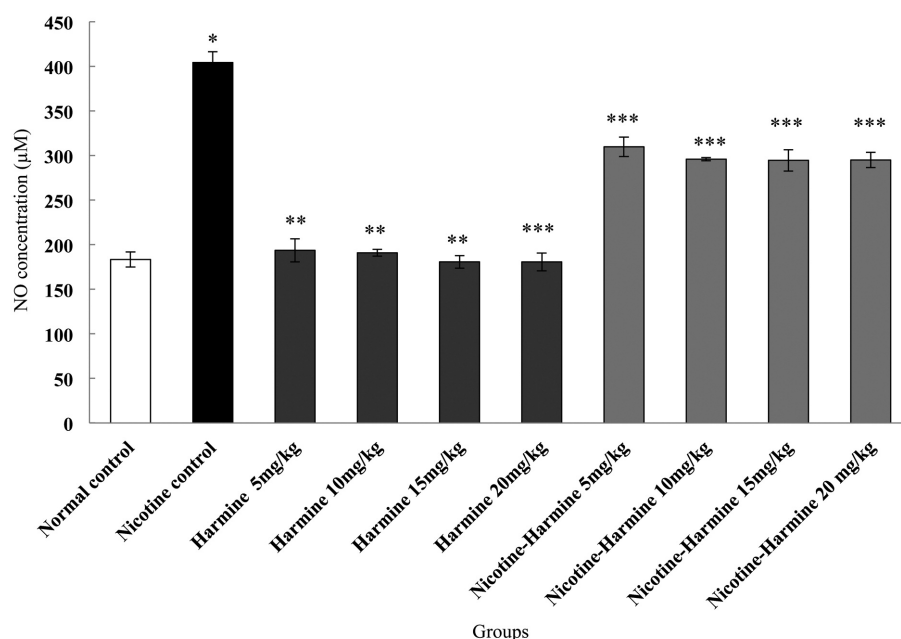
disorders, diabetes, hyperlipidemia, brain ischemia, and oxidative shock (Jalili et al., 2015). The liver detoxifies and inactivates materials through biotransformation

processes involving various enzymes (Giannini et al., 2005). Nicotine can lead to activation of stellate cells and progression of fibrosis in the liver by inducing

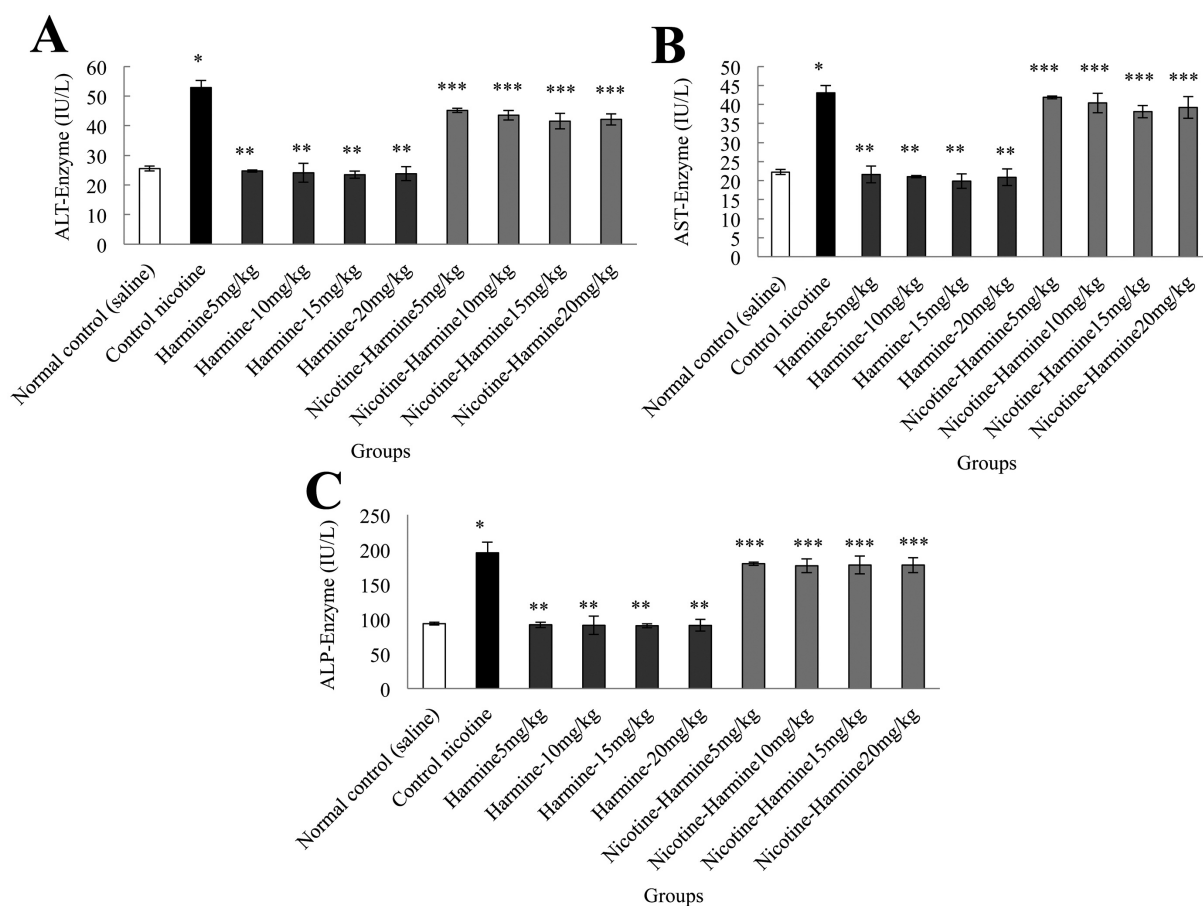


**Fig. 3.** Microscopic images of liver tissue in mature rats in different groups (5- $\mu$ m thick sections, H&E staining); Micrograph of the liver section in the normal control groups **(A)** normal liver structure. Micrograph of the liver section in the nicotine control group **(B)** increased white blood and macrophage cells (inflammation) (black arrows), and CHV dilatation (blue arrow) and hyperemia (yellow arrow), due to the oxidative stress caused by nicotine; Micrograph of the liver section in the harmine (15 mg/kg) group **(C)** normal liver structure; Micrograph of the liver section in the harmine + nicotine (15 mg/kg) group **(D)**, normal liver structure. x 100.

### Harmine shows therapeutic activity on liver



**Fig. 4.** Effects of harmine, nicotine, and harmine + nicotine on mean No levels; \*Significant increase in No in the nicotine control group compared with the normal control group ( $p < 0.05$ ); \*\*Significant decrease in all harmine groups compared with the nicotine control group ( $p < 0.05$ ); \*\*\*Significant decrease in all harmine + nicotine groups compared with the nicotine control group ( $p < 0.05$ ).

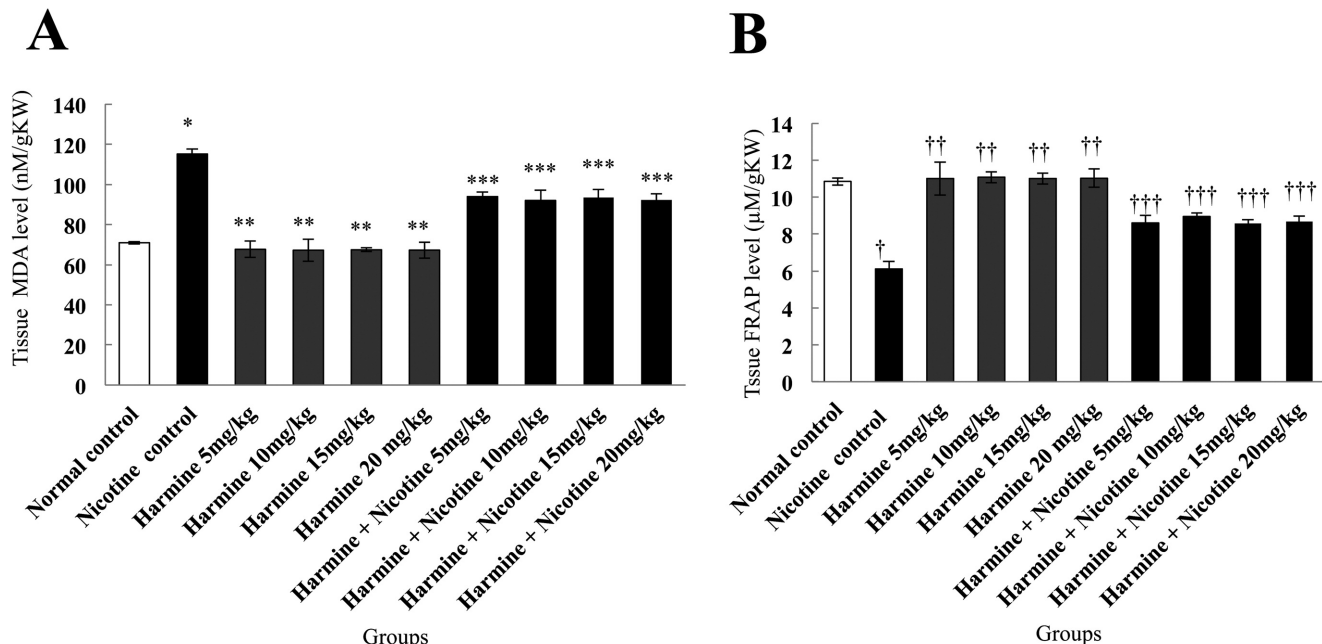


**Fig. 5.** Effects of nicotine, harmine, and harmine + nicotine administration on liver enzymes; ALT enzyme (A), AST enzyme (B) and ALP enzyme (C); \*Significant increase in enzymes in the nicotine control group compared with the normal control group ( $p < 0.05$ ); \*\*Significant decrease in all harmine groups compared with the nicotine control group ( $p < 0.05$ ); \*\*\*Significant decrease in harmine + nicotine groups compared with the nicotine control group ( $p < 0.05$ ).



oxidative stress and lipid peroxidation. Moreover, it seems that cigarette smoking can impair liver cells by producing proinflammatory cytokines IL-1, IL-6, and TNF- $\alpha$  (Salahshoor et al., 2016). Therefore, taking into account the spread of tobacco smoking, the present study investigated the pharmaceutical effect of harmine on nicotine-induced disorders in the liver. The findings showed that administration of nicotine reduced liver weight in comparison with the control normal group, while treatment with harmine and harmine + nicotine significantly increased the liver weight in all study groups compared with the nicotine control group. Since nicotine damages the liver and disturbs renal metabolism in mice, it can also decrease liver weight (Jalili et al., 2015). Nicotine can suppress food intake, reduce appetite, and increase the metabolic rate in the body by releasing hormones such as dopamine, serotonin, and gamma-aminobutyric acid (GABA) (Bellinger et al., 2010). Jalili et al. showed that nicotine administration caused liver damage, disturbance in real metabolism, and reduction in liver weight in mice, confirming the results of the present study (Jalili et al., 2017). It seems that harmine advances food absorption through attachment to diverse receptors as well as monoamine oxidase (MAO-A), serotonin 2A, and kinase-dependent syncline and plays an actual role in weight increase (Fortunato et al., 2010). The results of Hamden et al. confirm the results of the current study, demonstrating

that the prescription of peganum harmala improved weight loss in rats treated by thiourea (Hamden et al., 2007). The results of the current study indicated that nicotine significantly increased serum ALP, ALT, and AST levels in the experimental groups compared with the normal control group. Also, significant drops in serum ALT, AST, and ALP were observed in all harmine and harmine + nicotine groups compared with the nicotine control group. Currently, the measurement of enzymes like alanine aminotransferase and aspartate aminotransferase is among the methods applied for the diagnosis and analysis of liver damage (Dufour et al., 2000). Moreover, the serum levels of these enzymes are associated with liver function (Salahshoor et al., 2016). Nicotine seems to damage the membrane of liver hepatocytes, thereby releasing cytosolic enzymes of hepatocytes and consequently increasing these serums (Shakhanbeh et al., 2001). Nicotine can reduce the activity of antioxidant enzymes and induce the production of free radicals and ROS, thereby causing toxic effects such as damaging mitochondrial function and the Golgi apparatus of live cells through lipid peroxidation (Jalili et al., 2017). It seems that the effects of harmine are associated with the high capacity of this alkaloid to eliminate free radicals (Im et al., 2009). Diwan et al. reported that the administration of peganum harmala improved serum liver enzymes in rats treated with methotrexate, which is in line with the findings of



**Fig. 6.** Comparison of nicotine, saline, harmine + nicotine, and harmine groups of liver MDA level (A); tissue FRAP level (B); \*Significant increase in the nicotine control group compared with the normal control group ( $p < 0.05$ ); \*\*Significant decrease in all harmine groups compared with the nicotine control group ( $p < 0.05$ ); \*\*\*Significant decrease in all harmine + nicotine groups compared with the nicotine control group ( $p < 0.05$ ); †Significant decrease in the nicotine control group compared with the normal control group ( $p < 0.05$ ); ††Significant increase in all harmine groups compared with the nicotine control group ( $p < 0.05$ ); †††Significant increase in all harmine + nicotine groups compared with the nicotine control group ( $p < 0.05$ ).

the present study (Diwan et al., 2013). The morphometric findings of the analysis of the diameter of hepatocytes and measurement of the CHV in the study groups showed a significant increase in the nicotine control group compared with the normal control group. The diameter of hepatocytes and CHV in the harmine and harmine + nicotine groups reduced significantly compared with the nicotine control group. Furthermore, nicotine administration induced cytoplasmic degradation in necrotic areas and caused changes in the nucleus of cells. Necrosis in liver cells along with the accumulation of inflammatory cells was also observed in histological analyses. The changing size of hepatocytes can be a sign of increased metabolic activity. Also, it seems that the necrosis of hepatocytes in the nicotine groups can be caused by the increased activity to excrete toxins from the body during the detoxification process (Sakr, 2007). Lipid peroxidation and production of extra free radicals due to nicotine intake can impair the proteins and DNA and induce apoptosis (Salahshoor et al., 2016). Inflammation can intensify tubular and vascular damage by increasing the generation of substances such as ROS and peroxynitrite (Najafi et al., 2015). Nicotine seems to form ROS by terminating the activity of antioxidant enzymes and lipid peroxidation, thereby inducing mitochondrial pathway apoptosis and DNA damage in liver cells (Jalili et al., 2015). The effects of harmine in reducing liver enzymes seem to be due to its antioxidant activities. Harmine is one of the natural compounds found in the beta-carboline alkaloids family (Ishida et al., 1999). Beta-carbolines can exert their antioxidant effects by inhibiting lipid peroxidation in hepatic microsomal enzymes (Atteya et al., 2017). Moura et al. reported that beta-carbolines had antioxidant and protective effects against oxidative stress in yeast cells, confirming the results of the present study (Moura et al., 2007). In the current research, nicotine administration increased NO in the nicotine control group. Treatment with harmine and harmine + nicotine significantly reduced NO level compared with the nicotine control group. NO is a free radical that is produced in mammalian cells and is involved in the regulation of physiological processes (Jalili et al., 2016). Absorption of nicotine in the body is accompanied by a rise in serum NO and oxidative stress. The hydroxyl radicals produced by NO can interfere with the pathogenesis process and liver toxicity (Jalili et al., 2015). Harmine, as an antioxidant, can damage the NO system (i.e. protein enzymes, substrates, and cofactors). It seems that these substances inhibit NF- $\kappa$ B and proinflammatory mediators and induce the production of NO, TNF- $\alpha$ , and TGF- $\beta$ 1 (Wood et al., 1990). The results of Berrougui et al. showed that harmine had no effect on NO, which is in contrast with the findings of the current study (Berrougui et al., 2006). On the other hand, El Madani et al. reported that intraperitoneal administration of harmine significantly reduced serum NO in mice treated by rotenone, confirming the results of the present study (El Madani et al., 2016). The results of the present study

also showed that harmine is able to reduce lipid peroxidation (decreased MDA) and increase the antioxidant capacity (increased FRAP) of liver tissue, thereby reducing oxidative stress. Consistent with these findings, a large body of studies has shown anti-oxidant properties for harmine. Therefore, it appears that harmine with its anti-oxidant properties could reduce MDA and increase FRAP in the treatment groups by inhibiting the production of reactive oxygen species. Further studies are required to identify the exact cellular and molecular mechanisms involved in the pharmacological function of harmine extract in the therapeutic activity of nicotine-induced liver damage, with the etiology of increased oxidative stress, in order to determine the potential effects this extract may have.

### Conclusions

It appears that harmine might improve some liver damage in mice treated with nicotine. Hence, harmine could be appreciated for healing the livers of persons exposed to nicotine. The antioxidant properties of harmine can be a chief reason for its positive result on liver factors. However, supplementary studies are necessary to accurately describe their mechanisms of action.

**Acknowledgements.** We are grateful to the Research Council of Kermanshah University of Medical Sciences (No: 95203) for their financial support.

**Conflict of Interest.** None declared.

### References

- Atteya R., Ashour M.E., Ibrahim E.E., Farag M.A. and El-Khamisy S.F. (2017). Chemical screening identifies the  $\beta$ -Carboline alkaloid Harmine to be synergistically lethal with doxorubicin. *Mech Ageing Dev.* 161, 141-148.
- Bellinger L., Wellman P., Harris R., Kelso E. and Kramer P. (2010). The effects of chronic Nicotine on meal patterns, food intake, metabolism and body weight of male rats. *Pharmacol. Biochem. Behav.* 95, 92-99.
- Berrougui H., Martín-Cordero C., Khalil A., Hmamouchi M., Ettaib A., Marhuenda E. and Herrera M.D. (2006). Vasorelaxant effects of Harmine and harmaline extracted from *Peganum harmala* L. seed's in isolated rat aorta. *Pharmacol. Res.* 54, 150-157.
- Cao R., Peng W., Chen H., Ma Y., Liu X., Hou X., Guan H. and Xu A. (2005). DNA binding properties of 9-substituted Harmine derivatives. *Biochem. Biophys. Res. Commun.* 338, 1557-1563.
- Diwan S.Y. (2013) Effect of *Peganum harmala* methanol extract on liver and kidney of mice administered MTX drug. *Iraqi J. Med. Sci.* 16, 161-166.
- Dufour D.R., Lott J.A., Nolte F.S., Gretch D.R., Koff R.S. and Seeff L.B. (2000). Diagnosis and monitoring of hepatic injury. I. Performance characteristics of laboratory tests. *Clin. Chem.* 46, 2027-2049.
- El Madani M., Attia A. and El-Shenawy S. (2016). Neuropharmacological effects of naringenin, harmine and adenosine on parkinsonism induced in rats. *Der Pharmacia Lettre.* 8, 45-57.



## Harmine shows therapeutic activity on liver

- Fortunato J.J., Réus G.Z., Kirsch T.R., Stringari R.B., Fries G.R., Kapczinski F., Hallak J.E., Zuardi A.W., Crippa J.A. and Quevedo J. (2010). Effects of  $\beta$ -carboline Harmine on behavioral and physiological parameters observed in the chronic mild stress model: Further evidence of antidepressant properties. *Brain Res. Bull.* 81, 491-496.
- Giannini E.G., Testa R. and Savarino V. (2005). Liver enzyme alteration: a guide for clinicians. *Can. Med. Assoc. J.* 172, 367-379.
- Hamden K., Masmoudi H., Ellouz F., ElFeki A. and Carreau S. (2007). Protective effects of *Peganum harmala* extracts on thiourea-induced diseases in adult male rat. *J. Environ. Biol.* 29, 73.
- Hattori N., Nomoto H., Fukumitsu H., Mishima S. and Furukawa S. (2007). AMP N1-oxide potentiates astrogenesis by cultured neural stem/progenitor cells through STAT3 activation. *Biomed. Res.* 28, 295-299.
- Herraz T., Guillén H., Arán V.J. and Salgado A. (2017). Identification, occurrence and activity of quinazoline alkaloids in *Peganum harmala*. *Food Chem. Toxicol.* 103, 261-269.
- Im J.H., Lee J.J., Yu J.Y., Han X.H., Im S.H., Hong J.T., Yoo H.S., Pyo M.Y. and Yun Y.P. (2009). Antiplatelet activity of beta-carboline alkaloids from *Peganum harmala*: A possible mechanism through inhibiting PLCgamma2 phosphorylation. *Vascul. pharmacol.* 50, 147-152.
- Ishida J., Wang H.K., Bastow K.F., Hu C.Q. and Lee K.H. (1999). Antitumor agents 201. 1 Cytotoxicity of Harmine and  $\beta$ -carboline analogs. *Bioorg. Med. Chem. Lett.* 9, 3319-3324.
- Jalili C., Tabatabaei H., Kakaberiei S., Roshankhah S.H. and Salahshoor M.R. (2015). Protective role of crocin against nicotine-induced damages on male mice liver. *Int. J. Prev. Med.* 6, 92.
- Jalili C., Sharareh A., Roshankhah S.H. and Salahshoor M.R. (2016). Preventing effect of genistein on reproductive parameter and serum nitric oxide levels in morphine-treated mice. *Int. J. Reprod. BioMed.* 14, 95-102.
- Jalili C., Salahshoor M.R., Moradi M.T., Ahookhash M., Taghadosi M. and Sohrabi M. (2017). Expression changes of apoptotic genes in tissues from mice exposed to nicotine. *Asian Pac. J. Cancer Prev.* 18, 239-244.
- Lamchouri F., Settaf A., Cherrah Y., El Hamidi M., Tligui N., Lyoussi B. and Hassar M. (2002). Experimental toxicity of *Peganum harmala*. *Ann. Pharm. Fr. R.* 60, 123-129.
- Martinez S.S., Campa A., Li Y., Fleetwood C., Stewart T., Ramamoorthy V. and Baum M.K. (2017). Low plasma zinc is associated with higher mitochondrial oxidative stress and faster liver fibrosis development in the Miami adult studies in HIV cohort. *J. Nutr.* 147, 556-562.
- Moura D.J., Richter M.F., Boeira J.M., Pêgas Henriques J.A. and Saffi J. (2007). Antioxidant properties of  $\beta$ -carboline alkaloids are related to their antimutagenic and antigenotoxic activities. *Mutagenesis* 22, 293-302.
- Najafi H.O., Ashtiyani S.C., Madani S.H., Fakhri S.A., Yarijani Z.M. and Hazem M.E. (2015). Therapeutic effects of Curcumin on renal tissue damages induced by ischemia reperfusion in rat. *Koomesh* 16, 273-281.
- Wood P.L., Emmett M.R., Rao T.S., Cler J., Mick S. and Iyengar S. (1990). Inhibition of nitric oxide synthase blocks N-methyl-D-aspartate-, quisqualate-, kainate-, harmaline-, and pentylene-tetrazole-dependent increases in cerebellar cyclic GMP *in vivo*. *J. Neurochem.* 55, 346-348.
- O'Brien A., Ehrlich L., Hall C., White T., Dostal D., Alpini G. and Glaser S. (2017). Chronic administration of nicotine increases biliary damage and hepatic fibrosis in Mdr2 knockout (KO) mice. *FASEB J.* 31, 804-809.
- Rahmioglu N., Cherkas L., Surdulescu G., Swaminathan R., Spector T. and Ahmadi K.R. (2009). Epidemiology and genetic epidemiology of the liver function test proteins. *PLoS One* 4, e4435.
- Réus G.Z., de Souza B., Petronilho F., Dal-Pizzol F., Hallak J.E., Zuardi A.W., Crippa J.A. and Quevedo J. (2010). Harmine and imipramine promote antioxidant activities in prefrontal cortex and hippocampus. *Oxid Med. Cell Longev.* 3, 325-331.
- Roshankhah S.H., Salahshoor M.R., Aryanfar S., Jalili F., Sohrabi M. and Jalili C. (2017). Effects of curcumin on sperm parameters abnormalities induced by morphine in rat. *J. Med. Biomed Sci.* 6, 1-10.
- Salahshoor M.R., Mohamadian S., Kakabaraei S., Roshankhah S.H. and Jalili C. (2016). Curcumin improves liver damage in male mice exposed to nicotine. *J. Tradit Complement. Med.* 176-183.
- Salahshoor M.R., Roshankhah S., Hosseini P. and Jalili C. (2018). Genistein improves liver damage in male mice exposed to morphine. *Chin. Med. J.* 131, 1598-1604.
- Shakhanbeh J. and Adigüzel O. (2001). *Teucrium polium* inhibits nerve conduction and carrageenan induced inflammation in the rat skin. *Turk. J. Med. Sci.* 31, 15-21.
- Sakr S.A. (2007). Ameliorative effect of ginger (*Zingiber officinale*) on mancozeb fungicide induced liver injury in albino rats. *Australian J. Basic Appl. Sci.* 1, 650-656.
- Wood P.L., Emmett M.R., Rao T.S., Cler J., Mick S. and Iyengar S. (1990). Inhibition of nitric oxide synthase blocks N-methyl-D-aspartate-, quisqualate-, kainate-, harmaline-, and pentylene-tetrazole-dependent increases in cerebellar cyclic GMP *in vivo*. *J. Neurochem.* 55, 346-348.
- Zhou Z., Park S., Kim J.W., Zhao J., Lee M.Y., Choi K.C., Lim C.W. and Kim B. (2017). Detrimental effects of nicotine on thioacetamide-induced liver injury in mice. *Toxicol. Mech. Meth.* 27, 501-510.

Accepted May 3, 2019