

Safety of isotretinoin treatment as measured by liver parameters

B.F. Thomazini, C.A. Lamas and M.A.H. Dolder

Department of Structural and Functional Biology, Biology Institute, University of Campinas, Campinas, SP, Brazil

Summary. Isotretinoin is an analogue of vitamin A and by suppressing the sebaceous glands it is often prescribed in cases of severe acne treatment. The treatment for the average patient is carried out during two to ten months. This study was designed to investigate liver structure, hepatic enzyme levels and the stress oxidative parameter after isotretinoin treatment during a similar period and using the dosages of 1 mg/kg and another one of 10 mg/kg in young male Wistar rats. We have analyzed the blood serum biochemical levels to determine hepatic function and lipid peroxidation, hepatic tissue levels of hepatic enzymes, histology and ultrastructure. The groups receiving 1 mg/kg were not altered after treatment. Their ultrastructure showed a metabolically more active organ after treatment with 10 mg/kg, in which there was an increase in the area occupied by mitochondria and rough reticulum in electron transmission images. The group that received 10 mg/kg also showed increased alkaline phosphatase, decreased high density lipoprotein and low density lipoprotein. The changes observed with the 10 mg/kg dose were not conclusive for liver damage, because of the lack of histological structural modifications and the few biochemical alterations. The 1 mg/kg dose showed a liver responding to some stimuli but without profound

alterations. So, we confirm that the proposed protocol with 1 mg/kg or 10 mg/kg isotretinoin did not cause important biochemical and histological disfunctions for male Wistar rat livers.

Key words: Liver, Histology, Morphometry, Wistar rats

Introduction

Isotretinoin is a member of the Vitamin A family that is a highly effective therapeutic agent for acne treatment. Vitamin A is a retinol, a fat soluble molecule with potent effects on epithelium tissue growth and differentiation and is critical to the proper maintenance of epithelial integrity and structure (Hardman et al., 1996; Jacob et al., 2001; Madeira et al., 2012). Isotretinoin acts reducing sebaceous gland size by decreasing the proliferation of basal sebocytes. This action suppresses sebum production and inhibits sebocyte differentiation (Zouboulis et al., 1991).

Isotretinoin is one of the most effective drugs for acne vulgaris treatment and has a positive effect when we consider that less than 1% of patients have a relapse after one cycle employing the appropriate dosage (Diniz et al., 2002; Charakida et al., 2004; Sampaio, 2008; Rigopoulos et al., 2010; Vieira and Beijamini, 2012; Owen, 2014). This substance is also indicated for the treatment of rosacea, gram-negative folliculitis, lupus erythematosus, sebaceous hyperplasia, psoriasis and others diseases (Lowenstein and Lowenstein, 2011). The determination of this dosage depends on various factors

Offprint requests to: Bruna Fontana Thomazini, Departamento de Biologia Estrutural e Funcional, Instituto de Biologia, Universidade Estadual de Campinas- UNICAMP, Avenida Bertrand Russel, Bloco N, Zeferino Vaz, Campus- Barão Geraldo. CEP: 13083-865, Campinas – São Paulo – Brasil. e-mail: bruna.fth@gmail.com

DOI: 10.14670/HH-18-075

but the usual dosage recommended is 0.5-1.2 mg/kg/day for two to ten months (Diniz et al., 2002; Charakida et al., 2004; Sampaio, 2008; Brito et al., 2010; Brzezinski et al., 2017). The once daily dose seems to be more convenient and therefore encourages more patient compliance (Ahmad, 2015). Previous authors indicate that the cumulative dose is more important than the daily dose to achieve and maintain remission of the disease (Vieira and Bejamini, 2012).

Isotretinoin shows great therapeutic efficiency in induction of epithelial differentiation, and mucus secreting tissue. The inhibition of sebum production by isotretinoin is a determining factor for its pharmacological activity in the treatment (Allen and Bloxham, 1989; Saurat, 1997; Diniz et al., 2002; Sampaio, 2008; Alli and Yorulmaz, 2015; Kizlyel et al., 2014).

The treatment with retinoids, including isotretinoin, may lead to alterations of liver enzyme and lipid levels. The most common laboratory findings after oral isotretinoin treatment is hypertriglyceridemia (Lowenstein and Lowenstein, 2011). Other effects may include increased serum levels of liver enzymes, increased total cholesterol, low-density lipoprotein cholesterol and reduced high density lipoprotein cholesterol levels (Nankervis et al., 1995; White, 1999; Lowenstein and Lowenstein, 2011; Vieira and Bejamini, 2012; Blasiak et al., 2013; Kizilyel et al., 2014; Owen, 2014; Lee et al., 2016).

The effects of isotretinoin treatment, showing higher serum enzyme and lipid profiles, has been linked with liver injuries, as is well described in the literature. However the effect on liver histology is not so well described. In the research literature we did not find previous descriptions of liver histology and ultrastructural effects using the protocol as we proposed. So, the aim of this study was to investigate the effects in the blood serum and liver biochemical analysis, and also on liver histology structure and ultrastructure after treatment with two dosages of isotretinoin solution in young male Wistar rats.

Materials and methods

Experimental groups

Male Wistar rats (*Rattus norvegicus*) (n=24) initiated the experimental protocol aged 21 days when were randomly allocated into 4 experimental groups (n=6): C (control with water); D0 (control with soybean oil, the vehicle), D1 (1 mg/kg) and D10 (10 mg/kg) and maintained until reached 54 days. The protocol was designed to compare the isotretinoin dose dependent effects after 60 days of treatment which is the minimum period used in human treatment. The 1 mg/kg dosage is proportional to the frequently applied dosage and the 10 mg/kg dosage is still proportional to treatments which have been prescribed besides being higher and not toxic (Rademaker, 2013; Kotori, 2015; Chiu and Chen, 2017;

Karadag et al., 2017; Yap, 2017). The experimental protocol with the solutions of isotretinoin diluted in soybean oil (Nankervis et al., 1995) to obtain the desired concentrations started when rats reached 54 days of age with daily gavage for 60 days.

The experiment followed the established ethical standards according to the Brazilian animal protection laws (CEUA/Unicamp/Brazil protocol #2831-1). The rats had free access to rodent food and water and the animal house had controlled luminosity with 12 hours of light/dark and temperature at about $22\pm 1^\circ\text{C}$.

Blood extraction and plasma biochemistry

After the 60 days of treatment the rats were euthanized with a mixture of 10 mg/kg of ketamine and 80 mg/Kg of xylazin solutions. After anesthesia, blood was collected from the right ventricle using a vacuette tube. The blood was immediately centrifuged for 10 min at a speed of 3500 rpm at 4°C . The supernatant plasma was collected and frozen at -20°C . The plasma was processed as routine samples to determine the level of the following components: aspartate aminotransferase, alanine aminotransferase, total bilirubin, direct bilirubin, indirect bilirubin, alkaline phosphatase, gamma-glutamyl transferase, total cholesterol, total triglycerides, high density lipoprotein cholesterol, low density lipoprotein cholesterol, very-low-density lipoprotein cholesterol, total protein, albumin, globulin and malondialdehyde.

Liver extraction: Tissue biochemistry, light and electron microscopies

The liver was collected, the organ mass measured and smaller sections were prepared. Some fragments were frozen at -80°C , others were processed according to light microscopy and transmission electron microscopy routines.

Light microscopy routines were the usual ones for paraffin and glycol methacrylate Leica® embedding. The samples embedded in glycol methacrylate were sectioned with $2\ \mu\text{m}$ thickness (8 sections and distance of $30\ \mu\text{m}$ between them) and stained with Hematoxylin-Eosin, for morphometry data. The samples embedded in paraffin were sectioned at $5\ \mu\text{m}$ thickness (8 sections and distance of $30\ \mu\text{m}$ between them) stained with Masson's Trichrome, to observe the distribution of connective tissue, epithelium and muscle, or employing a combination of Periodic Acid Schiff (PAS) with Alcian Blue (AB) pH 2.5 (PAS+AB) (Alcian Blue pH 2.5-PAS®, EasyPath) to show areas with mucin deposition, or with Reticulin (Reticulina®, EasyPath) to reveal reticulin fiber distribution and structure. For transmission electron microscopy, the usual routine for Epon® embedding was employed. This tissue was sectioned at a thickness of 70 nm and was typically stained with uranyl acetate followed by lead citrate.

To investigate the oxidative stress level and liver integrity we measured the following enzyme or protein

A dose dependent study

levels in liver tissue samples: Superoxide Dismutase (Superoxide Dismutase Assay Kit Cayman Chemicals® Cat #706002), Catalase (Catalase Assay kit- Sigma Aldrich® Cat #100-1KT), Alkaline Phosphatase (Fosfatase Alcalina Bioclin® Cat #K019), Total Glutathione (Kit Sigma Aldrich Glutathione Assay® Cat#CS0260- 1KT), Gamma-Glutamyl Transferase (Gama Glutamyl Transferase Laborlab® Cat#09900), Aspartate Aminotransferase (Transaminase Oxalacética InVitro® Cat #015), Alanine Transaminase (Transaminase Pirúvica InVitro® Cat #016), Bradford protein assay (Bio-Rad Protein Assay® Cat #500-0006) and Malondialdehyde (TBars Assay Kit Cayman Chemicals® Cat #10009055).

Qualitative and quantitative observations

Images of liver samples stained with Hematoxylin and Eosin were captured at 400x magnification and 10 aleatory fields were selected. These fields were located around the centrilobular vessel for all animals. Using the software Image Pro Plus® (Media Cybernetics, version 4.5.0.29), the cell height and nuclear diameter of 30 hepatocytes were measured. In the same fields, a grid mask with 266 intersections was applied, quantifying a total of 2660 intersections per animal. Each intersection was classified according to the following parameters: binuclear and mononuclear hepatocytes, cytoplasm area, connective tissue, sinusoid vessels, connective tissue cells, lipid droplets and blood vessels. Thus, based on the total number of intersections per animal these parameters were quantified and expressed as relative percentage.

For samples stained with Masson's Trichrome, AB+PAS and Reticulin, we performed a qualitative evaluation observing tissue structure and organization.

Using transmission electron microscopy, we performed a more specific evaluation observing the connective tissue components as well as the cytoplasmic organelles, endoplasmic reticulum, mitochondria and Golgi complex morphology, distribution and frequency.

Statistical analysis

For multiple comparison, we applied the Kruskal-Wallis test followed by Dunn's post test. The level of significance applied was $p < 0.05$. We used Minitab® 16 program (LEAD Technologies, Inc. Charlotte, North Carolina) and the data are presented as mean \pm standard deviation in the tables.

Results

There were no significant macroscopic alterations in the liver, observed after euthanasia (Table 1). The morphometrical parameters of hepatocytes showed no difference after the treatment protocol (Table 1, Fig. 1). The frequency of hepatocytes, cytoplasm areas, connective tissue, blood vessels, connective tissue cells and lipid droplets showed no difference among the groups (Table 1, Fig. 1). The biochemical evaluation of liver tissue (Table 2) showed a decrease in Superoxide Dismutase in the D1 group in relation to C group, and an increase in Alkaline phosphatase in the D10 group in relation to the D0 control. The other enzymes, Total Glutathione, Gamma-Glutamyl Transferase, Aspartate Aminotransferase, Alanine Transaminase showed no significant difference. Protein quantification based on the Bradford method showed no variation, as was also found for lipid peroxidation based on malondialdehyde determination.

Serum biochemical analysis (Table 2) showed

Table 1. Morphometry and stereology of Wistar rat livers treated with 1mg/kg and 10mg/kg of isotretinoin for 60 days.

Groups	C- control with water	D0- control with soybean oil	D1-1mg/Kg of isotretinoin	D10- 10mg/kg of isotretinoin
Initial body weight (g)	192.82 \pm 13.96	193.50 \pm 10.17	193.46 \pm 15.24	192.78 \pm 3.80
Final body weight (g)	468.43 \pm 40.15	459.44 \pm 53.34	466.68 \pm 22.54	474.25 \pm 41.73
Liver mass (g)	12.89 \pm 0.97	12.82 \pm 1.44	12.97 \pm 1.41	14.21 \pm 1.65
Hepatocyte morphometry and stereology				
Hepatocyte diameter (μ m)	22.25 \pm 8.11	21.54 \pm 1.44	21.33 \pm 0.31	22.51 \pm 1.13
Hepatocyte nuclear diameter (μ m)	9.39 \pm 3.34 ^a	7.18 \pm 0.58 ^{ab}	6.85 \pm 0.53 ^b	7.63 \pm 0.68 ^{ab}
Liver stereology				
Binuclear hepatocyte (%)	0.30 \pm 0.25	0.20 \pm 0.10	0.17 \pm 0.09	0.08 \pm 0.10
Mononuclear hepatocyte (%)	5.83 \pm 0.66	5.43 \pm 0.61	6.05 \pm 1.36	4.80 \pm 0.63
Cytoplasmic (%)	90.53 \pm 1.84	90.03 \pm 3.45	91.18 \pm 1.30	92.28 \pm 2.25
Connective tissue (%)	1.44 \pm 0.85	2.23 \pm 2.00	1.01 \pm 0.35	0.95 \pm 0.75
Sinusoid vessel (%)	0.86 \pm 0.50	1.00 \pm 0.55	0.86 \pm 0.56	0.80 \pm 0.74
Connective tissue cell (%)	0.22 \pm 0.09	0.14 \pm 0.11	0.21 \pm 0.12	0.24 \pm 0.13
Lipid droplets (%)	0.06 \pm 0.09	0.23 \pm 0.24	0.09 \pm 0.12	0.02 \pm 0.05
Blood vessel (%)	0.75 \pm 0.98	0.74 \pm 0.78	0.43 \pm 0.59	0.82 \pm 1.00

Mean \pm standard deviation. Averages in the same row followed by different letters differ statistically by the Kruskal-Wallis test followed by Dunn's post test at a 5% significance level.

A dose dependent study

changes related to the D10 group. We observed increased triglyceride and very low density lipoprotein levels in relation to the D0 control. A decrease in high density lipoprotein and low density lipoprotein levels in D10 in relation to the controls C and D0 was also observed. For plasma protein, a decrease in the D10 group of total proteins and albumin occurred in relation to the control D0. The D1 group showed fewer modifications and they are related to an increase of alkaline phosphatase and a decrease of gamma glutamyl transferase in relation to the control C.

The stain analyses showed no tissue organization difference among the groups (Fig. 1). Transmission electron microscopy showed the expected distribution of cytoplasmic elements and some changes related to the

treatment. A higher area of rough endoplasmic reticulum and mitochondria was observed as being dose dependent, increasing in D10 group in relation to D1 group. Lipid droplet distribution and the area they occupied, tight junctions, defense cells, and connective tissue elements showed no qualitative difference in morphology or distribution among the groups (Fig. 2).

Discussion

In general, the treatment with isotretinoin has been claimed to cause alterations in blood serum levels of liver enzymes and lipid particles increasing serum levels of liver enzymes, triglycerides, total cholesterol and low-density lipoprotein, and it may reduce the level of high-

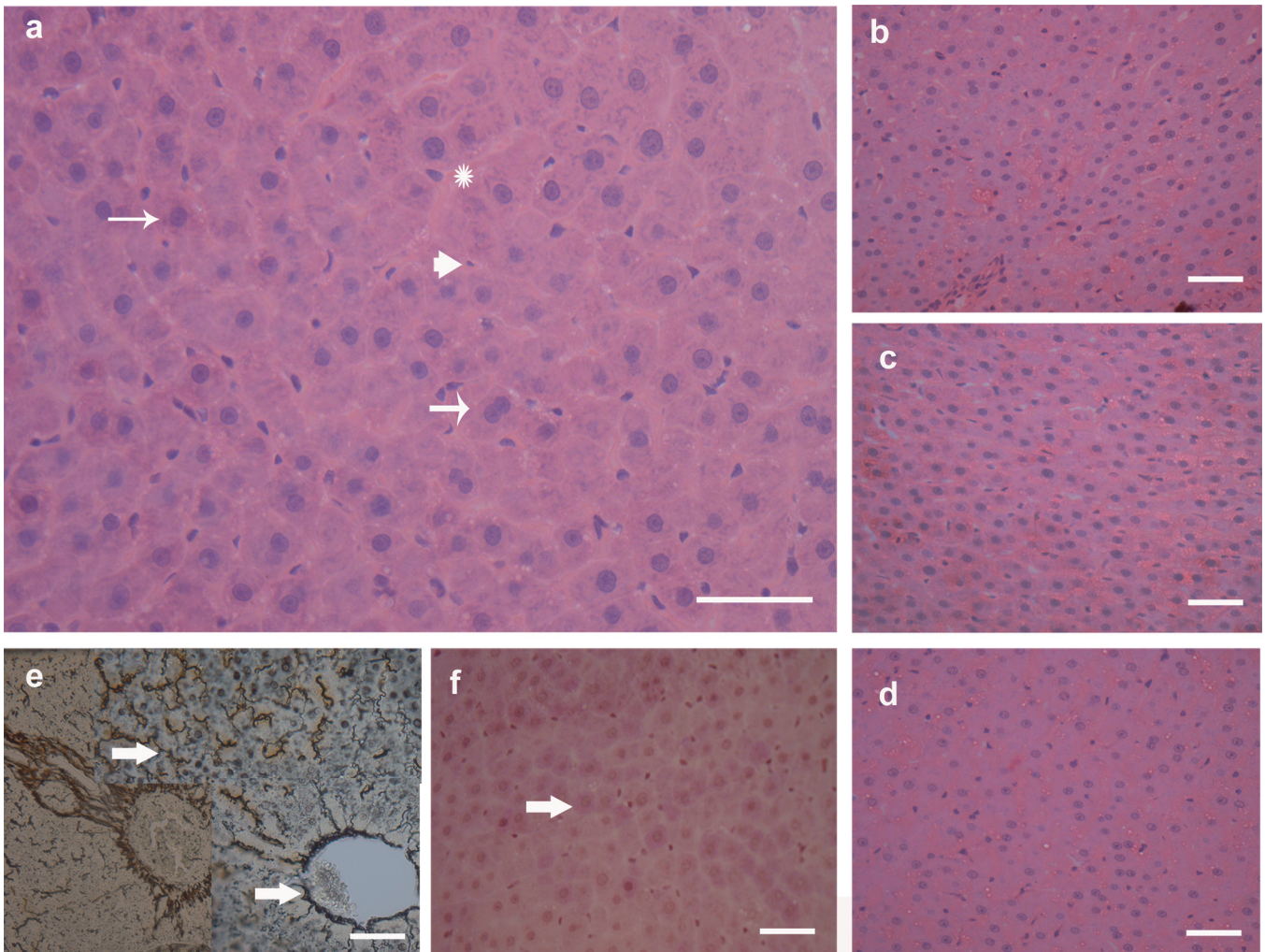


Fig. 1. Light microscopy images of the liver. **a-d.** Hematoxylin-Eosin staining. In image **a** we have the control group, chosen as an example to show the usual histological structures of liver. The thin arrow indicates a mononuclear hepatocyte; the thicker arrow indicates a binuclear hepatocyte. the arrowhead indicates a defense cell in the connective tissue. the asterisk (*) indicates the lymphatic space. **b.** Group D0. **c.** Group D1. **d.** Group D10. **e.** Reticulin in the control group. The arrows indicate the fibers providing support for the tissue and around the central vein of the liver lobule. **f.** Combination technique of PAS+AB in the control group. The arrow indicates the usual glycogen deposit in hepatocyte cytoplasm. Scale bars: 50 μm.

A dose dependent study

density lipoprotein (Shalita et al., 1983; Tallab et al., 2004; Bener et al., 2009; Owen, 2014; Rademaker, 2016, DeKlotz et al., 2017). In our study we did not observe modification in the liver enzymes and parameters which could indicate liver damage, as was also demonstrated in the gastrointestinal tract analysis (Thomazini and Dolder, 2017a,b). Previous authors observed the protein supplementation concomitant to isotretinoin treatment and showed that the liver transaminases alterations were due to the supplementation rather than the treatment (DeKlotz et al., 2017). The maintenance of protein parameters and lipid peroxidation indicates that the protocol for this study was not sufficient to cause biochemical liver injuries. It is important that this occurred with both dosages, so even a higher dosage was not enough to cause this kind of injury. On the other hand, increased alkaline phosphatase and a decrease of gamma-glutamyl transferase were observed for D1 in relation to C. The increase of alkaline phosphatase levels can indicate canalicular liver damage and liver inflammation, although not following a linear scale. We found a decrease in tissue level of gamma-glutamyl transferase in D1 in relation to the C group.

Previous authors (Vu-Dac et al., 1998; Rodondi et

al., 2002; Sedova et al., 2004; de Marchi et al., 2006; Vieira and Beijamini, 2012; Kızılyel et al., 2014) demonstrated that the increase in triglyceride levels in patients being treated with oral isotretinoin may be related to a reduction in the removal rate of these lipids from the plasma. According to these authors, it also appears to be influenced by the increase in gene expression for Apo E (Vu-Dac et al., 1998; Rodondi et al., 2002; Sedova et al., 2004; de Marchi et al., 2006; Vieira and Beijamini, 2012). The increase of triglyceride levels in the D10 group is in accordance with the literature that affirms this tendency (Tabanlıoğlu Onan et al., 2016). It is interesting to observe that the most commonly suggested dosage of 1mg/kg did not alter any lipid levels in male Wistar rats. Saied and Hamza (2014) treated rats with isotretinoin and selenium and observed that the exposure to isotretinoin increased serum levels of alanine aminotransferase, aspartate aminotransferase, alkaline phosphatase, cholesterol, triglycerides, and high-density lipid content. The authors also showed a significant rise in thiobarbituric acid reacting substance and nitric oxide content with concomitant decrease in reduced glutathione and the antioxidant enzyme activities of superoxide dismutase and catalase in liver

Table 2. Liver tissue and blood serum biochemical analysis in male Wistar rats after 60 days of treatment with 1mg/kg and 10mg/kg of isotretinoin.

Groups	C- control with water	D0- control with soybean oil	D1-1mg/Kg of isotretinoin	D10- 10mg/kg of isotretinoin
Liver tissue biochemistry				
AF (U/L)	73.27±12.96 ^{ab}	64.87±8.32 ^b	77.09±11.00 ^{ab}	101.26±16.33 ^b
ALT (U/mL)	63.52±7.65	62.88±21.70	85.05±25.37	50.33±28.99
AST (U/mL)	94.41±13.31 ^a	75.90±7.32 ^b	86.57±7.76 ^{ab}	87.81±3.32 ^{ab}
Brad (µgptn/µl)	0.24±0.04	0.27±0.03	0.26±0.04	0.28±0.03
CAT (U/mL)	31077±2999	29931±2129	29988±3068	28478±2384
GGT (U/L)	48.89±4.98	49.79±5.73	40.40±3.98	36.02±12.11
GLUT (nmoles/mL)	27.46±543.25	2813±1115	2928±986	3394±1044
MDH	27.14±8.09	23.10±1.01	19.38±4.22	21.03±2.78
SOD (U/mL)	0.14±0.03 ^a	0.09±0.03 ^{ab}	0.03±0.05 ^b	0.08±0.04 ^{ab}
Blood serum biochemistry				
AF (U/L)	146.80±59.22 ^a	157.20±63.31 ^a	293.60±84.57 ^b	162.60±64.35 ^{ab}
Alb (g/dL)	3.48±0.54 ^{ab}	3.86±0.87 ^a	3.48±0.31 ^{ab}	2.94±0.17 ^b
ALT (U/L)	37.40±8.44	48.00±13.30	52.40±10.78	41.20±9.86
AST (U/L)	176.60±66.55	169.80±19.46	225.20±63.21	211.80±73.66
COL (mg/dL)	68.60±11.91	67.60±16.14	68.40±13.45	55.80±8.04
DB (mg/dL)	0.03±0.03	0.03±0.02	0.04±0.03	0.02±0.03
GGT (U/L)	4.86±2.20 ^a	2.22±1.31 ^b	2.48±0.88 ^b	3.74±0.84 ^{ab}
GLOB (g/dL)	4.52±0.95	5.50±1.18	4.26±0.64	4.04±0.48
HDL (mg/dL)	25.00±5.15 ^{ab}	29.00±8.66 ^b	23.00±5.24 ^{ab}	18.80±3.42 ^a
IB (mg/dL)	0.06±0.04 ^a	0.04±0.04 ^a	0.04±0.02 ^a	0.04±0.01 ^a
LDL (mg/dL)	23.56±11.31 ^a	24.32±6.51 ^a	19.00±8.55 ^{ab}	10.10±5.99 ^b
MDH	16.05±9.61	17.71±9.09	15.80±2.12	13.38±4.93
TB (mg/dL)	0.09±0.07	0.07±0.04	0.07±0.05	0.06±0.03
TRIG (mg/dL)	100.20±50.99 ^{ab}	71.40±21.49 ^b	132.00±42.50 ^{ab}	145.00±60.67 ^a
TP (g/dL)	7.99±1.34 ^{ab}	9.36±2.03 ^a	7.74±0.79 ^{ab}	6.98±0.64 ^b
VLDL (mg/dL)	20.04±10.20 ^{ab}	14.28±4.30 ^a	26.40±8.50 ^{ab}	29.00±12.13 ^b

Mean ± standard deviation. Averages in the same row followed by different letters differ by the Kruskal-Wallis test followed by Dunn's post test at 5 % significance level. AF: Alkaline Phosphatase; Alb: albumin; ALT: Alanine Transaminase; AST: Aspartate Aminotransferase; Brad: Bradford protein assay; CAT: Catalase; Col: total cholesterol; DB: direct bilirubin; GGT: Gamma-Glutamyl Transferase; Glob: globulin; Glut: Total Glutathione; HDL: high density lipoprotein cholesterol; IB: indirect bilirubin; LDL: low density lipoprotein cholesterol; MDH: Malondialdehyde; SOD: Superoxide Dismutase; TB: total bilirubin; TP: total protein; Trig: total triglycerides; VLDL: very low density lipoprotein.

A dose dependent study

tissue after daily isotretinoin exposure at the dosage of 7.5 mg/kg for 28 days. Another study using vitamin A tablets as acne treatment in 50 patients showed elevated serum lipid levels in 4.2% of the patients and abnormal liver tests in 4.8% (Kotori, 2015).

The increase of triglyceride levels in D10 was expected, based on the literature but the decrease of low density lipoprotein and high density lipoprotein are not in accordance with what is known for the retinoid treatments. The very low density lipoprotein level was found to increase. We believe that this higher concentration is associated to the total triglyceride elevation considering that this protein is related with triglyceride transport in the blood. Previous authors (Bershad et al., 1985; Kaymak and Ilter, 2006; Rademaker, 2016) reported an increase in low density lipoprotein and triglycerides, but a decrease in high density lipoprotein during isotretinoin therapy. These changes in lipid profile also appeared to be transient and

returned to baseline level two months following the end of treatment. In another study (Vieira and Beijamini, 2012) with 130 patients who were treated with isotretinoin, the authors noted an increase in aspartate aminotransferase, alanine aminotransferase, and triglyceride levels. Most of the studies in the literature that reported effects of isotretinoin on liver enzymes and lipids suggested that the effects were reversible and the patterns followed those already presented in this discussion.

In a previous study with 150 participants, the authors found no statistically significant changes in liver transaminase and lipid levels following usual treatment with isotretinoin (Brito et al., 2010). In another study with 30 participants, the authors reported that triglycerides, low density lipoprotein or high density lipoprotein levels showed no difference with the treatment (Baxter et al., 2003). In another study with 1292 participants, the authors found no increase in

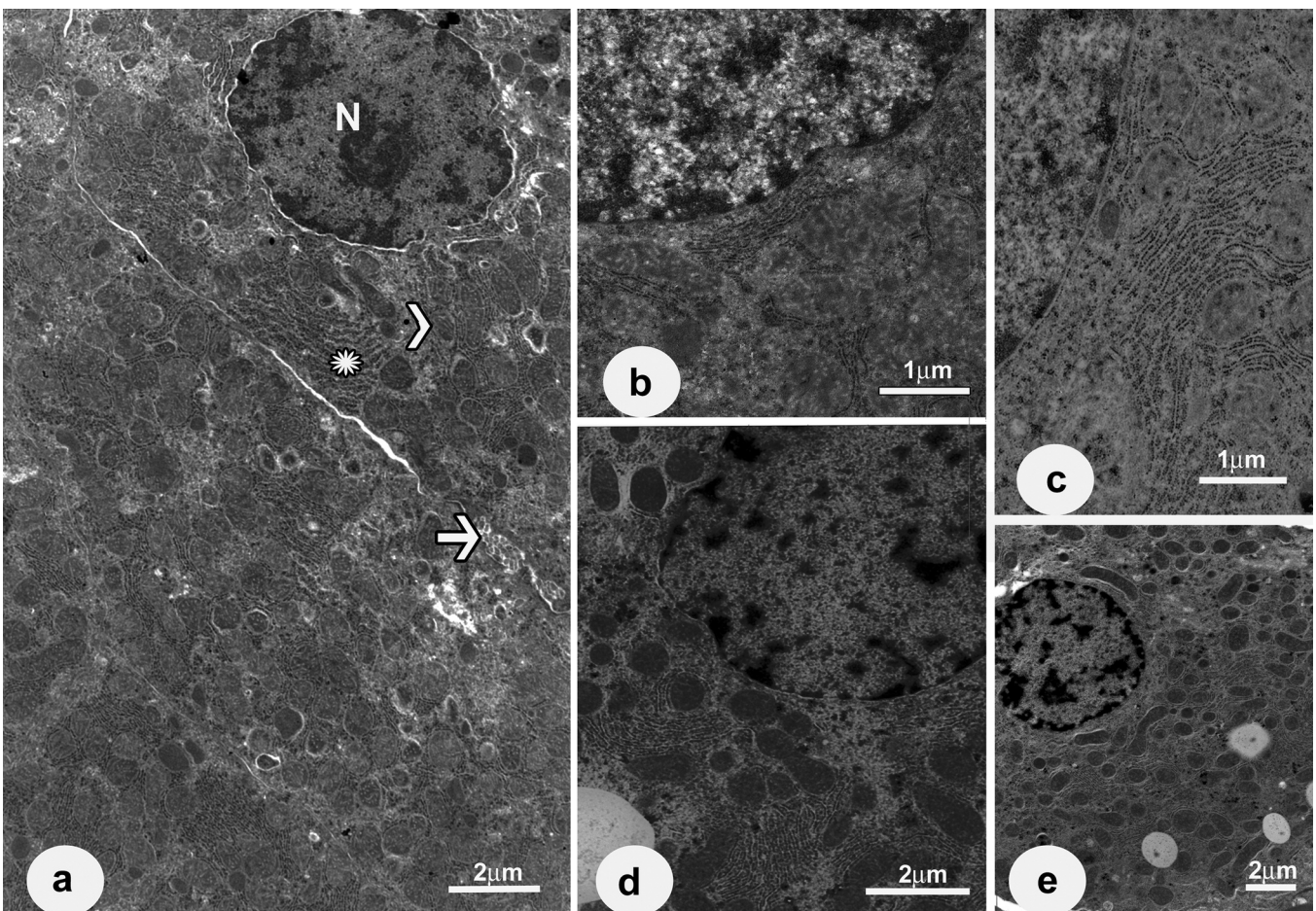


Fig. 2. Transmission Electron Microscopy. **a.** Group C (control group with water). **b.** Group D1(1mg/kg of isotretinoin). **c.** Group D0 (control group with soybean oil). **d-e.** Group D10 (10 mg/kg of isotretinoin). In the control group image, the arrow indicates the bile canalicular duct; the arrowhead indicates mitochondria; the asterisk (*) indicates an area with rough endoplasmic reticulum; N: nucleus. The dose dependent increase of mitochondria and rough endoplasmic reticulum frequency can be observed.

A dose dependent study

serum levels of liver enzymes occurred up to the end of the treatment (Alcalay et al., 2001). Another study found that liver enzymes were less affected than lipids in patients who underwent treatment with isotretinoin (Kızılyel et al., 2014). A study of seven patients with severe rosacea observed increases in serum triglycerides, cholesterol, triglycerides associated with very low density lipoprotein, low density lipoprotein, high density lipoprotein and aspartate aminotransferase. These authors also observed a decrease in bilirubin levels (Marsden et al., 1984). Previous work (Gencoglan et al., 2017) observed hematological parameters during isotretinoin therapy and verified increased platelet and decreased white blood cells in the first month of treatment. Besides these alterations, the authors noted a reestablishment of platelet and white blood cell levels in the second month. Thus, as in the above results, serum alteration due to isotretinoin treatment can occur initially but these soon return to baseline, in approximately 60 days. The lack of significant differences of the liver enzyme level and lipid parameters found for this study are in accordance with the literature that indicates variable effects with the isotretinoin treatment.

The histological analyses of liver sections showed no detectable alteration due to the treatment. Reticulin fibers were distributed as usual in the connective tissue, providing support for the organ. Masson's Trichrome showed no signs of fibrosis and no sign of mucin accumulation was established by the combination technique of Alcian Blue pH2.5 and PAS. Some previous studies indicated that retinoids suppressed fibrosis induced by CCL4 (Blomhoff, 1997; Okuno et al., 1997; Wang et al., 2007). The absence of fibrosis among the groups is in accordance with the literature (Blomhoff, 1997; Okuno et al., 1997; Wang et al., 2007) and the lack of histological differences in agreement with the other results registered (Thomazini and Dolder, 2017a,b).

Samples submitted to transmission electron microscopy showed evidence of higher liver activity, such as the increased number of mitochondria and of rough endoplasmic reticulum area. The connective tissue components showed no difference, in agreement with previous authors that showed that retinoids do not appear to produce consistent toxic liver abnormalities (Roeningk, 1988). Compiling serum and tissue biochemistry, which show no hepatotoxicity signs, we have demonstrated that isotretinoin in these two dosages did not cause lasting liver alterations in young male Wistar rats.

The lack of alterations, as assessed by morphometry, is in accordance with the biochemical and ultrastructural results. The proportion of binuclear and mononuclear hepatocytes, cytoplasm area, defense cells and vessels, are not different among the groups. Alterations in the proportion and area occupied by cytoplasmic organelles and normal frequency of binuclear or mononuclear hepatocytes depend on the kind of treatment (Weibel et al., 1969; Areshidze et al., 2013; Petrovova et al., 2013). This reinforces the finding that the treatment with

isotretinoin proposed in this protocol does not alter liver structure. In our study, we found no clear signs of alterations of the parameters showing that retinoids do not appear to produce consistent toxic liver abnormalities.

Conclusions

The treatment with 1 mg/kg and 10 mg/kg of isotretinoin did not alter significantly the liver tissue and blood serum biochemical parameters related to liver injuries, protein levels and stress oxidative levels. Liver structure did not show differences among the groups. We confirmed that this proposed treatment protocol does not produce consistent liver abnormalities in young male Wistar rats.

Acknowledgements. We are grateful to the Brazilian research agencies: CAPES, CNPq and Fapesp (Proc.2016/18201-0) for financial support for this research and Capes and CNPq for the scholarship.

Conflict of interest. The authors declare that there are no conflicts of interest.

References

- Ahmad H.M. (2015). Analysis of clinical efficacy, side effects, and laboratory changes among patients with acne vulgaris receiving single versus twice daily dose of oral isotretinoin. *Dermatol. Ther.* 28, 151-157.
- Alcalay J., Landau M. and Zucker A. (2001). Analysis of laboratory data in acne patients treated with isotretinoin: is there really a need to perform routine laboratory tests? *J. Dermatolog. Treat.* 12, 9-12.
- Allen J.G. and Bloxham D.P. (1989). The pharmacology and pharmacokinetics of the retinoids. *Pharmacol. Ther.* 40, 1-27.
- Alli N. and Yorulmaz A. (2015). An unusual side effect of isotretinoin: retinoid dermatitis affecting external urethral meatus. *Cutan. Ocul. Toxicol.* 34, 176-177
- Areshidze D.A., Timchenko L.D. and Kozlova M.A. (2013). Information condition of dog's liver at pathologies. *Glob. Veterinaria.* 11, 357-361.
- Baxter K.F., Ling T.C., Barth J.H. and Cunliffe W.J. (2003). Retrospective survey of serum lipids in patients receiving more than three courses of isotretinoin. *J. Dermatolog. Treat.* 14, 216-218.
- Bener A., Lestringant G.G., Ehlayel M.S., Saarinen K. and Takiddin A.H. (2009). Treatment outcome of acne vulgaris with oral isotretinoin. *J. Coll. Physicians Surg. Pak.* 19, 49-51.
- Bershad S., Rubinstein A., Paterniti J.R., Le N.A., Poliak S.C., Heller B., Ginsberg H.N., Fleischmajer R. and Brown W.V. (1985). Changes in plasma lipids and lipoproteins during Isotretinoin therapy for acne. *N. Engl. J. Med.* 313, 981-985.
- Blasiak R.C., Stamey C.R., Burkhardt C.N., Lugo-Somolinos A. and Morrell D.S. (2013). High-dose isotretinoin treatment and the rate of retreatment, relapse, and adverse effects in patients with acne vulgaris. *JAMA Dermatol.* 149, 1392-1398.
- Blomhoff R. (1997). Retinoids may increase fibrotic potential of TGF- β : crosstalk between two multi-functional effectors. *Hepatology* 26, 1067-1068.
- Brzezinski P., Borowska K., Chiriac A. and Smigielski J. (2017). Adverse

A dose dependent study

- effects of isotretinoin: A large, retrospective review. *Dermatol Ther.* 30, e12483.
- Brito M.F.M., Pessoa I.S., Galindo J.C.S., Rosendo L.H.P.M. and Santos J.B. (2010). Evaluation of clinical adverse effects and laboratory alterations in patients with acne vulgaris treated with oral isotretinoin. *An. Bras. Dermatol.* 85, 331-337.
- Charakida A., Mouser P.E. and Chu A.C. (2004). Safety and side effects of the acne drug, oral isotretinoin. *Expert Opin. Drug Saf.* 3, 119-125.
- Chiu Y-W. and Chen C-C. (2017). Cyclosporine-induced multiple sebaceous hyperplasia. *Dermatol. Sin.* 35, 52-53.
- DeKlotz C.M.C., Roby K.D. and Friedlander S.F. (2017). Dietary supplements, isotretinoin, and liver toxicity in adolescents: A retrospective case series. *Pediatrics* 140, e20152940.
- De Marchi M.A., Maranhao R.C., Brandizzi L.I. and Souza D.R. (2006). Effects of isotretinoin on the metabolism of triglyceride-rich lipoproteins and on the lipid profile in patients with acne. *Arch. Dermatol. Res.* 297, 403-408.
- Diniz D.G.A., Lima E.M. and Filho N.R.A. (2002). Isotretinoína: perfis farmacológicos, farmacocinético e analítico. *Rev. Farm. Bioquim. Univ. São Paulo.* 38, 415-430.
- Gencoglan G., Inanir I., Miskioglu M. and Gunduz K. (2017). Evaluation of sequential effect of isotretinoin on the haematological parameters in patients with acne vulgaris. *Cutan. Ocul. Toxicol.* 9, 1-4.
- Hardman J., Limbird L., Molinoff P., Ruddon R. and Gilman A. (1996). Goodman & Gilman's The Pharmacological Basis of Therapeutics. 9th ed. McGraw-Hill. New York.
- Jacobs D.G., Deutsch N.L. and Brewer M. (2001). Suicide, depression, and isotretinoin: Is there a causal link? *J. Am. Acad. Dermatol.* 45, S168-175.
- Karadag A.S.; Parish L.C. and Lambert W.C. (2017). Isotretinoin in retrospecto. *Clin. Dermatol.* 35, 335-339.
- Kaymak Y. and Ilter N. (2006). The results and side effects of systemic isotretinoin treatment in 100 patients with acne vulgaris. *Dermatol. Nurs.* 18, 576-580.
- Kızılyel O., Metin M.S., Elmas O.F., Çayır Y. and Aktas A. (2014). Effects of oral isotretinoin on lipids and liver enzymes in acne patients. *Cutis* 94, 234-238.
- Kotori M.G. (2015). Low-dose vitamin "A" tablets-treatment of acne vulgaris. *Med. Arch.* 69, 28-30.
- Lee S.A., Yuen J.J., Jiang H., Kahn B.B. and Blaner W.S. (2016). Adipocyte-specific overexpression of retinol-binding protein 4 causes hepatic steatosis in mice. *Hepatology* 64, 1534-1546.
- Lowenstein E.B. and Lowenstein E.J. (2011). Isotretinoin systemic therapy and the shadow cast upon dermatology's downtrodden hero. *Clin. Dermatol.* 29, 652-661.
- Madeira N., Santos T., Santos Z. and Marques A.R. (2012). Isotretinoin, depression and suicide. *Rev. Psiq. Clin.* 39, 76-77.
- Marsden J.R., Trinick T.R., Laker M.F. and Shuster S. (1984). Effects of isotretinoin on serum lipids and lipoproteins, liver and thyroid function. *Clin. Chim. Acta* 143, 243-251.
- Nankervis R., Davis S.S., Day N.H. and Shaw P.N. (1995). Effect of lipid vehicle on intestinal lymphatic transport of isotretinoin in the rat. *Int. J. Pharm.* 119, 173-181.
- Okuno M., Moriwaki H., Imai S., Muto Y., Kawada N., Suzuki Y. and Kojima S. (1997). Retinoids exacerbate rat liver fibrosis by inducing the activation of latent TGF- β in liver stellate cells. *Hepatology* 26, 913-921.
- Owen C.E. (2014). Treating acne with high-dose isotretinoin. *JAMA Dermatol.* 311, 2121.
- Petrovova E., Purzyc H., Mazensky D., Luptakova L., Torma N., Sopoliga I. and Sedmera D. (2013). Morphometric alterations, steatosis, fibrosis and active caspase-3 detection in carbamate bendiocarb treated rabbit liver. *Environ. Toxicol.* 30, 212-222.
- Rademaker M. (2016). Isotretinoin: dose, duration and relapse. What does 30 years of usage tell us? *Australas. J. Dermatol.* 54, 157-162.
- Rademaker M. (2018). Very low-dose isotretinoin in mild to moderate papulopustular rosacea; a retrospective review of 52 patients. *Australas J. Dermatol.* 59, 26-30.
- Rigopoulos D., Larios G. and Katsambas A.D. (2010). The role of isotretinoin in acne therapy: why not as first-line therapy? Facts and controversies. *Clin. Dermatol.* 28, 24-30.
- Rodondi N., Darioli R., Ramelet A.A., Hohl D., Lenain V., Perdrix J., Wietlisbach V., Riesen W.F., Walther T., Medinger L., Nicod P., Desvergne B. and Mooser V. (2002). High risk for hyperlipidemia and the metabolic syndrome after an episode of hypertriglyceridemia during 13-cis-retinoic acid therapy for acne: A pharmacogenetic study. *Ann. Intern. Med.* 136, 582-589.
- Roenigk H.H. Jr (1988). Liver toxicity of retinoid therapy. *J. Am. Acad. Dermatol.* 19, 199-208.
- Shalita A.R., Cunningham W.J., Leyden J.J., Pochi P.E. and Strauss J.S. (1983). Isotretinoin treatment of acne and related disorders: An update. *J. Am. Acad. Dermatol.* 9, 629-638.
- Saied N.M. and Hamza A.A. (2014). Selenium ameliorates isotretinoin-induced liver injury and dyslipidemia via antioxidant effect in rats. *Toxicol. Mech. Methods.* 24, 433-437.
- Sampaio S.A.P. (2008). Experiência de 65 anos no tratamento da acne e de 26 anos com isotretinoína oral. *An. Bras. Dermatol.* 83, 361-367.
- Saurat J.H. (1997). Oral isotretinoin. Where now, where next? *Dermatol.* 195, 1-3.
- Sedova L., Seda O., Krenova D., Kren V. and Kazdova L. (2004). Isotretinoin and fenofibrate induce adiposity with distinct effect on metabolic profile in a rat model of the insulin resistance syndrome. *Int. J. Obes.* 28, 719-725.
- Tallab T., Joharji H., Jazei M., Bahamdan K., Ibrahim K. and Karkashan E. (2004). Isotretinoin therapy: any need for laboratory assessment? *West Afr. J. Med.* 23, 273-275.
- Tabanlıoğlu Onan D., Hazar Tantoğlu B., Alli N., Özkan S., Samsar U., Köseoğlu H.T. and Artüz R.F. (2016). Evaluation of the gastrointestinal findings of nodulocystic acne patients during systemic isotretinoin therapy. *Turk. J. Med. Sci.* 46, 820-824.
- Thomazini B.F. and Dolder M.A. (2017a). Effect of 60 and 90 days of isotretinoin treatment on the structure of the small intestine mucosa in young male Wistar rats. *Interdiscip. Toxicol.* 10, 45-51.
- Thomazini B.F. and Dolder M.A. (2017b). Dose dependent treatment with isotretinoin induces more changes in the ileum than in the duodenum and jejunum in Wistar rats. *Tiss. Cell.* 49, 203-208.
- Vieira A.S. and Bejamini V. (2012). Melchioris AC. The effect of isotretinoin on triglycerides and liver aminotransferases. *An. Bras. Dermatol.* 87, 382-387.
- Vu-Dac N., Gervois P., Torra I.P., Fruchart J.C., Kosykh V., Kooistra T., Princen H.M.G., Dallongeville J. and Staels B. (1998). Retinoids increase human apo C-III expression at the transcriptional level via the retinoid X receptor: contribution to the hypertriglyceridemic action of retinoids. *J. Clin. Invest.* 102, 625-632.
- Wang L., Potter J.J., Rennie-Tankersley L., Novitskiy G., Sipes J. and

A dose dependent study

- Mezey E. (2007). Effects of retinoic acid on the development of liver fibrosis produced by carbon tetrachloride in mice. *BBA-Mol. Basis Dis.* 1772, 66-71.
- Weibel E.R., Stäubli W., Gnägi H.R. and Hess F.A. (1969). Correlated morphometric and biochemical studies on liver cell: I. Morphometric model stereologic methods and normal morphometric data for rat liver. *J. Cell Biol.* 42, 68-91.
- White G.M. (1999) Acne therapy. *Dis. Mon.* 45, 301-332.
- Yap F.B. (2017). Safety and efficacy of fixed-dose 10 mg daily isotretinoin treatment for acne vulgaris in Malaysia. *J. Cosmet. Dermatol.* 16, 348-352.
- Zouboulis C.C., Korge B., Akamatsu H., Xia L.Q., Schiller S., Gollnick H. and Orfanos C.E. (1991). Effects of 13-cis-retinoic acid, all-trans-retinoic acid, and acitretin on the proliferation, lipid synthesis and keratin expression of cultured human sebocytes in vitro. *J. Invest. Dermatol.* 96, 792-797.

Accepted December 17, 2018