

Review

Pathology and terminology of interstitial cystitis/bladder pain syndrome: A review

Yoshiyuki Akiyama¹, Yukio Homma^{1,2} and Daichi Maeda^{3,4}

¹Department of Urology, Graduate School of Medicine, The University of Tokyo, ²Japanese Red Cross Medical Center, Tokyo, ³Department of Cellular and Organ Pathology, Graduate School of Medicine, Akita University, Akita and ⁴Department of Clinical Genomics, Graduate School of Medicine, Osaka University, Osaka, Japan

Summary. Interstitial cystitis/bladder pain syndrome (IC/BPS) is an umbrella term of chronic debilitating conditions of unknown etiology characterized by symptoms of lower urinary tract hypersensitivity such as bladder pain/discomfort, urgency, and urinary frequency. The pathological features of IC/BPS have been generally reported as non-specific chronic inflammatory changes, with mast cell infiltration as a potential key finding. However, growing evidence reveals a histological distinction between IC/BPS with Hunner lesions and IC/BPS without Hunner lesions, and also sheds doubt on the diagnostic value of the mast cell count. Specifically, IC/BPS with Hunner lesions is an inflammatory disorder characterized by pancystitis with B cell abnormalities and epithelial denudation, while IC/BPS without Hunner lesions shows minimal histological changes. The umbrella term “IC/BPS” connects totally distinct clinical entities. Pathological evaluation thus plays an important role in the precise subtyping and clinical management of IC/BPS. In addition, terminology should be developed to refer separately to IC/BPS with Hunner lesions and IC/BPS without Hunner lesions.

Key words: Interstitial cystitis, Bladder pain syndrome, Terminology, B cell, Plasma cell, Mast cell

Introduction

Interstitial cystitis/bladder pain syndrome (IC/BPS) is an umbrella term connecting IC and BPS. IC is a bladder disorder of unknown etiology characterized by lower urinary tract hypersensitivity, including bladder pain/discomfort, urinary urgency, and increased urinary frequency (Gillenwater and Wein, 1988; van de Merwe et al., 2008; Hanno et al., 2015; Homma et al., 2016). IC may be associated with Hunner lesions, which are reddish mucosal lesions lacking the normal capillary structure on cystoscopy (Fig. 1). BPS is a clinical symptom syndrome of unknown etiology with similar lower urinary tract symptoms to IC (Hanno and Dmochowski, 2009). Both IC and BPS are seen in adult women and men, and no abnormalities are detected upon routine clinical tests. IC and BPS are thus phenotypically indistinguishable and are often connected and described using an umbrella term, IC/BPS. The role of histopathological evaluation in IC/BPS has not been generally established. The pathological features of IC/BPS are highly variable; that is, some cases show virtually no abnormal findings, while others display severe inflammatory changes (Utz and Zincke, 1974; Messing and Stamey, 1978; Fall et al., 1987; Johansson and Fall, 1990; Lynes et al., 1990; Erickson et al., 1997; Denson et al., 2000; Leiby et al., 2007; Logadottir et al.,

Offprint requests to: Daichi Maeda, M.D., Ph.D., Department of Clinical Genomics, Graduate School of Medicine, Osaka University, Osaka, Japan, e-mail: maeda-ky@umin.ac.jp or Yoshiyuki Akiyama, M.D., Ph.D., Department of Urology, Graduate School of Medicine, The University of Tokyo, Tokyo, Japan. e-mail: yakiyamauro-ky@umin.ac.jp
DOI: 10.14670/HH-18-028

Abbreviations. ESSIC, International Society for the Study of BPS; HIC, Hunner type interstitial cystitis; HSB, hypersensitive bladder; IC/BPS, interstitial cystitis/bladder pain syndrome; MBAD, mucosal bleeding after distension; NHIC, non-Hunner type interstitial cystitis

2014a,b; Gamper et al., 2015; Maeda et al., 2015; Kim et al., 2017). In addition, the specificity of mast cell infiltration has been deeply debated.

However, recent research has clearly elucidated the histological distinction between IC/BPS with Hunner lesions and IC/BPS without Hunner lesions. IC/BPS with Hunner lesions is an inflammatory disorder characterized by pancystitis with B cell abnormalities and epithelial denudation, while IC/BPS without Hunner lesions shows minimal histological changes (Maeda et al., 2015). Growing evidence suggests that the mast cell count in bladder biopsy samples is of limited value in differentiating IC/BPS from other etiologies (Dundore et al., 1996; Gamper et al., 2015; Akiyama et al., 2017).

Herein, we review recent pathological findings in IC/BPS and underscore the significance of histopathological examination in IC/BPS. We also propose the disuse of the term “IC/BPS,” as it creates confusion by connecting distinct clinical entities.

Current definition, diagnosis and classification

Currently, there is no internationally standardized definition or set of diagnostic criteria for IC, BPS, or related conditions. However, available clinical guidelines commonly require lower urinary tract symptoms such as bladder pain, urinary urgency, and increased frequency of urination for a diagnosis of IC/BPS, after excluding confusable disorders (van de Merwe et al., 2008; Hanno et al., 2015; Cox et al., 2016).

The International Society for the Study of BPS (ESSIC) defines BPS as chronic (lasting >6 months) pelvic pain, pressure, or discomfort perceived to be related to the urinary bladder and accompanied by at least one other urinary symptom such as a persistent urge to void or increased frequency of urination (van de Merwe et al., 2008). The American Urological Association (AUA) defines IC/BPS as an unpleasant sensation (pain, pressure, or discomfort) perceived to be related to the urinary bladder and associated with lower urinary tract symptoms lasting >6 weeks in the absence of infection or other identifiable cause (Hanno and Dmochowski, 2009). The East Asian guidelines avoid using the term BPS, and define IC as bladder hypersensitive symptoms with cystoscopic abnormalities, and hypersensitive bladder (HSB) as the symptoms alone, in the absence of cystoscopic abnormalities (Homma et al., 2016). However, no guidelines require histopathological findings for definition or diagnosis.

Regarding classification, the ESSIC and the East Asian guidelines further classify IC/BPS based on cystoscopic and/or histological findings from bladder biopsies (Table 1) (van de Merwe et al., 2008; Homma et al., 2016). IC/BPS with Hunner lesions (also termed “classic” or “ulcerative” IC) corresponds to BPS type 3 in the ESSIC guidelines and Hunner type IC (HIC) in the East Asian guidelines, respectively. The ESSIC guidelines designate IC/BPS without Hunner lesions but with glomerulations as BPS type 2 and IC/BPS with neither Hunner lesions nor glomerulations as BPS type 1. The East Asian guidelines classify patients without

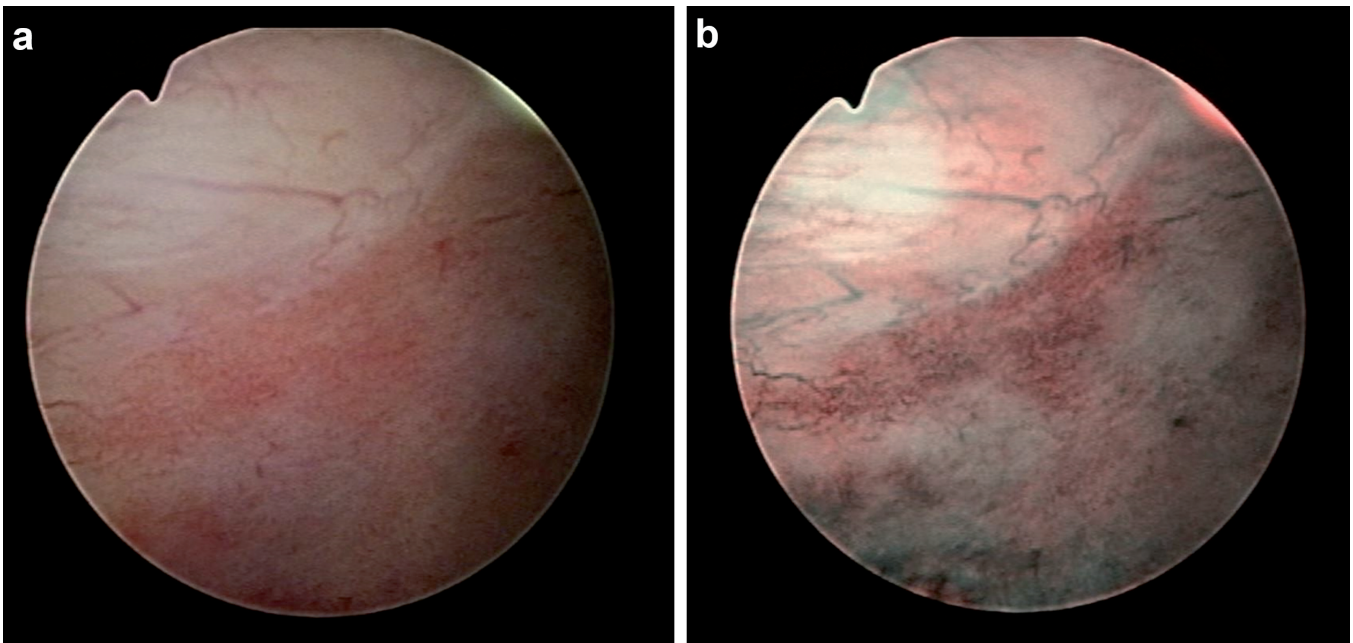


Fig. 1. A Hunner lesion. **a.** Hunner lesions are reddish mucosal lesions lacking the normal capillary structure, frequently covered by fibrin clots. **b.** Narrow-band imaging cystoscopy of the Hunner lesion emphasizes the abnormal capillary structure.

Pathology and terminology of interstitial cystitis

Hunner lesions but with mucosal bleeding after distension (MBAD) as having non-Hunner type IC (NHIC), and patients with neither Hunner lesions nor MBAD as having HSB. Glomerulations and MBAD refer to virtually the same cystoscopic findings: spotty bleeding after bladder overdistension.

The ESSIC guidelines further classify BPS into three groups according to histological findings such as inflammatory infiltrate, granulation tissue, detrusor mastocytosis, and intrafascicular fibrosis. For example, BPS type 3C indicates the presence of Hunner lesions by cystoscopy and histological evidence of inflammation in the biopsy specimen. The East Asian guidelines make no further classifications based on bladder histopathology. The AUA and Canadian Urological Association provide no classification system for IC/BPS (Hanno et al., 2015; Cox et al., 2016).

Pathological findings in IC/BPS

Earlier studies on the histological manifestations of IC/BPS concluded that IC/BPS is a non-specific manifestation, while recent studies demonstrated

histopathological differences among IC/BPS subtypes (Table 2). Earlier studies failed to detect the significance of histological findings because IC/BPS cases with and without Hunner lesions were evaluated as a single cohort. Once evaluated separately, the different pathological features of IC/BPS subtypes became apparent (Fall et al., 1987; Johansson and Fall, 1990; Logadottir et al., 2014a,b; Gamper et al., 2015; Kim et al., 2017). IC/BPS with Hunner lesions is characterized by pancystitis accompanied by epithelial denudation, whereas IC/BPS without Hunner lesions exhibits minimal inflammatory changes and urothelial preservation (Maeda et al., 2015).

HIC or IC/BPS with hunner lesions

If Hunner lesions are present, the bladder tissue almost always shows subepithelial infiltration by inflammatory cells, predominantly lymphocytes and plasma cells. The subepithelial inflammation is often dense, with lymph follicles frequently observed in biopsied specimens (Fig. 2a). The plasma cell/lymphocyte ratio is significantly higher in HIC than in chronic cystitis without IC/BPS (Maeda et al., 2015). Plasma cells may comprise a substantial proportion of the inflammatory infiltrate in some areas of the biopsy specimen (Fig. 2b). In most cases, scattered eosinophils are found, while neutrophils are scarce. Dense neutrophilic infiltration, which is indicative of acute inflammation or infection, is rarely observed. Stromal edema and fibrosis may be found in the lamina propria, as documented previously (Fall et al., 1987). Edema and fibrosis may be present, most likely as a result of chronic inflammatory processes, but are difficult to objectively quantify.

Another distinct histological feature of importance in HIC is epithelial denudation, where the epithelium is denuded in a sloughing manner (Fig. 2c). Intra-epithelial

Table 1. Relationship between the terminology of the ESSIC and the East Asian guidelines.

Guidelines	BPS type 1	BPS type 2	BPS type 3
ESSIC	Hypersensitive bladder	Non-Hunner type IC	Hunner type IC
East Asian			
Endoscopic findings			
Hunner lesions	Negative	Negative	Positive
Glomerulations/ after distension mucosal bleeding	Negative	Positive	Not required

ESSIC: European Society for the Study of IC/BPS, IC: interstitial cystitis, BPS: bladder pain syndrome.

Table 2. Past publications on the histological manifestations of interstitial cystitis/bladder pain syndrome.

	Distinction of IC/BPS subtypes	Histological changes†	
		Differences between the subtypes	Histological findings specific to IC/BPS
Messing et al., 1978	+	ND	Non-specific
Fall M et al., 1987	+	HIC>NHIC	Increased mast cell density in HIC
Lynes et al., 1990	ND	ND	Non-specific
Johansson et al., 1990	+	HIC>NHIC	Non-specific
Erickson et al., 1997	ND	ND‡	Non-specific
Denson et al., 2000	ND*	ND	Non-specific
Leiby et al., 2007	ND	ND¶	Non-specific
Logadottir et al., 2014a,b	+	HIC>NHIC	Increased nitric oxide production in HIC
Gamper et al., 2015	+	HIC>NHIC	Non-specific
Maeda et al., 2015	+	HIC>NHIC	Pancystitis and clonal B cell expansion in HIC
Kim et al., 2017	+	HIC>NHIC	Severe fibrosis and increased mast cell density in NHIC

IC/BPS: interstitial cystitis/bladder pain syndrome, HIC: Hunner type interstitial cystitis (IC/BPS with Hunner lesions), NHIC: non-Hunner type interstitial cystitis (IC/BPS without Hunner lesions), ND: not detected. † Epithelial denudation, inflammatory infiltrates, submucosal edema and hemorrhage, vasodilation, vascularization, and fibrosis. ‡ Two distinct histological groups by the degree of inflammation. * NHIC except one HIC. ¶ Three distinct histological subgroups by the degree of epithelial denudation and inflammatory infiltrates.

lymphocytes are frequently seen. Our quantitative analysis confirmed significantly denuded epithelium in HIC as compared with chronic cystitis without IC/BPS, implying that chronic inflammation alone does not cause the epithelial denudation (Maeda et al., 2015). These observations suggest that epithelial denudation is a characteristic and distinct feature of HIC.

Interestingly, inflammation and denudation are not confined to the Hunner lesions alone. Random biopsies from the background mucosa (outside the Hunner lesion area) also show subepithelial inflammation and epithelial denudation (Maeda et al., 2015). These findings indicate that HIC is essentially pancystitis, and that a Hunner lesion on cystoscopy may represent the area of the bladder mucosa with the most severe epithelial denudation and inflammation. The obsolete

nomenclature “Hunner ulcer” should also be disused, since pathologically the term “ulcer” refers to severely inflamed mucosa with dense infiltration of neutrophils, which is rarely seen in HIC, a complete loss of epithelium, and exudative changes. Characterization of infiltrating B cells demonstrated clonal expansion. In more than 30% of HIC cases, the infiltrating B cells were light chain-restricted (Fig. 2d-f), which is direct evidence of clonal B cell expansion (Maeda et al., 2015). These and subsequent reports suggest that specific immune responses or aberrant B cell proliferation may underlie the pathophysiology of HIC (Maeda et al., 2015; Akiyama et al., 2016). Revealing the biological significance of this B cell abnormality will likely increase our understanding of HIC pathogenesis.

The clinical implications of Hunner lesions are not

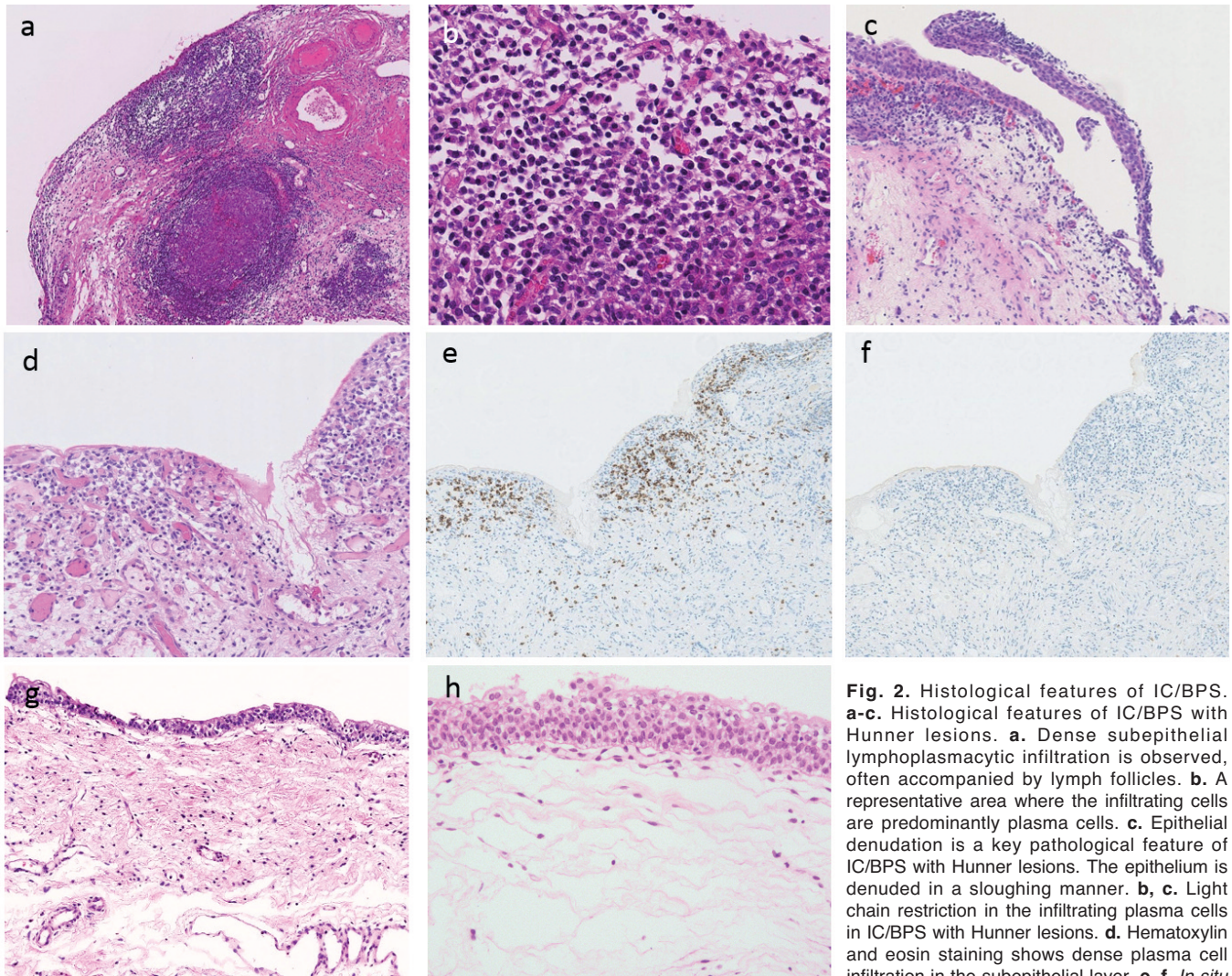


Fig. 2. Histological features of IC/BPS. **a-c.** Histological features of IC/BPS with Hunner lesions. **a.** Dense subepithelial lymphoplasmacytic infiltration is observed, often accompanied by lymph follicles. **b.** A representative area where the infiltrating cells are predominantly plasma cells. **c.** Epithelial denudation is a key pathological feature of IC/BPS with Hunner lesions. The epithelium is denuded in a sloughing manner. **b, c.** Light chain restriction in the infiltrating plasma cells in IC/BPS with Hunner lesions. **d.** Hematoxylin and eosin staining shows dense plasma cell infiltration in the subepithelial layer. **e, f.** *In situ*

hybridization for the kappa chain (**e**) or lambda chain (**f**). Most plasma cells express the kappa chain. **g.** Histological features of IC/BPS without Hunner lesions. The epithelium is well-preserved, and the density of subepithelial fiber is variable. Subepithelial hemorrhage, edema and vascular congestion are occasionally seen. In most cases, no significant inflammatory changes are observed.

Pathology and terminology of interstitial cystitis

well defined. Recently, we reported a significant relationship between the extent of Hunner lesions and symptom severity and bladder capacity on hydrodistension (Akiyama et al., 2018). By contrast, the degree of subepithelial inflammation did not correlate with symptom severity (Maeda et al., 2015). Urothelial denudation rather than the severity of inflammation may explain symptoms such as bladder pain. This hypothesis is supported by clinical evidence that Hunner lesion-targeted treatments (fulguration and/or direct injection of triamcinolone) effectively relieve these symptoms (Cox et al., 2009; Hillelsohn et al., 2012; Chennamsetty et al., 2015; Niimi et al., 2016).

IC/BPS without Hunner lesions

In contrast to IC/BPS cases with Hunner lesions, IC/BPS cases without Hunner lesions show little or no

histological inflammation (Fig. 2g) (Fall et al., 1987; Logadottir et al., 2014a,b; Maeda et al., 2015; Kim et al., 2017). Some previous studies reported subepithelial hemorrhage, edema, and vascular congestion as histological features of IC/BPS without Hunner lesions (Fig. 2h) (Johansson and Fall, 1994; Kim, 2016). However, these changes could be artifacts of the bladder distension prior to biopsy. A recent report identified fibrosis of the lamina propria as a potential characteristic feature of IC/BPS without Hunner lesions, as compared with IC/BPS with Hunner lesions (Kim et al., 2017). Other studies indicated the urothelial abnormalities, such as increased apoptotic activity and barrier dysfunction in the bladder of IC/BPS without Hunner lesions (Shie and Kuo, 2011; Liu et al., 2012). Urothelial functional deficiency, rather than visible morphological changes, may be causative factors for the hypersensitive symptoms in patients with IC/BPS

Table 3. Previous studies on mast cell enumeration in interstitial cystitis and bladder pain syndrome in humans.

	Inflammation	Mast cell			
		Staining/Counting	Counted area*	Density	
				Lamina propria	Detrusor
Larsen et al., 1982	NA	Naphthol esterase/Manual	Not described	IC†≈non-IC controls‡	IC>non-IC controls
Kastrup et al., 1983	NA	Naphthol esterase/Manual	Not described	NA	HIC>non-IC cystitis
Aldenburg et al., 1986	NA	Toluidine Blue/Manual	1 mm ²	HIC≈normal bladder**	HIC>normal bladder
Lynes et al., 1987	IC†>normal bladder	Alcian Blue/Manual	2 mm ²	IC≈normal bladder	IC>normal bladder
Feltis et al., 1987	NA	Alcian Blue/Manual	1 mm ²	NHIC>non-IC cystitis NHIC>normal bladder	NHIC>non-IC cystitis NHIC>normal bladder
Johansson and Fall, 1990	NA	Toluidine Blue/Manual	Not described	HIC>NHIC≈normal bladder	HIC>NHIC≈normal bladder
Christmas and Rode, 1991	NA	Toluidine Blue/Digital	5 mm ²	NHIC≈bacterial cystitis >normal bladder	NHIC>bacterial cystitis≈normal bladder
Theoharides et al., 1995	NA	Giemsa, Toluidine Blue, Alcian Blue/Manual	Not described	1. Non-IC controls¶>NHIC (Giemsa staining) 2. Bladder carcinoma≈NHIC >non-IC controls (Toluidine Blue and Alcian Blue)	NA
Dundore et al., 1996	NA	Giemsa/Manual	3 mm ²	NHIC≈non-IC cystitis ≈bladder cancer≈normal bladder	NHIC≈non-IC cystitis ≈bladder cancer≈normal bladder
Peeker et al., 2000	NA	MCT-IHC/Manual	1-2 mm ²	HIC>NHIC≈normal bladder	HIC>NHIC≈normal bladder
Yamada et al., 2000	NA	MCT-IHC/Manual	1 mm ²	NHIC>bladder cancer	NHIC>bladder cancer
Liu et al., 2012	NA	MCT-IHC/Manual	1 mm ²	NHIC≈OAB >normal bladder	NA
Logadottir et al., 2014a,b	NA	MCT-IHC/Manual	1-4 mm ²	NA	HIC>normal bladder
Gamper et al., 2015	HIC>NHIC ≈controls	MCT-IHC/Manual	1 mm ²	HIC≈OAB ≈NHIC≈normal bladder	HIC≈NHIC ≈OAB≈normal bladder (HIC>normal bladder)
Kim et al., 2017	HIC>NHIC >normal bladder	Toluidine Blue/Manual	0.2 mm ²	NHIC>HIC>normal bladder	NA
Akiyama et al., 2017	HIC≈non-IC cystitis >NHIC ≈normal bladder	MCT-IHC/Digital	Entire area	HIC≈non-IC cystitis >NHIC≈normal bladder	HIC≈non-IC cystitis ≈NHIC≈normal bladder

IC: interstitial cystitis, HIC: Hunner type interstitial cystitis, NHIC: non-Hunner type interstitial cystitis, OAB: overactive bladder, MCT: mast cell tryptase, IHC: immunohistochemistry, NA: not available. * The area of one high-powered field (×400) under a light microscope was calculated as 0.2 mm². ** "Normal bladder" refers to a non-inflamed bladder specimen with minimal histological changes. † The distinction between HIC and NHIC was unclear. ‡ Benign prostatic hypertrophy, bacterial cystitis, bladder cancer, and neurogenic bladder. ¶ Chronic urinary tract infection, hypersensitive bladder, urethral stenosis, normal bladder, radiation cystitis, hematuria, and renal transplantation. ≈ No significant difference was observed between the two variables. > A significant difference was observed between the two variables.

without Hunner lesions. These findings may provide an insight into the pathogenesis of IC/BPS without Hunner lesions. The lack of significant inflammatory changes also suggests that some patients of the IC/BPS without Hunner lesions may be affected with a systemic functional somatic syndrome rather than a bladder disease (Warren, 2014).

Mast cell infiltration in IC/BPS

Mast cell infiltration in IC/BPS has been extensively studied (Table 3), but its significance remains uncertain. While significant mast cell infiltration in IC/BPS has repeatedly been documented, many authors consider mastocytosis in IC/BPS to be a non-specific histological finding (Larsen et al., 1982; Kastrup et al., 1983; Aldenborg et al., 1986; Feltis et al., 1987; Lynes et al., 1987; Johansson and Fall, 1990; Christmas and Rode, 1991; Theoharides et al., 1995; Dundore et al., 1996; Peeker et al., 2000; Yamada et al., 2000; Liu et al., 2012; Logadottir et al., 2014a,b; Gamper et al., 2015; Kim et al., 2017; Akiyama et al., 2017). These inconsistent results are partially due to the use of obsolete immunohistochemical stains such as Giemsa, Alcian blue-periodic acid Schiff (PAS), or toluidine blue (Aldenborg et al., 1986; Yamada et al., 2000) and the limited area under evaluation (a 1-2 mm² area defined by measuring grids, or 5-10 high-powered fields in areas with the highest mast cell density) (Nordling et al., 2004). Other potentially confounding factors include subjective protocols for mast cell counting, the practice of combining IC/BPS with and without Hunner lesions into a single cohort (Larsen et al., 1982; Lynes et al., 1987), and ignorance of underlying inflammation that could influence mast cell infiltration (Larsen et al., 1982; Kastrup et al., 1983; Aldenborg et al., 1986; Feltis et al., 1987; Christmas and Rode, 1991; Theoharides et al., 1995; Peeker et al., 2000; Yamada et al., 2000; Liu et al., 2012; Logadottir et al., 2014a,b).

The ESSIC guidelines propose a detrusor mast cell count of ≥ 28 cells/mm² as a supportive histological finding to diagnose IC/BPS (Nordling et al., 2004). However, this criterion threshold is apparently derived from an older study and has not been fully discussed or validated (Larsen et al., 1982). Recently, we digitally quantified the mast cell densities in bladder biopsy specimens from patients with bladder inflammation with or without IC, in the lamina propria and in the detrusor muscle (Akiyama et al., 2017). The mast cell count was of limited value in differentiating IC from non-IC bladder specimens, which is in agreement with recent reports questioning the significance of mast cell infiltration in IC/BPS (Dundore et al., 1996; Gamper et al., 2015). It was noteworthy that non-IC cases exhibited detrusor mastocytosis of 40.9 cells/mm² on average, by far exceeding the ESSIC-defined criterion threshold for IC/BPS (28 cells/mm²).

Our observation does not deny the functional role of mast cells in the pathophysiology of IC/BPS; increased

fibrotic changes and neurogenic inflammation may be related to infiltrating mast cells (Pang et al., 1995; Kim et al., 2017). Detrusor mastocytosis and intrafascicular fibrosis in the deep detrusor layer are clearly observed in total cystectomy specimens from patients with end-stage IC/BPS with Hunner lesions. Persistent, severe inflammation, including mast cell infiltration, may be responsible for the extensive histological changes seen deep in the detrusor layer in advanced cases of IC/BPS with Hunner lesions. Detrusor mastocytosis and intrafascicular fibrosis in biopsy samples, with a small amount of the detrusor superficial layers, however, are of no significant value for the diagnosis of IC/BPS. Further analysis of mast cells is required to elucidate the potential pathophysiological consequences of mast cell infiltration in IC/BPS.

Revisiting the definition and terminology of IC/BPS

These recent pathological findings necessitate revision of the terminology of IC/BPS. IC/BPS with Hunner lesions is a distinct inflammatory disorder with epithelial denudation, whereas IC/BPS without Hunner lesions shows few histological manifestations. Detection of Hunner lesions has clinical implications; IC/BPS with Hunner lesions is responsive to Hunner lesion-targeted therapies such as fulgurations. Therefore, the umbrella term “IC/BPS” connects totally distinct clinical entities. The terminology should be developed to refer separately to IC/BPS with Hunner lesions and IC/BPS without Hunner lesions.

Conclusions

IC/BPS with Hunner lesions is a distinct inflammatory disorder characterized by pancystitis with frequent clonal expansion of infiltrating B cells and epithelial denudation, whereas IC/BPS without Hunner lesions is a non-inflammatory disorder with few histological manifestations. The umbrella term “IC/BPS” connects totally distinct clinical entities. Pathological evaluation thus plays an important role in the precise subtyping and clinical management of IC/BPS. In addition, terminology should be developed to refer separately to IC/BPS with Hunner lesions and IC/BPS without Hunner lesions.

Acknowledgements. The authors are financially supported by the Practical Research Project for Rare/Intractable Diseases of the Japan Agency for Medical Research and Development (AMED) (to YA), the Japan Intractable Diseases Research Foundation (to YA), the Asahi Kasei Pharma Urological Academy (to YA), and the Mitsui Life Social Welfare Foundation (to DM), and by KAKENHI Grants-in-Aid from the Japanese Society for the Promotion of Science (JSPS) [grant numbers 17H06639 (to YA), JP25293334 (to YH), and JP26870129 (to DM)].

Competing financial interests. The research of an author (DM) is supported partly by Takara Bio, Inc. Other authors declare that they have no relevant financial interests to disclose.

References

- Akiyama Y., Morikawa T., Maeda D., Shintani Y., Niimi A., Nomiya A., Nakayama A., Igawa Y., Fukayama M. and Homma Y. (2016). Increased CXCR3 expression of infiltrating plasma cells in hunner type interstitial cystitis. *Sci. Rep.* 6, 28652.
- Akiyama Y., Maeda D., Morikawa T., Niimi A., Nomiya A., Yamada Y., Igawa Y., Goto A., Fukayama M. and Homma Y. (2017). Digital quantitative analysis of mast cell infiltration in interstitial cystitis. *Neurourol. Urodyn.* 37, 650-657.
- Akiyama Y., Niimi A., Nomiya A., Yamada Y., Nakagawa T., Fujimura T., Fukuhara H., Kume H., Igawa Y. and Homma Y. (2018). Extent of hunner lesions: The relationships with symptom severity and clinical parameters in hunner type interstitial cystitis patients. *Neurourol. Urodyn.* 37, 1441-1447.
- Aldenberg F., Fall M. and Enerback L. (1986). Proliferation and transepithelial migration of mucosal mast cells in interstitial cystitis. *Immunology* 58, 411-416.
- Chennamsetty A., Khourdaji I., Goike J., Killinger K.A., Girdler B. and Peters K.M. (2015). Electrosurgical management of hunner ulcers in a referral center's interstitial cystitis population. *Urology* 85, 74-78.
- Christmas T.J. and Rode J. (1991). Characteristics of mast cells in normal bladder, bacterial cystitis and interstitial cystitis. *Br. J. Urol.* 68, 473-478.
- Cox M., Klutke J.J. and Klutke C.G. (2009). Assessment of patient outcomes following submucosal injection of triamcinolone for treatment of hunner's ulcer subtype interstitial cystitis. *Can. J. Urol.* 16, 4536-4540.
- Cox A., Golda N., Nadeau G., Curtis Nickel J., Carr L., Corcos J. and Teichman J. (2016). Cua guideline: Diagnosis and treatment of interstitial cystitis/bladder pain syndrome. *Can. Urol. Assoc. J.* 10, E136-E155.
- Denson M.A., Griebing T.L., Cohen M.B. and Kreder K.J. (2000). Comparison of cystoscopic and histological findings in patients with suspected interstitial cystitis. *J. Urol.* 164, 1908-1911.
- Dundore P.A., Schwartz A.M. and Semerjian H. (1996). Mast cell counts are not useful in the diagnosis of nonulcerative interstitial cystitis. *J. Urol.* 155, 885-887.
- Erickson D.R., Belchis D.A. and Dabbs D.J. (1997). Inflammatory cell types and clinical features of interstitial cystitis. *J. Urol.* 158, 790-793.
- Fall M., Johansson S.L. and Aldenberg F. (1987). Chronic interstitial cystitis: A heterogeneous syndrome. *J. Urol.* 137, 35-38.
- Feltis J.T., Perez-Marrero R. and Emerson L.E. (1987). Increased mast cells of the bladder in suspected cases of interstitial cystitis: A possible disease marker. *J. Urol.* 138, 42-43.
- Gamper M., Regauer S., Welter J., Eberhard J. and Viereck V. (2015). Are mast cells still good biomarkers for bladder pain syndrome/interstitial cystitis?. *J. Urol.* 193, 1994-2000.
- Gillenwater J.Y. and Wein A.J. (1988). Summary of the national institute of arthritis, diabetes, digestive and kidney diseases workshop on interstitial cystitis, national institutes of health, Bethesda, Maryland, August 28-29, 1987. *J. Urol.* 140, 203-206.
- Hanno P. and Dmochowski R. (2009). Status of international consensus on interstitial cystitis/bladder pain syndrome/painful bladder syndrome: 2008 snapshot. *Neurourol. Urodyn.* 28, 274-286.
- Hanno P.M., Erickson D., Moldwin R., Faraday M.M. and American Urological Association (2015). Diagnosis and treatment of interstitial cystitis/bladder pain syndrome: AUA guideline amendment. *J. Urol.* 193, 1545-1553.
- Hillelsohn J.H., Rais-Bahrami S., Friedlander J.I., Okhunov Z., Kashan M., Rosen L. and Moldwin R.M. (2012). Fulguration for hunner ulcers: Long-term clinical outcomes. *J. Urol.* 188, 2238-2241.
- Homma Y., Ueda T., Tomoe H., Lin A.T., Kuo H.C., Lee M.H., Oh S.J., Kim J.C. and Lee K.S. (2016). Clinical guidelines for interstitial cystitis and hypersensitive bladder updated in 2015. *Int. J. Urol.* 23, 542-549.
- Johansson S.L. and Fall M. (1990). Clinical features and spectrum of light microscopic changes in interstitial cystitis. *J. Urol.* 143, 1118-1124.
- Johansson S.L. and Fall M. (1994). Pathology of interstitial cystitis. *Urol. Clin. North Am.* 21, 55-62.
- Kastrup J., Hald T., Larsen S. and Nielsen V.G. (1983). Histamine content and mast cell count of detrusor muscle in patients with interstitial cystitis and other types of chronic cystitis. *Br. J. Urol.* 55, 495-500.
- Kim H.J. (2016). Update on the pathology and diagnosis of interstitial cystitis/bladder pain syndrome: A review. *Int. Neurourol. J.* 20, 13-17.
- Kim A., Han J.Y., Ryu C.M., Yu H.Y., Lee S., Kim Y., Jeong S.U., Cho Y.M., Shin D.M. and Choo M.S. (2017). Histopathological characteristics of interstitial cystitis/bladder pain syndrome without hunner lesion. *Histopathology* 71, 415-424.
- Larsen S., Thompson S.A., Hald T., Barnard R.J., Gilpin C.J., Dixon J.S. and Gosling J.A. (1982). Mast cells in interstitial cystitis. *Br. J. Urol.* 54, 283-286.
- Leiby B.E., Landis J.R., Probert K.J., Tomaszewski J.E. and Interstitial Cystitis Data Base Study Group (2007). Discovery of morphological subgroups that correlate with severity of symptoms in interstitial cystitis: A proposed biopsy classification system. *J. Urol.* 177, 142-148.
- Liu H.T., Shie J.H., Chen S.H., Wang Y.S. and Kuo H.C. (2012). Differences in mast cell infiltration, e-cadherin, and zonula occludens-1 expression between patients with overactive bladder and interstitial cystitis/bladder pain syndrome. *Urology* 80, 225 e213-228.
- Logadottir Y., Delbro D., Lindholm C., Fall M. and Peeker R. (2014a). Inflammation characteristics in bladder pain syndrome essic type 3C/classic interstitial cystitis. *Int. J. Urol.* 21 Suppl 1, 75-78.
- Logadottir Y., Delbro D., Fall M., Gjerdtsson I., Jirholt P., Lindholm C. and Peeker R. (2014b). Cytokine expression in patients with bladder pain syndrome/interstitial cystitis essic type 3C. *J. Urol.* 192, 1564-1568.
- Lynes W.L., Flynn S.D., Shortliffe L.D., Lemmers M., Zipser R., Roberts L.J. 2nd and Stamey T.A. (1987). Mast cell involvement in interstitial cystitis. *J. Urol.* 138, 746-752.
- Lynes W.L., Flynn S.D., Shortliffe L.D. and Stamey T.A. (1990). The histology of interstitial cystitis. *Am. J. Surg. Pathol.* 14, 969-976.
- Maeda D., Akiyama Y., Morikawa T., Kunita A., Ota Y., Katoh H., Niimi A., Nomiya A., Ishikawa S., Goto A., Igawa Y., Fukayama M. and Homma Y. (2015). Hunner-type (classic) interstitial cystitis: A distinct inflammatory disorder characterized by pancystitis, with frequent expansion of clonal B-cells and epithelial denudation. *PLoS one* 10, e0143316.
- Messing E.M. and Stamey T.A. (1978). Interstitial cystitis: Early diagnosis, pathology, and treatment. *Urology* 12, 381-392.
- Niimi A., Nomiya A., Yamada Y., Suzuki M., Fujimura T., Fukuhara H., Kume H., Igawa Y. and Homma Y. (2016). Hydrodistension with or

Pathology and terminology of interstitial cystitis

- without fulguration of hunner lesions for interstitial cystitis: Long-term outcomes and prognostic predictors. *Neurourol. Urodyn.* 35, 965-969.
- Nordling J., Anjum F.H., Bade J.J., Bouchelouche K., Bouchelouche P., Cervigni M., Elneil S., Fall M., Hald T., Hanus T., Hedlund H., Hohlbrugger G., Horn T., Larsen S., Leppilahti M., Mortensen S., Nagendra M., Oliveira P.D., Osborne J., Riedl C., Sairanen J., Tinzi M. and Wyndaele J.J. (2004). Primary evaluation of patients suspected of having interstitial cystitis (ic). *Eur. urol.* 45, 662-669.
- Pang X., Marchand J., Sant G.R., Kream R.M. and Theoharides T.C. (1995). Increased number of substance p positive nerve fibres in interstitial cystitis. *Br. J. Urol.* 75, 744-750.
- Peeker R., Enerback L., Fall M. and Aldenborg F. (2000). Recruitment, distribution and phenotypes of mast cells in interstitial cystitis. *J. Urol.* 163, 1009-1015.
- Shie J.H. and Kuo H.C. (2011). Higher levels of cell apoptosis and abnormal E-cadherin expression in the urothelium are associated with inflammation in patients with interstitial cystitis/painful bladder syndrome. *BJU Int.* 108, E136-141.
- Theoharides T.C., Sant G.R., el-Mansoury M., Letourneau R., Ucci A.A. Jr and Meares E.M. Jr (1995). Activation of bladder mast cells in interstitial cystitis: A light and electron microscopic study. *J. Urol.* 153, 629-636.
- Utz D.C. and Zincke H. (1974). The masquerade of bladder cancer in situ as interstitial cystitis. *J. Urol.* 111, 160-161.
- van de Merwe J.P., Nordling J., Bouchelouche P., Bouchelouche K., Cervigni M., Daha L.K., Elneil S., Fall M., Hohlbrugger G., Irwin P., Mortensen S., van Ophoven A., Osborne J.L., Peeker R., Richter B., Riedl C., Sairanen J., Tinzi M. and Wyndaele J.J. (2008). Diagnostic criteria, classification, and nomenclature for painful bladder syndrome/interstitial cystitis: An ESSIC proposal. *Eur. Urol.* 53, 60-67.
- Warren J.W. (2014). Bladder pain syndrome/interstitial cystitis as a functional somatic syndrome. *J. Psychosom. Res.* 77, 510-515.
- Yamada T., Murayama T., Mita H. and Akiyama K. (2000). Subtypes of bladder mast cells in interstitial cystitis. *Int. J. Urol.* 7, 292-297.

Accepted July 17, 2018