

# Matrix metalloproteinase-1 (MMP-1) and (MMP-8) gene polymorphisms promote increase and remodeling of the collagen III and V in posterior tibial tendinopathy

Tulio Diniz-Fernandes<sup>1</sup>, Alexandre Leme Godoy-Santos<sup>1</sup>,  
Maria Cristina Santos<sup>2</sup>, Pedro Pontin<sup>1</sup>, Caio Augusto Alves Pereira<sup>3</sup>, Yuri Justi Jardim<sup>3</sup>,  
Ana Paula Pereira Velosa<sup>3</sup>, Nicola Maffulli<sup>4</sup>, Walcy Rosolia Teodoro<sup>3</sup> and Vera Luiza Capelozzi<sup>5</sup>

<sup>1</sup>Department of Orthopedic Surgery, University of São Paulo, São Paulo, <sup>2</sup>Department of Genetic, Federal University of Paraná, PR, Curitiba, Paraná, <sup>3</sup>Department of Rheumatology, University of São Paulo, São Paulo, Brasil, <sup>4</sup>Centre for Sports and Exercise Medicine Barts and The London School of Medicine and Dentistry, London, United Kingdom and <sup>5</sup>Department of Pathology, University of São Paulo, São Paulo, Brazil

**Summary.** Posterior tibial tendinopathy (PTT) can lead to acquired flatfoot in adults. Many patients develop PTT without any identifiable risk factors. Molecular changes in extracellular matrix (ECM) and matrix metalloproteinase (MMP) polymorphism may influence the risk of developing PTT. We aim to investigate the association between matrix metalloproteinase-1 (MMP-1) and (MMP-8) gene polymorphisms with changes in collagen I, III and V in PTT. A case-control study with 22 patients and 5 controls was performed. The MMP-1 (2G/2G) and MMP-8 (T/T) genotypes were determined by PCR-restriction fragment length polymorphism. Tendon specimens were evaluated by a histologic semiquantitative score, immunofluorescence and histomorphometry for collagen I, III and V. Tendon specimens from PTT demonstrated marked distortion of the architecture with necrosis, large basophilic areas with disruption of the normal linear orientation of collagen bundles, infiltration of inflammatory cells, dystrophic calcification and ossification. Under immunofluorescence, PTT tendon specimens showed weak green fluorescence and diffuse distribution of

collagen I fibers, but strong fluorescence of collagen III and V. The collagen I fibers were significantly decreased whereas an increase of collagen III and V were found in PTT compared to control groups. In addition, PTT group presented a significant association with MMP-1 and MMP-8 gene polymorphisms. Patients with PTT matrix metalloproteinase-1 (MMP-1) and (MMP-8) gene polymorphisms presented an increase of the collagen III and V ratio, suggesting that the higher proportion in degenerated tendons could contribute to a decrease in the mechanical resistance of the tissue. Still, functional and association studies are needed to elucidate evident roles of MMPs in PTT.

**Key words:** Tendinopathy, Genetic, Extracellular matrix, Metalloproteinase, Collagen

## Introduction

Posterior tibial tendinopathy (PTT) is a multifactorial disorder that represents the most common cause of adult-acquired flatfoot deformity (Johnson, 1980; Funk et al., 1986; Mosier et al., 1998; Dyal et al., 1997; Posthumus et al., 2009). This deformity is most commonly seen in middle-aged women, caucasian, obese, diabetic, rheumatic, and hypertensive patients (Kohls-Gatzoulis et al., 2009; Baroneza et al., 2014) and has been linked to increased genetic susceptibility

*Offprint requests to:* Walcy Rosolia Teodoro, PhD, Discipline of Rheumatology, University of São Paulo, Brazil. e-mail: [walcy.teodoro@fm.usp.br](mailto:walcy.teodoro@fm.usp.br) or Vera Luiza Capelozzi, MD, PhD, Associate Professor of Lung Pathology, Department of Pathology, University of São Paulo, Brazil. [vera.capelozzi@fm.usp.br](mailto:vera.capelozzi@fm.usp.br)  
DOI: 10.14670/HH-11-982

(Reuther et al., 2013; Godoy-Santos et al., 2014). Clinically it is characterized by valgus alignment of the hindfoot, plantarflexion of the talus, collapse of the longitudinal arch and abduction of the forefoot, at a on molecular level it is characterized by changes in extracellular matrix (Gonçalves-Neto et al., 2002; Satomi et al., 2008; Godoy-Santos et al., 2013, 2014).

The main component of the tendon is collagen (Tasci et al., 2008) with collagen I mainly responsible for its mechanical properties. Collagen I is a heterotrimer consisting of the two  $\alpha$ -1(I) and one  $\alpha$ -2(I) chains arranged in a parallel fashion. Collagen IV is the main component of the basal membrane, collagen III and V originate thin fibrils that interweave with collagen I. Collagen III and V are both responsible for the elasticity of the tendon tissue. The ECM of a normal tibialis posterior tendon contains 95% of collagen I, and small amounts of collagen III, IV and V.

In PTT, the ECM of the tendon shows an increase of 53.6% in collagen III and 26.4% of collagen V, and a decrease of 40.4% in the alpha-1 chain and 42.5% in the alpha-2 chain of collagen I. This different biochemical pattern may explain poorer mechanical properties of the tendon, leading to PTT (Gonçalves-Neto et al., 2002; Godoy-Santos et al., 2014).

MMPs are responsible for the degradation and removal of collagen and could play an important role in the tendinopathy process. MMP-1 (collagenase-1) and MMP-8 (collagenase-2) degrade all collagen molecules and are especially important in the degradation of fibrillary collagen (Kannus, 2000). Normally, the expression of collagenases is low, but it is readily induced by phorbol esters, growth factors, and inflammatory cytokines. Their expression can also be induced in response to local conditions such as mechanical load or inflammatory processes (Karousou et al., 2008).

The MMP-1 and MMP-8 genes are located on chromosome 11q22; an insertion of a guanine at position -1607 of MMP-1 produces the 2G allele, while polymorphism at position -799 of MMP-8 is characterized by the substitution of a cytosine (C) for a thymine (T). Our group showed that polymorphisms in the promoters of MMP-1 and MMP-8 are associated with tendinopathy of the tibialis posterior tendon (Godoy-Santos et al., 2014).

To our knowledge, there are no studies associating the MMP genotype with the histological change patterns and composition of collagen in tendon tissue. We hypothesized that MMP-1 and MMP-8 polymorphisms are associated with marked changes in the percentage of collagen in the ECM of tibialis posterior tendons in patients with PTT. We therefore investigated the association between genotype -1607 (rs1799750) of MMP-1 and -799 (rs11225395) of MMP-8 and changes in collagen types I, III, and V in the ECM of tibialis posterior tendon.

## Materials and methods

Ethics approval was granted by our University IRB/Ethics Committee and registered at Clinical Trials National Register under number 0901/09. Written informed consent was obtained from each participant. This case-control cross-sectional study was designed with two groups. We obtained samples at convenience.

### Patients and controls

PTT specimens were collected from 22 female patients (median age at operation 55 years, range 35 to 79 years) who underwent surgery for grade 2 (12 patients) or 3 (10 patients) PTT dysfunction (PTTd) tendinopathy, identified in all patients by MRI, confirmed by histology. Patients with grade II PTTd underwent resection of the distal portion of the posterior tibialis tendon, tenodesis of the proximal portion of the PTT with the tendon of flexor digitorum longus, transfer of the tendon of flexor digitorum longus to the navicular, and varus sliding osteotomy of the calcaneus. Patients with grade III PTTd underwent resection of the posterior tibialis tendon, triple arthrodesis, and correction of the hindfoot valgus. None of the subjects had a BMI greater than 30, diabetes, rheumatic or autoimmune disorders, liver or kidney disease, and infection or trauma in the foot and ankle.

Five posterior tibialis tendon specimens were collected from subjects who died from violent causes (age at death: 43.2 years, range 35 to 50 years). None of the subjects in the control group had a history of PTTd, foot and ankle deformities, or previous surgery in the foot and ankle. None of the subjects in the control group had a history of obesity, diabetes, rheumatic or autoimmune disorders, liver or kidney disease, and infection or trauma in the foot and ankle. All tendon specimens underwent histological analysis.

### DNA extraction and genotyping analysis

Posterior tibialis tendon specimens were collected from their insertion on the navicular using a midfoot medial approach for a length of 5 to 7 cm. DNA from epithelial buccal cells was extracted as previously described (Aidar and Line, 2007).

DNA from epithelial buccal cells was extracted using the procedure described by Aidar & Line (Aidar and Line, 2007). DNA concentration (ng/ $\mu$ L) was estimated by measurements of optical density with a 260/280 nm ratio greater than 1.9.

The SNPs were previously identified and reported in the database of the National Center for Biotechnology Information (<http://www.ncbi.nlm.nih.gov/SNP/>) with minor allele frequencies greater than 0.2. The MMP genotypes were determined using PCR-RFLP assays. The primer sequences, PCR conditions, and restriction enzymes are detailed in Table 1.

## Collagen remodeling and matrix metalloproteinases polymorphisms

PCR reactions were carried out in a total volume of 15  $\mu$ L containing 400 ng of genomic DNA, 8  $\mu$ L Taq Green (Amersham Pharmacia-Biotech, Uppsala, Sweden), and 200 nmol of each primer. A 10- $\mu$ L aliquot of PCR products was then digested with 1 unit of specific enzyme (indicated below) overnight. The total amount of the digested aliquot was electrophoresed on a 5% agarose at 20 mA. The gel was stained by GelRed (Biotium).

The polymorphism at position -1607 of MMP-1 is characterized by the insertion of a guanine base (G), creating two different alleles (1G or 2G). Restriction enzyme *XmnI* recognizes the 1G allele and digested the PCR product (118 base pairs) in two parts (89 and 29 base pairs). In electrophoresis, the 2G allele was represented by a DNA band of 118 base pairs, the 1G allele by a DNA band of 89 base pairs, while the heterozygote showed a combination of both alleles (118 and 89 base pairs). During electrophoresis, the 29-base pair band exited the gel.

The polymorphism at position -799 of MMP-8 is characterized by the substitution of a base of cytosine (C) with a base of thymine (T) resulting in two alleles: C and T. Restriction enzyme *BfmI* recognizes the C allele and digested the PCR product (106 base pairs) in two parts (74 and 32 base pairs). In electrophoresis, the T allele was represented by a DNA band of 106 base pairs, the C allele by a DNA band of 74 base pairs, while the heterozygote presented a combination of both alleles (106 and 74 base pairs). During electrophoresis, the 32-base pair band exited the gel.

### Histology and semiquantitative analysis

Tendons were fixed by immersion in 10% neutral buffered formalin. After decalcification for 1 to 4 days with 7% nitric acid, the tissue was neutralized by soaking it in a sodium sulfate solution for one day and then washed for 10 hours under running water. The tendon samples were cut from a longitudinal position. After being embedded in paraffin, the tissue was sliced using a microtome. From each tendon, 6 slices were obtained at 4-5  $\mu$ m thickness spaced at 50  $\mu$ m. Thin sections were stained according to the hematoxylin and eosin (HE) double staining method. Two pathologists (VLC and WRT) examined the tendon specimens and found the following changes: basophilic degeneration,

fragmentation of collagen, vascular proliferation, raising the synovium by fibroblast proliferation, inflammatory infiltrate, necrosis, calcification, and ossification. The extension and distribution of the above parenchymal alterations were not homogeneous along the tendon. Thus, the severity of the various pathological processes was rated semi-quantitatively according to the amount and severity of disease using a modified Bonar Score (Fearon et al., 2014). The review of the Bonar Score and suggestions for changes to the scale were completed by consensus in the following grade:

- 0: absence of tendon alterations;
- 1: tendon alterations in 1 to 25% of the examined tissue;
- 2: tendon alterations in 26 to 50% of the examined tissue;
- 3: tendon alterations in 51 to 75% of the examined tissue;
- 4: tendon alterations in 76 to 100% of the examined tissue.

The semi-quantitative scores of tendon lesions represent the average of extension and intensity of lesions present in all histologic sections examined (three or four), which, in turn, represents the most compromised areas identified on gross examination of the tendons.

### Collagen I, III, V and histomorphometry analysis

Immunofluorescence was done to characterize the collagen I, III and V fibers in tendon 4-5  $\mu$ m thick sections attached onto slides previously treated with 3-aminopropyltriethoxy silane (Sigma Chemical Co., St. Louis, MO, USA). The reaction was initiated by deparaffinization of the sections by soaking in xylene at 60°C for 30 minutes in two baths, followed by 10 minutes in xylene at room temperature. Rehydration was undertaken by successive washes with decreasing concentrations of ethanol (100-75%), followed by washing in running water for 10 minutes in a distilled water bath, and 10 minutes in sodium phosphate buffer pH 7,4 (PBS). For exposure of antigenic sites and retrieval, sections were digested with bovine pepsin (Sigma Chemical Co.; 10000 ICU/mL) at a concentration of 8 mg/mL in 0.5 N acetic acid for 45 minutes at 37°C. The sections were then washed with PBS three times for 10 minutes each time, and

**Table 1.** PCR-RFLP conditions for the detection of MMP-1 (-1607) and MMP-8 (-799) polymorphisms.

| SNP          | Primers (5'-3')  | Annealing    | RFLP         | pb PCR-RFLP                          | Reference                  |
|--------------|--|--------------|--------------|--------------------------------------|----------------------------|
| MMP-1(-1607) | F*: TCGTGAGAATGTCTTCCCAT<br>R**: TCTTGGATTGATTTGAGATAAGTGAAATC | 55°C<br>30 s | XmnI<br>37°C | 118 (Allele 2G)<br>89+29 (Allele 1G) | Godoy-Santos et al., 2013  |
| MMP-8 (-799) | F*: CAGAGACTCAAGTGGGA<br>R**: TTTCATTTGTGGAGGGGC               | 51°C<br>1 m  | BfmI<br>37°C | 106 (Allele T)<br>74+32 (Allele C)   | Godoy-Santos et. al., 2013 |

\*Primer Forward, \*\* Primer Reverse.

nonspecific sites blocked with 5% bovine serum albumin in PBS for 30 minutes at room temperature. The slides were incubated overnight with anti-collagen type I antibodies (1:50) (Rockland, Immunochemicals Inc. Limerick, PA, USA), III (1:50) (Abcam, Cambridge, UK) and V (1:50) (Sigma Chemical Co.) in PBS solution. The sections were then washed in PBS with 0.05% Tween 20, and incubated for 90 minutes with rabbit anti-goat IgG antibody and anti-mouse IgG conjugated Alexa 488 (Invitrogen, Carlsbad, CA, USA) diluted 1:200 in PBS solution containing 0.006% Evans blue. Finally, the slides were again washed five times for 10 minutes with PBS with 0.05% Tween 20, mounted with buffered glycerol solution, and examined under a fluorescence microscope (Olympus BX-51, Olympus Co., Tokyo, Japan).

Histomorphometric analysis was performed to quantify the density of immunostained fibers of collagen type I, III, and V using automated image analysis. Briefly, the system consisted of a camera (Olympus Co.) attached to a microscope (Olympus BX-51, Olympus Co.), which captures images and sends them to the monitor for scanning (Oculus TCX, Coreco, Inc., St. Laurent, Quebec Canada). The images were processed by commercially available image analysis software *Image-Pro plus 6.0* to quantify the green fluorescent immunostained fibers. The density of collagen fibers was measured in all microscopic fields. An observer blinded as to whether the specimen being analyzed came from a patient or a control randomly acquired 10 images per each specimen, at 400x magnification and the area of each field was measured in  $\mu\text{m}$  (Alfredson, 2005). The average collagen content area was divided by the average of the total area analyzed, and the result was expressed as a percentage.

### Statistical analysis

All statistical analyses were performed using SPSS version 18 (Inc., Chicago, IL). Data were tabulated considering the descriptive statistics (mean and standard deviation) for quantitative and semiquantitative data and frequency tables for the qualitative. The association between clinical, molecular profile, histology, immunofluorescence and histomorphometry was first compared using Fisher's exact test or chi-square test of Kruskal-Wallis. The  $p$  value  $\leq 0.05$  was considered to be significant.

### Results

All patients presented both the 2G/2G of -1607MMP-1 and T/T of -799 MMP-8 polymorphisms genes, whereas the subjects in the control group presented the G/G -1607 MMP-1 and C/C -799 MMP-8.

Fig. 1A-1H shows H&E staining of tendon tissues from control and study groups. Tendons from the control group showed parallel or linear orientation of collagen bundles, low angiogenesis, and scarce fibroblast

proliferation (Fig. 1A) coincident with the maintenance of their architecture. In contrast, tendon specimens from the study group demonstrated marked distortion of the architecture with necrosis (Fig. 1B), large basophilic areas (Fig. 1C) with disruption of the normal linear orientation of collagen bundles and fibrils (Fig. 1D). Similarly, tendon sections from the study group showed increased synovia by fibroblast proliferation (Fig. 1E) and infiltration of inflammatory cells (Fig. 1F). Finally, the remodeling process of tendinopathy in the tendon specimens of study group was characterized by dystrophic calcification (Fig. 1G) and ossification (Fig. 1H).

Fig. 1I-1L shows the distribution of histopathological parameters according to PTTd grade. Compared to controls, tendon from patients with PTTd presented a significant amount of necrosis ( $2.8 \pm 1.61$  vs.  $0.80 \pm 1.42$ ;  $p < 0.01$ ), basophilic degeneration of collagen fibers ( $3.40 \pm 0.84$  vs.  $2.41 \pm 1.08$ ;  $p = 0.03$ ), collagen fiber fragmentation ( $2.77 \pm 0.17$  vs.  $1.0 \pm 0.0$ ;  $p < 0.01$ ), vessel neoformation ( $2.86 \pm 0.17$  vs.  $0.8 \pm 0.2$ ;  $p < 0.01$ ), inflammation ( $2.70 \pm 0.48$  vs.  $1.75 \pm 0.45$ ;  $p = 0.001$ ) and ossification/calcification ( $2.90 \pm 0.74$  vs.  $1.66 \pm 0.88$ ;  $p = 0.002$ ).

Fig. 2A-2F shows the immunofluorescence analysis of collagen I, III and V in control and patients. Clearly, tendons from the control group showed green fluorescence for collagen I, III and V, with parallel orientation of collagen I fibers in all areas of the tendon (Fig. 2A), interaction between collagen III and type I collagen fibers in a similar pattern (Fig. 2B) and a finely reticulated pattern of type V collagen fibers (Fig. 2C). In contrast, tendon specimens from the study group showed discrete collagen I green fluorescence and diffuse distribution of the fibers (Fig. 2D), where as collagen III exhibited the same distribution as collagen I (Fig. 2E), but with prominent fluorescence. Interestingly, collagen V was mostly distributed around the vessel walls (Fig. 2F), resulting in a finely reticulated network and accentuated fluorescence when compared to collagen III fibers.

Fig. 2G-2I shows the distribution of collagen fibers according to PTTd grade. Compared to controls, patients with PTTd also presented a significantly increased percentage of collagen III ( $6.97 \pm 0.40$  vs.  $1.87 \pm 0.30$ ;  $p < 0.01$ ; Fig. 2H) and collagen V ( $6.51 \pm 0.41$  vs.  $1.85 \pm 0.17$ ;  $p < 0.01$ ; Fig. 2I) collagen fibers. In contrast, the percentage of collagen I fibers was significantly decreased in tendons from patients compared to that in tendon from controls ( $22.19 \pm 0.46$  vs.  $66.65 \pm 2.97$ ;  $p < 0.01$ ; Fig. 2G).

### Discussion

The mechanisms of tendinopathy are complex and involve mechanical stress, degenerative changes in the tendon tissue, and disorganized healing along with a contribution from inflammatory processes (Galis et al., 1994). Some tendons are particularly vulnerable to



## Collagen remodeling and matrix metalloproteinases polymorphisms

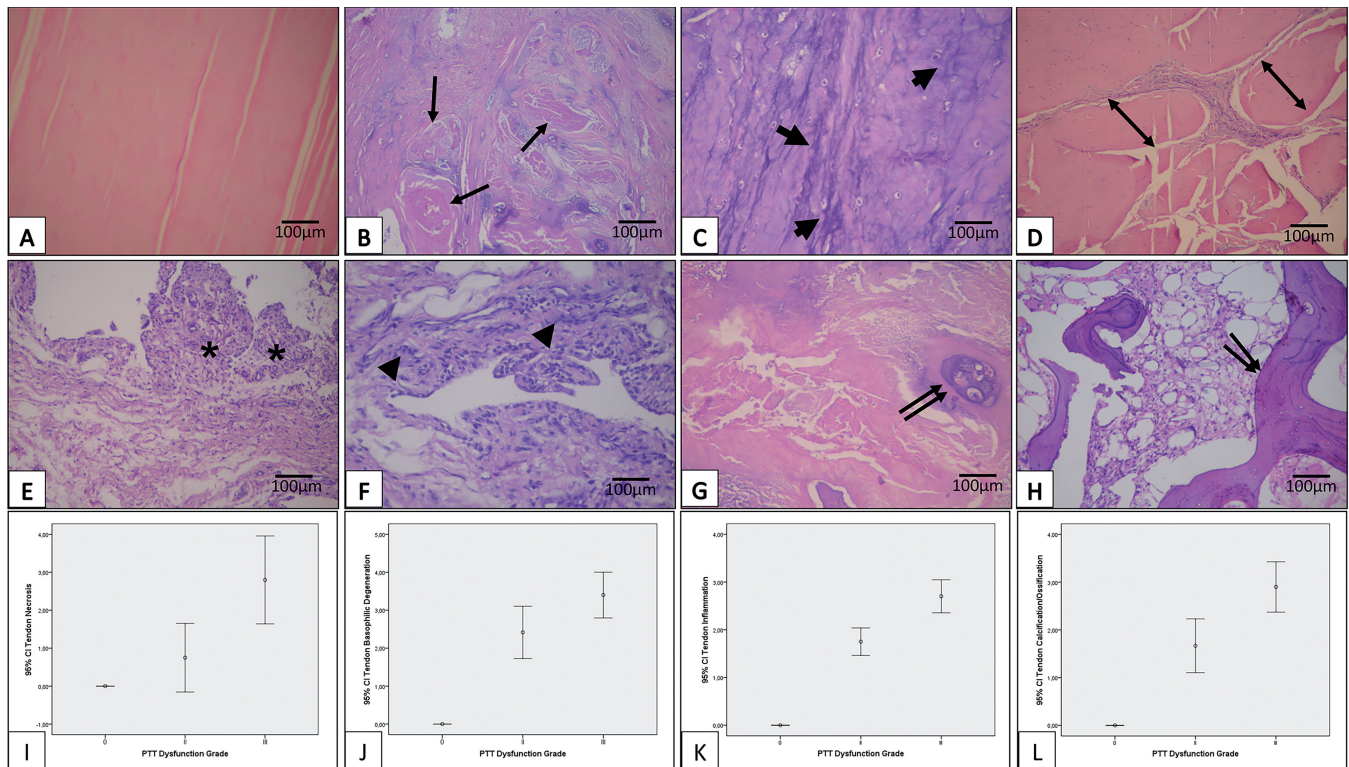
tendinopathy, as observed for rotator cuff, patellar tendon, Achilles tendon, and the posterior tibialis tendon (Maffulli et al., 2003; Mokone et al., 2005). Genetic factors may play a role in the etiology of tendinopathy (Raleigh et al., 2009). Some genetic polymorphisms are associated with tendinopathy. These include type V collagen (COL5A1), type I collagen (COL1A1), tenascin-C and type I collagen (TN-C), the beta transforming growth factor 1 (TGF- $\beta$ 1) variant rs1800469, 5th growth differentiation factor (GDF-5) variant rs143383, and metalloproteinases 1, 3, 8, and 9. (Maffulli et al., 2003; Mokone et al., 2005, 2006; Raleigh et al., 2009; Posthumus et al., 2009, 2010; Lakemeir et al., 2011; Godoy-Santos et al., 2013, 2014; Baroneza et al., 2014).

Our first step in the process to identify genetic factors involved in PTTd was to prove that patients with clinical and imaging diagnosis of PTT presented specific polymorphisms in *MMP-1* and *MMP-8* promoters (Godoy-Santos et al., 2013, 2014). The second step was

to investigate the histological and immunohistochemical impact on the ECM of the posterior tibial tendon tissue in patients with these genetic markers.

Since collagen type I, III and V are the main proteins affecting the ECM during the process of tendinopathy (Gonçalves-Neto et al., 2002), and the principal enzymes degrading these collagens are MMP-1 and MMP-8, the present research focused on the association between MMP-1 and MMP-8 genetic polymorphism with the concentration of collagen type I, III, and V in the ECM of normal and tendinopathic specimens from the posterior tibialis tendon.

From our previous studies, we selected specimens from 22 female patients with a diagnosis of PTTd who presented both the 2G/2G -1607 MMP-1 and T/T -799 MMP-8 polymorphisms. As controls, we selected 5 fresh female cadavers with no history of PTTd, foot and ankle deformities, or previous surgery in the foot and ankle, which presented both the G/G -1607 MMP-1 and C/C -799 MMP-8 polymorphism.



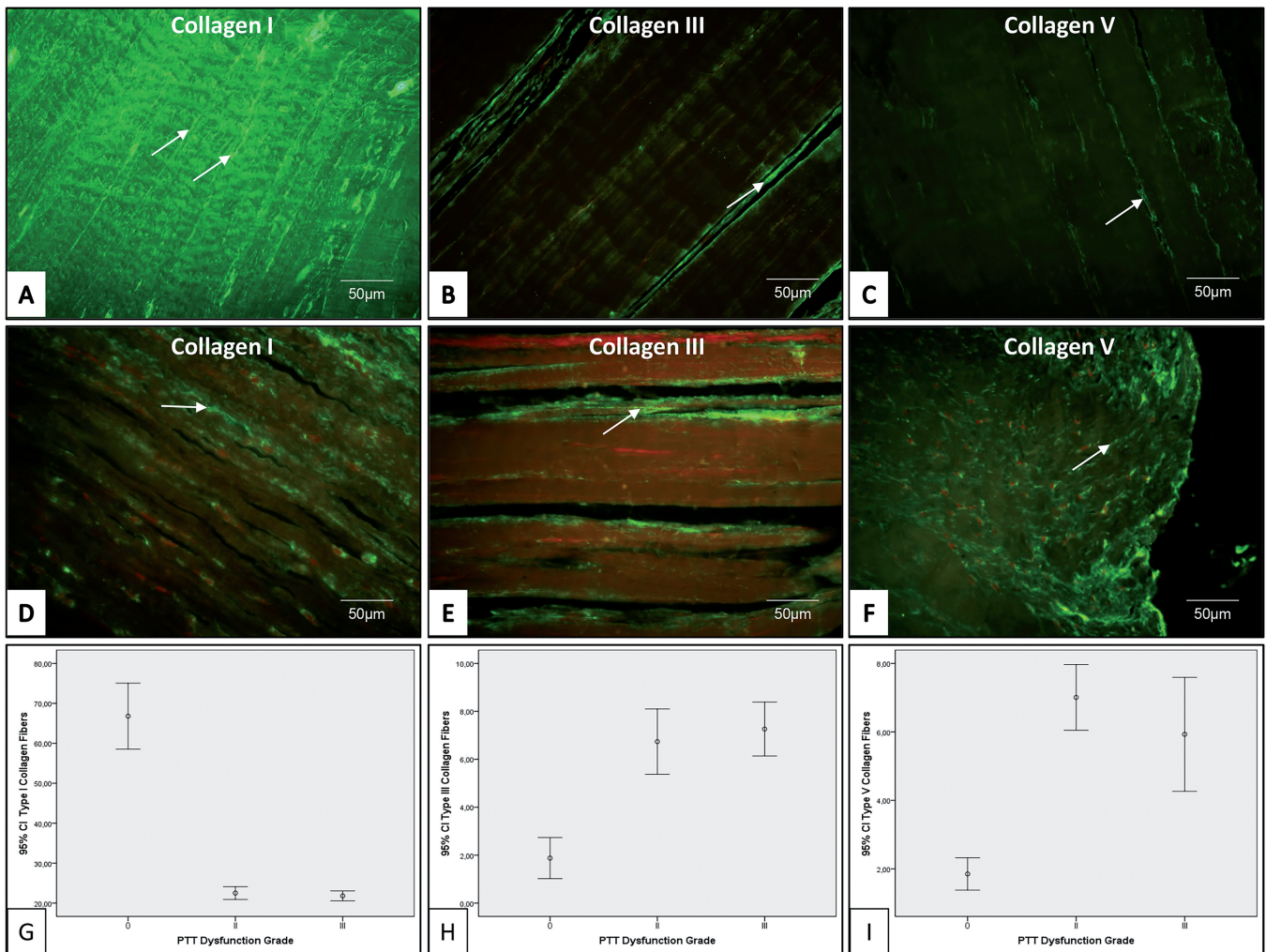
**Fig. 1.** Tendon samples obtained from control and study group, stained with H&E. Tendon specimens from the control group shows maintenance of the histoarchitecture in H&E preparations (A). In contrast, tendon specimens of study group show fibrinoid necrosis (B, arrows), basophilic degeneration of collagen fibers (C), disruption of the normal linear orientation of collagen bundles and fibrils allied to the findings of large, sparse and fragmented bundles of collagen fibers (D). The synovia is polypoid by fibroblast proliferation (E) and infiltrate by inflammatory cells (F). Dystrophic calcification (G) and ossification (H) characterize the final remodeling of tendon architecture. Long arrows indicate the fibrinoid necrosis and dilated vessels in tendon. Short arrows indicate basophilic degeneration of collagen fibers. Double-headed arrows indicate fragmented bundles of collagen fibers. Asterisks indicate synovia elevation. **Graphics I-L** shows the distribution of histopathological parameters according to PTTd grade. Compared to controls, tendon from patients with PTTd presented a significant amount of necrosis ( $2.8 \pm 1.61$  vs.  $0.80 \pm 1.42$ ;  $p < 0.01$ ), basophilic degeneration of collagen fibers ( $3.40 \pm 0.84$  vs.  $2.41 \pm 1.08$ ;  $p = 0.03$ ), collagen fiber fragmentation ( $2.77 \pm 0.17$  vs.  $1.0 \pm 0.0$ ;  $p < 0.01$ ), vessel neoformation ( $2.86 \pm 0.17$  vs.  $0.8 \pm 0.2$ ;  $p < 0.01$ ), inflammation ( $2.70 \pm 0.48$  vs.  $1.75 \pm 0.45$ ;  $p = 0.001$ ) and ossification/calcification ( $2.90 \pm 0.74$  vs.  $1.66 \pm 0.88$ ;  $p = 0.002$ ).

*Collagen remodeling and matrix metalloproteinases polymorphisms*

PTTd leads to acquired flatfoot in adults (Deland et al., 2005; Posthumus et al., 2009). Johnson and Strom (1989) originally classified PTTd in 3 stages, and a further stage was later added by Myerson (1996). In the present study, we chose women with stage II and III PTTd as the target population.

The histopathologic changes in tendinopathy are well established (Xu and Murreal, 2008). Microscopically, the tendon shows disorganized collagen bundles, and the nuclei of tenocytes are dark and

prominent. There is neovascularization and evident small blood vessels, in contrast to the well-organized parallel collagen bundles found in normal tendons, with the nuclei of the spindle shaped normal tenocytes in parallel alignment. These pathological changes are consistent with the failed healing response with neovascularization, typical of tendinopathic specimens (Maffulli et al., 2000; Alfredson, 2005). In our patients with the 2G/2G MMP1 and T/T MMP-8 genotypes, semi-quantitative histological analysis showed marked



**Fig. 2.** Tendon samples obtained from control and study group, stained with collagen I, III and V and visualized under fluorescence microscopy. Note uniform green fluorescence and parallel orientation of type I fibers in all areas of the tendon (A), interaction between type III and type I collagen fibers in a similar pattern (B) and a finely reticulated pattern of type V collagen fibers (C) in control group. D shows tendon specimens from study group with discrete type I collagen green fluorescence and diffuse distribution of the fibers coincident with low percentage when compared to control. Type III collagen fibers in tendon specimens of study group can be appreciated in figure (E) with similar distribution to collagen I fibers and strong fluorescence signal coincident with higher amount when compared to control. A finely reticulated network and strong fluorescent signal of type collagen V fibers in tendon specimens of study group is visualized around the vessel walls (F), coincident with higher amount than control. **Graphics G-I** show the distribution of collagen fibers according to PTTd grade. Compared to controls, patients with PTTd also presented a significantly increased percentage of collagen III ( $6.97 \pm 0.40$  vs.  $1.87 \pm 0.30$ ;  $p < 0.01$ ; **Graphic H**) and collagen V ( $6.51 \pm 0.41$  vs.  $1.85 \pm 0.17$ ;  $p < 0.01$ ; **Graphic I**) collagen fibers. In contrast, the percentage of collagen I fibers was significantly decreased in tendons from patients compared to that in tendon from controls ( $22.19 \pm 0.46$  vs.  $66.65 \pm 2.97$ ;  $p < 0.01$ ; **Graphic G**).



tissue changes in terms of fibrillar degeneration, fragmentation, neovascularity, tenocyte proliferation, and abnormal collagen deposition, with low scores for calcification, necrosis, fibrin, and inflammatory infiltrate.

The role of collagen in tendon is extensively studied; tendinopathy is related to abnormal synthesis of collagen. In this scenario, the failed healing repair typical of a tendinopathy lesion results in altered homeostasis of the ECM, with newly synthesized collagens in abnormal proportions (Riley et al., 2002; Riley, 2005; Godoy-Santos et al., 2013, 2014). Although type I collagen accounts for 65% to 80% of the dry tendon mass, representing almost 95% of total collagen in the ECM of the normal tendon, collagen type II, III, IV, V, VI, IX, X, XII, and XIV are also detected in small amounts in the normal tendon. Changes in the content and composition of collagen have been consistently detected in tendinopathy. These include reduction of the total content of collagen, an increase in the proportion of type III and V, a higher percentage of denatured collagen, and a minor proportion of higher frequency and pentosidine lysine residues crosslinked hydroxylated collagen (Tsuzaki et al., 1993; Waggett et al., 1998; Bank et al., 1999; Kannus, 2000; Riley et al., 2002; Ireland et al., 2001; De Mos et al., 2007).

Our specimens from patients with PTTd showed a significant decrease in collagen type I content ( $p < 0.0001$  Fig. 2G), and a significant increase in type III and V collagen content ( $p < 0.0001$  Fig. 2H, 2I) compared to controls. The present study shows a remarkable association between well-defined genetic polymorphisms and histological changes in tendinopathic tendons of patients with PTTd. Patients with 2G/2G MMP-1 and T/T MMP-8 genotypes present marked and typical alteration in collagen composition.

Significant genetic interactions between ECM components of the posterior tibial tendon and tendinopathy have been observed. These observations point to an important role of MMP-1 and 8 polymorphisms on signaling pathways involved in structural failure of the posterior tibial tendon. Foot and ankle surgeons should be aware of these genetic markers to identify individuals at high risk of adult acquired flatfoot, which should facilitate the application of prevention and management measures. Further understanding of the biological mechanisms underlying the tendinopathy process is an important prerequisite for the development of diagnostic and treatment strategies.

### Conclusion

Our study shows that patients with posterior tibial tendinopathy who present 2G/2G MMP-1 T/T MMP-8 polymorphisms show marked changes in ECM content and composition. In fact, collagen type I is decreased and collagen type III and V are increased compared to controls.

### References

- Aidar M. and Line S.R. (2007). A simple and cost-effective protocol for DNA isolation from buccal epithelial cells. *Braz. Dent. J.* 18, 148-152.
- Alfredson H. (2005). The chronic painful Achilles and patellar tendon: research on basic biology and treatment. *Scand. J. Med. Sci. Sports* 15, 252-259.
- Bank R.A., TeKoppele J.M., Oostingh G., Hazleman B.L. and Riley G.P. (1999). Lysylhydroxylation and non-reducible crosslinking of human supraspinatus tendon collagen: changes with age and in chronic rotator cuff tendinitis. *Ann. Rheum. Dis.* 58, 35-41.
- Baroneza J.E., Godoy-Santos A.L., Massa B.F., Munhoz F.B.A., Fernandes T.D. and Godoy-Santos M.C.L. (2014). MMP-1 promoter genotype and haplotype association with posterior tibial tendinopathy. *Gene* 547, 334-337.
- Corps A.N., Robinson A.H.N., Harrall R.L., Avery N.C., Curry V.A., Hazleman B.L. and Riley G.P. (2012). Changes in matrix protein biochemistry and the expression of Mrna encoding matrix proteins and metalloproteinases in posterior tibialis tendinopathy. *Ann. Rheum. Dis.* 71, 746-752.
- Deland J.T., De Asla R.J., Sung I.H., Emberg L.A. and Potter H.G. (2005). Posterior tibial tendon insufficiency: which ligaments are involved? *Foot Ankle Int.* 26, 427-435.
- Del Buono A., Oliva F., Osti L. and Maffulli N. (2013). Metalloproteases and tendinopathy. *Muscles Ligaments Tendons J.* 3, 51-57.
- De Mos M., Van El B., DeGroot J., Jahr H., Van Schie H.T., Van Arkel E.R., Tol H., Heijboer R., Van Osch G.J. and Verhaar J.A. (2007). Achilles tendinosis: changes in biochemical composition and collagen turnover rate. *Am. J. Sports Med.* 35, 1549-1556.
- Dyal C., Feder J., Deland J.T. and Thompson F.M. (1997). Pes planus in patients with posterior tibial tendon insufficiency: asymptomatic versus symptomatic foot. *Foot Ankle Int.* 18, 85-88.
- Fearon A., Dahistrom J.E., Twin J., Cook J. and Scott A. (2014). The Bonar score revisited: Region of evaluation significantly influences the standardized assessment of tendon degeneration. *J. Sci. Med. Sport.* 17, 346-350.
- Funk D., Cass J.R. and Johnson K.A. (1986). Acquired adult flat foot secondary to posterior tibial-tendon pathology. *J. Bone Joint Surg.* 68, 95-102.
- Galis Z.S., Sukhova G.K., Lark M.W. and Libby P. (1994). Increased expression of matrix metalloproteinases and matrix degrading activity in vulnerable regions of human atherosclerotic plaques. *J. Clin. Invest.* 94, 2493-2503.
- Godoy-Santos A.L., Cunha M.V., Ortiz R.T., Fernandes T.D., Mattar R. Jr. and Dos M.C. (2013). MMP-1 promoter polymorphism is associated with primary tendinopathy of the posterior tibial tendon. *J. Orthop. Res.* 31, 1103-1107.
- Godoy-Santos A.L., Ortiz R.T., Mattar R. Jr., Fernandes T.D. and Santos M.C. (2014). MMP-8 polymorphism is genetic marker to tendinopathy primary posterior tibial tendon. *Scand. J. Med. Sci. Sports.* 24, 220-223.
- Gonçalves-Neto J., Witzel S.S., Teodoro W.R., Carvalho A.E.Jr., Fernandes T.D. and Yoshinari N.H. (2002). Changes in collagen matrix composition in human posterior tibial tendon dysfunction. *Joint Bone Spine* 69, 189-194.
- Ireland D., Harrall R., Curry V., Holloway G., Hackney R., Hazleman B. and Riley G.P. (2001). Multiple changes in gene expression in chronic human Achilles tendinopathy. *Matrix Biol.* 20, 159-169.

- Johnson K.A. (1983). Tibialis posterior tendon rupture. *Clin. Orthop.* 177, 140-147.
- Johnson K.A. and Strom D.E. (1989). Tibialis posterior tendon dysfunction. *Clin. Orthop.* 239, 196-206.
- Kannus P. (2000). Structure of the tendon connective tissue. *Scand. J. Med. Sci. Sports* 10, 312-320.
- Karousou E., Ronga M., Vigeiti D., Passi A. and Maffulli N. (2008). Collagens, proteoglycans, MMP-2, MMP-9 and TIMPs in human achilles tendon rupture. *Clin. Orthop. Relat. Res.* 466, 1577-1582.
- Kerrigan J.J., Mansell J.P. and Sandy J.R. (2000). Matrix turnover. *J. Orthod.* 27, 227-233.
- Kohls-Gatzoulis J., Woods B., Angel J.C. and Singh D. (2009). The prevalence of symptomatic posterior tibialis tendon dysfunction in women over the age of 40 in England. *Foot Ankle Surg.* 15, 75-81.
- Lakemeir S., Braun J., Efe T., Foelsch C., Archontidou-Aprin E., Fuchs-Winkelmann S., Paletta J.R. and Schofer M.D. (2011). Expression of matrix metalloproteinases 1,3 and 9 in differing extents of tendon retraction in torn rotator cuff. *Knee. Surg. Sports Traumatol. Arthrosc.* 19, 1760-1765.
- Maffulli N., Barrass V. and Ewen S.W. (2000). Light microscopic histology of achilles tendon ruptures. A comparison with unruptured tendons. *Am. J. Sports Med.* 28, 857-863.
- Maffulli N., Wong J. and Almekinders L.C. (2003). Types and epidemiology of tendinopathy. *Clin. Sports Med.* 22, 675-692.
- Mokone G.G., Gajjar M., September A.V., Schwellnus M.P., Greenberg J., Noakes T.D. and Collins M. (2005). The guanine-thymine dinucleotide repeat polymorphism within the tenascin-C gene is associated with Achilles tendon injuries. *Am. J. Sports Med.* 33, 1016-1021.
- Mokone G.G., Schwellnus M.P., Noakes T.D. and Collins M. (2006). The COL5A1 gene and Achilles tendon pathology. *Scand. J. Med. Sci. Sports* 16, 19-26.
- Mosier S.M., Lucas D.R., Pomeroy G. and Manoli A. (1998). 2nd. Pathology of the posterior tibial tendon in posterior tibial tendon insufficiency. *Foot Ankle Int.* 19, 520-524.
- Myerson M.S. (1996). Adult acquired flatfoot deformity. *J. Bone Joint Surg.* 78, 780-792.
- Pomeroy G.C., Maine S.P., Pike R.H. and Manoli A. (1999). 2nd. Current concepts review - acquired flatfoot in adults due to dysfunction of the posterior tibial tendon. *J. Bone Joint Surg. Am.* 81, 1173-1182.
- Posthumus M., September A.V., Schwellnus M.P. and Collins M. (2009). Investigation of the Sp1-binding site polymorphism within the COL1A1 gene in participants with Achilles tendon injuries and controls. *J. Sci. Med. Sport* 12, 184-189.
- Posthumus M., Collins M., Cook J., Handley C.J., Ribbans W.J., Smith R.K., Schwellnus M.P. and Raleigh S.M. (2010). Components of the transforming growth factor-beta family and the pathogenesis of human Achilles tendon pathology - a genetic association study. *Rheumatology (Oxford)* 49, 2090-2097.
- Raleigh S.M., Van der Merwe L., Ribbans W.J., Smith R.K., Schwellnus M.P. and Collins M. (2009). Variants within the MMP3 gene are associated with Achilles tendinopathy: possible interaction with the COL5A1 gene. *Br. J. Sports Med.* 43, 514-520.
- Reuther K.E., Thomas S.J., Evans E.F., Tucker J.J., Sarver J.J., Ilkhani-Pour S., Gray C.F., Voleti P.B., Glaser D.L. and Soslowky L.J. (2013). Returning to overuse activity following a supraspinatus and infraspinatus tear leads to joint damage in a rat model. *J. Biomech.* 46, 1818-1824.
- Riley G.P. (2004). The pathogenesis of tendinopathy. A molecular perspective. *Rheumatology (Oxford)* 43, 131-142.
- Riley G.P. (2005). Gene expression and matrix turnover in overused and damaged tendons. *Scand. J. Med. Sci. Sports* 15, 241-251.
- Riley G.P., Curry V., DeGroot J., Van El B., Verzijl N., Hazleman B.L. and Bank R.A. (2002). Matrix metalloproteinase activities and their relationship with collagen remodelling in tendon pathology. *Matrix Biol.* 21, 185-195.
- Satomi E., Teodoro W.R., Parra E.R., Fernandes T.D., Velosa A.P., Capelozzi V.L. and Yoshinari N.H. (2008). Changes in histoanatomical distribution of types I, III and V collagen promote adaptative remodeling in posterior tibial tendon rupture. *Clinics* 63, 9-14.
- Tasci A.I., Tugcu V., Ozbek E., Ozbay B., Simsek A. and Koksall V. (2008). A single-nucleotide polymorphism in the matrix metalloproteinase-1 promoter enhances bladder cancer susceptibility. *BJU Int.* 101, 503-507.
- Tsuzaki M., Yamauchi M. and Banes A.J. (1993). Tendon collagens: extra-cellular matrix composition in shear stress and tensile components of flexor tendons. *Connect. Tissue Res.* 29, 141-152.
- Xu Y. and Murrell G.A. (2008). The basic Science of tendinopathy. *Clin. Orthop. Relat. Res.* 466, 1528-1538.
- Waggett A.D., Ralphs J.R., Kwan A.P., Woodnutt D. and Benjamin M. (1998). Characterization of collagens and proteoglycans at the insertion of the human Achilles tendon. *Matrix Biol.* 16, 457-470.