

Soy isoflavone effects on the adrenal glands of orchidectomized adult male rats: a comprehensive histological and hormonal study

Verica Lj. Milošević¹, Walter B. Severs², Nataša M. Ristić¹,
Milica N. Manojlović-Stojanoski¹, Florina V. Popovska-Perčinić³, Branka T. Šošić-Jurjević¹,
Lazo B. Pendovski³, Svetlana L. Trifunović¹, Marko Š. Miler¹ and Vladimir Z. Ajdžanović¹

¹Department of Cytology, Institute for Biological Research “Siniša Stanković”, University of Belgrade, Belgrade, Serbia, ²Department of Pharmacology, College of Medicine, Pennsylvania State University, Hershey, Pa., USA and ³Faculty of Veterinary Medicine, “Ss. Cyril and Methodius” University in Skopje, Skopje, Macedonia

Summary. Genistein (G) and related soy phytoestrogens have been studied for potential usefulness in different chronic diseases, and may ameliorate signs of aging. They have a profound influence on the hypothalamo-pituitary-adrenal (HPA) axis. The present study utilized the rat model of mild andropause to thoroughly evaluate the effects of G and soy extract on the adrenal gland and related blood hormones. Adult male rats were orchidectomized (Orx) or sham operated (SO). Orx rats received daily subcutaneous injections for 3 weeks of solvent, or G (Orx+G, 30 mg/kg), or commercial soy extract (Orx+Soy, 30 mg/kg). Adrenal glands and blood were harvested at the end of the treatment for hormone analyses, histology and design-based stereology. Compared to SO rats Orx evoked significant ($P<0.05$) changes including: the replicating cell number in the 3 adrenocortical zones; vascularity and cortical volume and blood levels of adrenocorticotrophic hormone (ACTH), aldosterone and dehydroepiandrosterone (DHEA). When comparing Orx vs. Orx+G groups the following significant ($P<0.05$) changes were observed: a further increase in number of replicating cells in zonas glomerulosa and reticularis, vasculature network presence, cortical and zona reticularis volumes, ACTH and corticosterone concentrations, and lower DHEA levels. Comparing Orx vs. Orx+Soy resulted in elevated

($P<0.05$) ACTH and corticosterone levels. Structural integrity of the adrenal gland was unchanged vs. SO rats. Overall, G and soy extract treatments resulted in proliferative activity and/or vasculature support in the adrenal cortex. The data and current literature support the impression of a beneficial effect of soy components on the homeostatic response to stress.

Key words: Soy isoflavones, Adrenal Glands, Stereology, Orchidectomy, Rats

Introduction

Ageing in males is a gradual phenomenon that culminates in a state of andropause (Wespes and Schulman, 2002; Morales, 2004; Chahal and Drake, 2007). An irregular activity of the hypothalamic-pituitary-adrenal (HPA) axis is a characteristic of this multi-symptomatic aging process (Hatzinger et al., 2000). Generally, free testosterone deficiency reflects the hormonal milieu of ageing males, so orchidectomy and the reduction of circulating testosterone and estradiol appear to be important in various animal models of andropause. In our prior research we have studied orchidectomized middle-aged rats to mimic andropause and examined the effects of synthetic steroids/steroid-like compounds on the morphofunctional parameters of pituitary adrenocorticotrophic (ACTH) cells and the adrenal cortex (Ajdžanović et al., 2009a,b, 2011, 2012, 2015, 2016, 2017a,b). In addition to this rat model using aged rats wherein the central regulation of

Offprint requests to: Verica Lj. Milošević, PhD, Department of Cytology, Institute for Biological Research “Siniša Stanković”, University of Belgrade, Despot Stefan Blvd. 142, 11060 Belgrade, Serbia. e-mail: dimi@ibiss.bg.ac.rs
DOI: 10.14670/HH-11-984

glucocorticoid production/secretion is not completely preserved (Trifunović et al., 2012; Ajdžanović et al., 2016), orchidectomized adult rats with functional hippocampal, hypothalamic and limbic neurons and synapses, have also been evaluated during mild andropause (Ke et al., 2000; Blouin et al., 2008; Trifunović et al., 2012, 2014). It should be mentioned that increased pituitary weights as well as higher values of the regulatory, hypothalamic paraventricular nucleus (PVN) volume, percentage of corticotrophin-releasing hormone (CRH) neurons and percentage of activated CRH neurons characterize this model of mild andropause (Trifunović et al., 2012, 2014).

Previous studies also examined the immunohistochemical and fluorescent characteristics of hypothalamic CRH neurons and pituitary ACTH cells, their stereological parameters and the capacity for ACTH secretion, all after the soy isoflavone genistein, or soy extract administration to orchidectomized adult male rats (Trifunović et al., 2012, 2014; Trifunović and Milošević, 2018). In the present study we investigated the histological changes of the adrenal gland under the same experimental protocol. Specifically we evaluated the quantitative and the qualitative histological parameters of the adult rat adrenal gland. This structured and complex HPA axis target gland was assessed after orchidectomy with genistein alone, or by soy extract treatment. Related blood hormone levels were also assessed. Collectively, the above literature along with the present adrenal gland data provide an assessment of isoflavone effects on the hypothalamic, pituitary and adrenal gland components of the orchidectomy model. It should be noted that the isoflavone treatments were of 3 weeks duration rather than short, acute exposure. Thus, the terminal status of the rats likely reflects a physiological and biochemical equilibrium.

Intake of soy isoflavones, the non-nutrient, estrogen-like bioactives of soy-food and therapeutic supplements, is elevated in countries where the incidence of age-related diseases (cardiovascular issues, osteoporosis, various endocrine-related malignancies, etc.) is low, suggesting an ameliorative effect (Setchell, 1998; Mazur and Aldercreutz, 2000). Serious pharmacological approach and good preventive/therapeutic practice require comparison of the biomedical effects of, in various formulations available, pure isoflavones and their mixtures, in creating the remedial strategy. According to our previous results and the available literature, soy products containing high levels of isoflavone daidzein and low levels of genistein or isoflavone β -glucosides (present in soy extracts) could be a more beneficial component of the diet of subjects with cardiovascular issues (Ajdžanović et al., 2012). On the other hand, it was suggested that soy extracts could be more potent than individual soy isoflavones in prostate cancer treatment (Hsu et al., 2010). Finally, some investigations showed that soy isoflavones may act as endocrine disruptors (Lephart et al., 2004), so monitoring for safety during consumption is advisable.

It was previously reported that genistein treatment of orchidectomized adult rats enhanced the proportion of activated CRH neurons, the number of ACTH cells as well as blood ACTH concentration (Trifunović et al., 2012). Supposedly, genistein acts through estrogen receptors (ERs) distributed throughout hypothalamic nucleus paraventricularis, an area functionally connected to the HPA axis (Cho et al., 2007), while the ACTH cells go through intense synthetic and secretory activity during constant hypothalamic stimulation (Trifunović et al., 2012). In line with this, soy extract treatment in the same rats increased ACTH levels, as well as the total and individual volume of ACTH cells (Trifunović et al., 2014). It should be noted that genistein and the structurally similar soy isoflavone daidzein have direct, ER-independent, suppressive effects on ACTH cells, when applied to orchidectomized middle-aged rats (Ajdžanović et al., 2009a, 2011).

The histological objectives in the present study complement the above studies on isoflavone effects on hypothalamic and pituitary components of the HPA axis by analyzing the adrenal gland as the final HPA component. The same protocol was used; *i.e.* orchidectomy alone, or treated with either genistein or a commercial soy extract (containing the mixture of soy isoflavones and their glucosides). Comparison with sham operated rats is also provided. Modern, design-based stereological approaches (Ajdžanović et al., 2017a) were used in combination with the histological and hormonal analyses.

In addition to mimicking andropause, orchidectomy allowed the evaluation of other synthetic steroids/steroid-like compounds on the endocrine status in a hormonal milieu deprived of endogenous sex steroids (Ajdžanović et al., 2009a,b, 2011, 2015, 2016; Trifunović et al., 2012, 2014).

Materials and methods

Animals and diets

The experiments involved 32 adult (2-month-old) Wistar rats. They were bred at the Institute for Biological Research "Siniša Stanković", Belgrade, Serbia; housed two *per* cage, and maintained under constant laboratory conditions (22±2°C, 12-12 h light-dark cycle). Two weeks before the experiment, the rats started to eat a soy-free diet (Picherit et al., 2000; reported in Ajdžanović et al., 2009a,b, 2011; Trifunović et al., 2012, 2014) prepared in cooperation with the Department of Animal Nutrition and Botany, School of Veterinary Medicine, Belgrade, Serbia, and INSHRA PKB, Belgrade, Serbia, with corn oil as a fat source. In brief, the diet contained *per* 100 g: 20.3 g casein; 65 g carbohydrate (45 g cornstarch + 20 g sucrose); 5.2 g corn oil; 3.7 g fiber (crystalline cellulose); 1.5 g vitamin/mineral mix (Ca-phosphate deficient); 1.8 g dibasic calcium phosphate; 1 g calcium carbonate; 1.5 g DL-methionine. Casein and crystal cellulose originated

Andropausal adrenals after isoflavones

from Alfa Aesar, Johnson Matthey GmbH & Co. KG, Karlsruhe, Germany; carbohydrate, oil, vitamin/mineral mix, calcium carbonate, calcium phosphate from INSHRA PKB, Belgrade, Serbia; and DL-methionine from Sigma Chemical Company, St. Louis, MO, USA. Food and water were available *ad libitum*.

Experimental design

The experimental animals were randomly bilaterally orchidectomized (Orx; n=24 animals) or sham-operated (SO; n=8 animals) under Ketamine anesthesia (15 mg/kg b.m.; Richter Pharma, Wels, Austria). The recovery period was two weeks. Orchidectomized rats were then divided into three subgroups of eight animals (n=8) each. The first group was subcutaneously (*s.c.*) treated with genistein (Nutraceutica, Monterenzio, Italy; Orx+G) in a dose of 30 mg/kg b.m. every day except on Sundays for 3 weeks. The second group *s.c.* received commercial soy extract (Orx+Soy), which contained 40% of isoflavones: genistein ($\geq 10\%$), daidzein ($\geq 15\%$), genistin ($\geq 3\%$), daidzin ($\geq 5\%$), glicitin ($\geq 1\%$), and glicitein ($\geq 0.5\%$), according to the manufacturer specifications (Nutraceutica, Monterenzio, Italy), in a dose of 30 mg/kg b.m., under the same regime as the previous group. The applied doses of genistein and soy extract were chosen following our previous protocol related to the orchidectomy model of andropause, that confirmed the beneficial effects of soy isoflavones (Ajdžanović et al., 2009a,b; Filipović et al., 2010). The injection strategy approximates oral consumption in terms of absorption rate (Jefferson et al., 2007). Genistein and soy extract were predissolved in a minimal volume of absolute ethanol (~0.1 ml) and mixed with sterile olive oil (~0.2 ml). The final volume injected was ~0.3 ml *per* animal. The third orchidectomized group (Orx) and the SO group were given the same volume (~0.3 ml) of vehicle (absolute ethanol + sterile olive oil, alone) and served as controls. There was no spontaneous death of the animals during the experiment. All the animals (n=32) were sacrificed by decapitation under ether anesthesia (*ether ad narcosis* Ph. Iug. III., Lek, Ljubljana, Slovenia) 24 h after the last injection. All experimental procedures complied with Directive 2010/63/EU on the protection of animals used for experimental and other scientific purposes and were approved by the Ethical Committee for the Use of Laboratory Animals of the Institute for Biological Research "Siniša Stanković", University of Belgrade.

Organ processing, histological procedures and light microscopy

With a view to exclude the potential toxic effects of used treatments at some elementary level, livers were excised, macroscopically observed and weighed. Also, the left adrenal glands were excised, stripped of fat and connective tissue, weighed (the relative weight of the adrenal to the body mass was also determined), fixed in

4% paraformaldehyde for 24 h, dehydrated in a series of increasing concentrations of ethanol (30%-100%), enlightened in xylol and embedded in paraplast. After embedding, adrenal glands were cut serially using a rotational microtome (RM 2125RT Leica Microsystems, Wetzlar, Germany) at 5 μm thickness and prepared for further quantitative and qualitative histological analyses. The adrenal sections for quantitative histological *i.e.* stereological analysis were stained with hematoxylin and eosin, while qualitative histological analysis required Masson's trichrome stain procedure, Novelli staining, as well as vascular endothelial growth factor (VEGF) or proliferating cell nuclear antigen (PCNA) immunostaining. After all the histological procedures, cover slips were mounted with DPX (Sigma-Aldrich, Co., USA).

Masson's trichrome staining, used in qualitative histology, is often a method of choice to distinguish cells from connective tissue, as well as to estimate the volume of connective tissue fibers. Commonly, it results in dark brown to black stained nuclei, red/reddish cytoplasm, muscle fibers and deposits, as well as blue appearance of collagen. In the initial steps, the procedure involved deparaffinization in xylol and rehydration (100%-70% ethanol, distilled water) of the adrenal sections, followed by incubation in Weigert's hematoxylin (5 min). After washing in tap water, the sections were incubated in a mixture of 1% acid fuchsine and 1% ponceau dextrilidene (1:2) for 5 min. The next step included multiple washing of adrenal sections in distilled water and their incubation in 0.05% phosphomolybdic acid (10 min). Finally, the sections were incubated in 2.5% aniline blue (3 min), washed several times in distilled water, dehydrated and mounted as previously described (Ajdžanović et al., 2017a).

Novelli histochemical staining was used to gain insight into the tissue vascular profile, and beside the deparaffinization in xylol and rehydration of adrenal sections involved incubation in hot 1N HCl (60°C, 3 min), 1% acid fuchsine (30 s) and 1% light green (30 s), respectively. The individual incubations were completed by washing in distilled water, then dehydration and mounting were processed. As a result, purple erythrocytes were clearly visible against the bright green background of the adrenal cortex (Ajdžanović et al., 2015, 2017a).

VEGF, which is a potent endothelial cell-specific angiogenic peptide, also expressed in kidney podocytes, epithelium of small bronchioles, choroid plexus epithelium, Purkinje cells, hepatocytes, adipocytes, cardiac and skeletal myocytes, Leydig cells, prostatic epithelium and salivary serous epithelium, was localized by immunohistochemistry (Maharaj et al., 2006; Šošić-Jurjević et al., 2016; Ajdžanović et al., 2017a). For immunohistochemical staining, 5 μm thick adrenal gland sections were deparaffinized in xylol and hydrated, followed by heat-induced antigen retrieval in a microwave on high power (750 W for 21 min in 0.01 M citrate buffer, pH 6.0). After washing with PBS, sections were incubated with 0.3% hydrogen peroxide in

methanol during 15 min at room temperature, to block endogenous peroxidase activity. Adrenal sections were then treated with normal swine serum (Dako Denmark A/S, Glostrup, Denmark) diluted in PBS (1:10) and incubated with rabbit polyclonal primary antibody to VEGF (1:100, abcam[®] ab46154, Lot No. GR247559-1; Cambridge, MA, USA) overnight in a humidified chamber at room temperature. It should be noted that the primary antibodies used are appropriate for immunocytochemistry/immunofluorescence, immunohistochemistry (frozen and paraffin sections) and Western blot, as validated by abcam[®], while the species reactivity includes mouse, rat and human. After rinsing in PBS, sections were incubated with polyclonal swine anti-rabbit immunoglobulins/HRP - an affinity-isolated, peroxidase-conjugated secondary antibody (Code No. P 0399, Lot No. 20011615; DAKO, Glostrup, Denmark) diluted in PBS (1:100) for 1 h at room temperature. Binding sites were visualized using 0.05% diaminobenzidine (DAB; Serva, Heidelberg, Germany), followed by counterstaining with hematoxylin and mounting in DPX (Sigma-Aldrich, Co., USA). Negative controls were obtained by replacing the primary antibody for PBS. For a positive tissue control we used the section of a rat thyroid gland.

The mouse monoclonal anti-PCNA antibody ((PC10) ab29 abcam[®]) is specific for proliferating cell nuclear antigen p36 protein that is expressed at high levels in proliferating cells. The primary antibody used is suitable for immunohistochemistry (frozen and paraffin sections), immunocytochemistry/immunofluorescence, flow cytometry and Western blot, as previously validated by abcam[®], while the species reactivity includes mouse, rat and human. After deparaffinization in xylol, hydration and antigen retrieval in a microwave (750 W for 21 min in 0.01M citrate buffer, pH 6.0), 5 μ m thick paraffin adrenal gland sections were washed with PBS and incubated with 0.3% hydrogen peroxide in methanol, during 15 min at room temperature, to block endogenous peroxidase activity. Then the sections were rinsed in 0.2M PBS and pre-incubated in normal donkey serum for 45 min (dilution 1:10, Dako, Glostrup, Denmark) to prevent nonspecific staining. Primary anti-PCNA antibody (dilution 1:10000 in PBS) was applied overnight at 4°C. After washing in PBS (pH 7.4) the secondary antibody polyclonal donkey anti-mouse (dilution 1:250 in PBS; Dako, Glostrup, Denmark) was applied for another 60 min, then rinsed again with PBS for 10 min. Antibody localization was visualized with 0.05% 3,3'-diaminobenzidine tetrahydrochloride (DAB) liquid substrate chromogen system (Dako, Glostrup, Denmark). Sections were thoroughly washed under running tap water, counterstained with hematoxylin and mounted with DPX.

Digital images of variously stained adrenal gland sections were taken using a LEITZ DM RB light microscope (Leica Mikroskopie & Systems GmbH,

Wetzlar, Germany), a LEICA DFC320 CCD camera (Leica Microsystems Ltd., Heerbrugg, Switzerland) and the Leica DFC Twain Software (Leica, Germany).

Quantification of cell proliferation

Proliferating cell nuclear antigen (PCNA) - positive cells were counted over the entire surface of adrenal sections, for each adrenocortical zone separately. Then the cells in each adrenocortical zone were counted and the number of PCNA positive cells, expressed *per* 1000 cells in the zona glomerulosa - ZG, zona fasciculata - ZF and zona reticularis - ZR of adrenal gland cortex, was calculated. This prevented biasing results with the heterogeneous PCNA distribution over the gland and the different cell volumes *per* zones. Counting was performed separately on the three central sections *per* animal, on four to five animals (individuals) for each group (SO, Orx, Orx+G and Orx+Soy). The average value of the number of PCNA positive cells was estimated *per* group and the values were expressed as means + standard deviation (SD).

Stereological analyses

All stereological analyses were carried out using a workstation comprising a microscope (Olympus BX-51, Olympus, Japan) equipped with a microcator (Heidenhain MT1201, Heidenhain, Traunreut, Germany) to control movement in the *z*-direction (0.2 μ m accuracy), a motorized stage (Prior Scientific Inc., Rockland, USA) for stepwise displacement in the *x*-*y* directions (1 μ m accuracy) and a CCD video camera (Pixelink Ottawa, ON, Canada) connected to a 19" PC LCD monitor (Dell 1907FPc, Dell Inc., Round Rock, TX, USA). The whole system was controlled by the newCAST stereological software package (VIS - Visiopharm Integrator System, version 2.12.1.0; Visiopharm; Denmark). The main objectives were planachromatic 10x dry lenses and a 100x oil lens. Control of stage movements and interactive test grids (uniformly spaced points test grids and a rectangular unbiased dissector frame) were provided by the newCAST software running on a Dell computer.

Volume estimation

The volumes of major adrenal gland structures (ZG, ZF, ZR, medulla (M) and blood vessels (BV)) as well as of the whole adrenal gland were estimated using Cavalieri's principle (Gundersen and Jensen, 1987; Ajdžanović et al., 2017a). The Cavalieri principle is an unbiased way of estimating the volume of an object, obtained by dividing the object into a series of parallel planes with known distances between them. The total volume of an object is estimated by summing up the areas across all sections and multiplying the results by section thickness. In order to ensure a random position

Andropausal adrenals after isoflavones

for the first section, a random number table was used. From the first selected section, every 20th section was analyzed to enable systematic uniform random sampling. On the PC monitor, final magnification of 182.5x allowed easy and accurate recognition of tissue boundaries. Mean section thickness was estimated using the block advance (BA) method (Dorph-Petersen et al., 2001), and we found that there was no variation from 5 μm , as set in the microtome, *i.e.* there were no differences between nominal and true section thickness.

The volumes of adrenal gland compartments (ZG, ZF, ZR, M, and BV) were calculated by the formula:

$$\bar{V} = a(p) \cdot \bar{d} \cdot \sum_{i=1}^n P_i$$

where $a(p)$ is the area associated to each sampling point, \bar{d} is the mean distance between two consecutively studied sections (100 μm), n is the number of sections studied for each adrenal gland and $\sum P_i$ is the sum of points hitting a given target. To ensure that 100-200 points were hitting the phase of interest, three test grids with different point densities were used. Therefore, $a(p)$ for ZG and M was 371 338.70 μm^2 , $a(p)$ for ZF and ZR was 208 878.02 μm^2 , while for BV and CP $a(p)$ was 52 219.50 μm^2 . Then the volume of the adrenal gland cortex was calculated by summing appropriate adrenal gland components.

Volumes of the individual cells of ZG, ZF and ZR as well as their respective nuclei volumes were estimated using a planar rotator as an unbiased local estimator (Jensen and Gundersen, 1993; Ajdžanović et al., 2017a), and 150-200 of cells with nuclei were measured *per* animal (objective magnification at 100x). Primarily, the position in the center of the nucleus of the measured cell was marked. From this point, a line was drawn across the apparently shortest diameter of the cell, and the two points where the projection of the widest points of the structure, *i.e.* cell membrane intersected the first line were marked. By marking the intersections between the half lines and the cell membrane or cell nuclei as the boundaries of the structure, the computer generates a volume estimate from the formula:

$$V = \sum l_i^2 \cdot t \cdot \frac{\pi}{2}$$

where t represents distance between the half lines (test lines) and l_i is individual distance between the intersections of half lines with the cell boundary and the first line.

Biochemical analyses

Blood was collected from the trunk, and separated sera/plasma samples of all the animals were stored at the same time at -70°C until assayed.

Concentrations of total cholesterol, triglycerides,

HDL and LDL in serum were determined by the corresponding enzymatic colorimetric assays, according to the manufacturer's instructions on Roche/Hitachi cobas c system (Roche Diagnostics, Basel, Switzerland). All samples were tested in duplicate within a single assay, with an intra-assay coefficient of variation (CV) for total cholesterol of 1.4%, for triglycerides of 1.6%, HDL-cholesterol of 0.9% and LDL-cholesterol of 1.9%.

Plasma ACTH concentration was determined without dilution, by a chemiluminescence method using an IMMULITE automatic analyzer (DPC, Los Angeles, CA, USA), in duplicate samples within a single assay, with an intra-assay CV of 9.6%. The analytical sensitivity of this assay is 9 pg/ml. Serum testosterone concentrations were determined without dilution, using a competitive immunoenzymatic colorimetric method (EIAgen Testosterone Kit, Adaltis Italia S.p.A., Bologna, Italy), in duplicate samples within a single assay, with an intra-assay CV of 6.2%. Serum aldosterone concentrations were determined by enzyme immunoassay for direct quantitative determination (Aldosterone ELISA, IBL Hamburg, Germany), in duplicate samples within a single assay, with an intra-assay CV of 4.1% (128.67 pg/ml). Serum corticosterone concentrations were measured without dilution by immunoassay (R&D Systems Inc., Minneapolis, USA), in duplicate within single assays, with an intra-assay CV of 8.0% (171 pg/ml). Serum DHEA concentrations were determined by enzyme immunoassay for quantitative determination (DHEA ELISA, IBL Hamburg, Germany), in duplicate samples within a single assay, with an intra-assay CV of 6.92%.

Adrenal tissue corticosterone assay

The right adrenal glands were excised, stripped of fat and connective tissue, weighed and immediately shredded on ice. Shredded tissue was then homogenized in TRIS-saccharose buffer (pH 7.9; 1 mg of tissue : 1 μl of buffer) using a dispersion system (Ultra - Turax T25, Janke & Kunkel, IKA-Labortechnik, Staufen, Germany) at 8000 rpm. The homogenate was centrifuged at 35000 rpm (105000 g) for 1 h (BECKMAN ultracentrifuge, L7-55) and corticosterone concentration in the supernatant was determined by immunoassay (R&D Systems Inc., Minneapolis, USA) (Ajdžanović et al., 2009b, 2015, 2016).

Statistical analysis

STATISTICA[®] version 7.0 (StatSoft, Inc) was used for the statistical analysis. Stereological and biochemical data obtained for the experimental groups were subjected to one-way analyses of variance (ANOVA). Duncan's multiple range tests were used for *post hoc* comparisons between the groups. A confidence level of $P < 0.05$ was considered statistically significant. All data are presented as means \pm SD.

Results

Body mass, adrenal gland and liver weights

Body mass and organ weight data appear in Table 1. Body mass and the relative adrenal weight were significantly altered after orchidectomy compared to the SO group. Significant ($P<0.05$) changes occurred in body mass, relative adrenal gland and absolute liver weights of the Orx+G group and the relative adrenal gland weight in Orx+Soy group, all in relation to SO rats, were observed (Table 1). The macroscopic examination of organs did not reveal superficial pathologies in the livers of any rats.

Histological analysis of the adrenal gland

The adrenal cortex is composed of three concentric zones where, beneath the capsule, ovoid cells with single round nuclei, and a small amount of homogeneously stained cytoplasm with a few lipid droplets comprising the zona glomerulosa (ZG) are arranged in typical spherical structures. Beneath the ZG are long, radially arranged cords of zona fasciculata (ZF) cells, that are larger than in the other zones, with large, numerous lipid droplets. The innermost zona of the cortex, zona reticularis (ZR), is characterized by the disruption of the regular, parallel alignment of the ZF cords and the formation of an anastomosing network made of cells that

are smaller than those in ZF, and contain relatively few small lipid droplets (Fig. 1).

After Novelli and Masson trichrome staining, a network of blood vessels with blue violet erythrocytes and blue collagen fibers become clearly visible and reveal that orchidectomy increased the presence of capillaries and blood vessels mostly in ZG vs. the SO group. After treatment of orchidectomized animals with genistein (Orx+G) and soy extract (Orx+Soy) the appearance of an extensive vascular network is mainly seen in the outer region of the cortex. Qualitative analysis revealed that in the ZR the presence of the blood vessels is more pronounced than in SO and Orx groups (Fig. 1b,c).

The immunohistochemical analysis of VEGF immunopositive cells showed them to be mainly observed in the adrenal cortex and medulla. The specific staining for VEGF in cells of all adrenocortical zones was cytoplasmic, making the presence of lipid droplets more apparent. In SO group the most intense immunopositivity was observed in the ZG where cytoplasmic immunostaining was present in all cells. Orchidectomy significantly increased VEGF protein abundance in the cortical cells and in the wall of capillaries; the most intense staining was present in the ZG cells, while a smaller number of cells in ZF and ZR did not stain uniformly. A few cells of inner zones showed intense cytoplasmic immunopositivity and other cells were moderately stained. Increased accumulation

Table 1. Body mass, absolute and relative adrenal gland and liver weights of control and soy isoflavone treated rats.

Group	Body mass (g)	Absolute adrenal gland weight (mg)	Relative adrenal gland weight (mg%)	Absolute liver weight (g)	Relative liver weight (g%)
SO	397.1±26.1	26.3±5.7	6.6±1.1	15.6±0.5	3.9±0.2
Orx	335.8±28.7 ^a a (-15.4%)	29.2±4.6	8.6±0.7 ^a a (+30.3%)	14.2±4.3	3.8±0.2
Orx+G	324.3±55.3 ^a a (-18.3%)	31.1±4.9	9.7±1.5 ^a a (+47.0%)	11.5±2.2 ^a a (-26.3%)	3.5±0.3
Orx+Soy	353.6±37.7	30.0±2.1	9.2±1.3 ^a a (+39.4%)	12.8±1.6	3.7±0.3

SO (sham operated), Orx (orchidectomized), Orx+G (orchidectomized and genistein treated), Orx+Soy (orchidectomized and soy extract treated) group of adult male rats. All values are the means ± SD, n=8 animals *per* group. ^a $P<0.05$ vs. SO; ^b $P<0.05$ vs. Orx.

Table 2. Number of proliferating cell nuclear antigen (PCNA) positive cells expressed *per* 1000 cells in zona glomerulosa (ZG), zona fasciculata (ZF) and zona reticularis (ZR) of adrenal gland cortex in the SO (sham operated), Orx (orchidectomized), Orx+G (orchidectomized and genistein treated), Orx+Soy (orchidectomized and soy extract treated) group of adult male rats.

Group	ZG	ZF	ZR
SO	28.4±1.4	7.2±1.5	8.7±0.8
Orx	34.3±1.9 ^a a (+20.8%)	9.8±1.5 ^a a (+36.1%)	11.7±1.9 ^a a (+30.9%)
Orx+G	37.3±1.9 ^{a,b} a (+31.3%) b (+8.7%)	11.5±0.8 ^a a (+59.7%) b (+17.3%)	14.3±0.8 ^{a,b} a (+57.7%) b (+20.5%)
Orx+Soy	30.8±1.8	8.5±1.4	9.8±0.7

All values are the means ± SD, n=5 animals *per* group. ^a $P<0.05$ vs. SO; ^b $P<0.05$ vs. Orx.

Andropausal adrenals after isoflavones

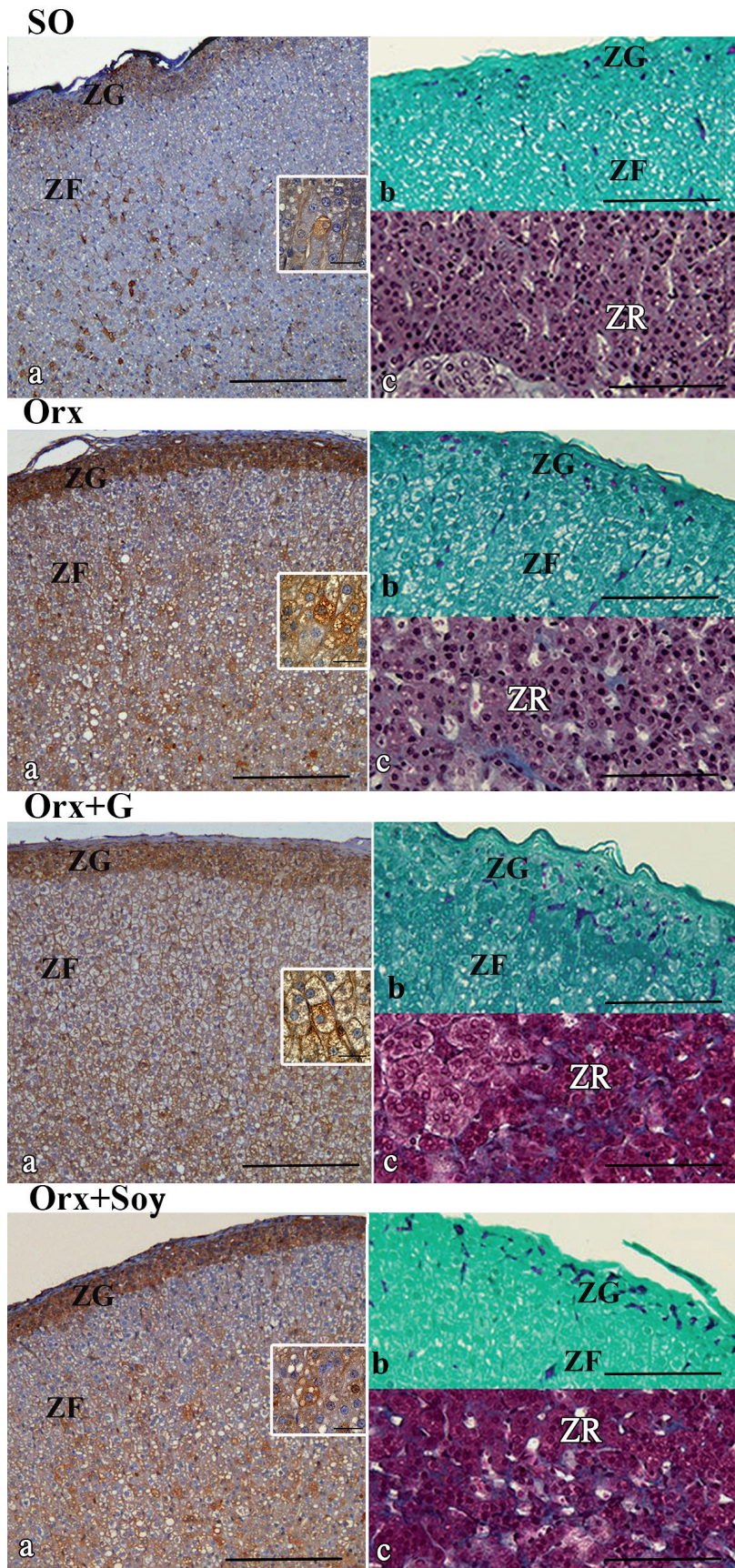


Fig. 1. Representative micrographs of VEGF immunohistochemical (a), Novelli (b) and Masson trichrome (c) histological staining of adrenal sections from the: SO (sham operated), Orx (orchidectomized), Orx+G (orchidectomized and genistein treated), Orx+Soy (orchidectomized and soy extract treated) group of adult male rats; insets of VEGF stained zona fasciculata. ZG (zona glomerulosa), ZF (zona fasciculata), ZR (zona reticularis). Scale bars: a, 200 μm ; b, c, 100 μm ; insets, 50 μm .

of lipid droplets, in parallel with VEGF synthesis and secretion within cortical cells and capillary walls, in all zones was seen in Orx+G group. In Orx+Soy group the predominant staining for VEGF was found in the ZG, with weaker staining in inner cortical zones, all relative

to the Orx and SO group (Fig. 1a).

The highest presence of the proliferative marker, PCNA, was detected as nuclear staining in the cells of outer portion of the adrenal cortex, and its intensity varied among cells. PCNA positive cells were numerous

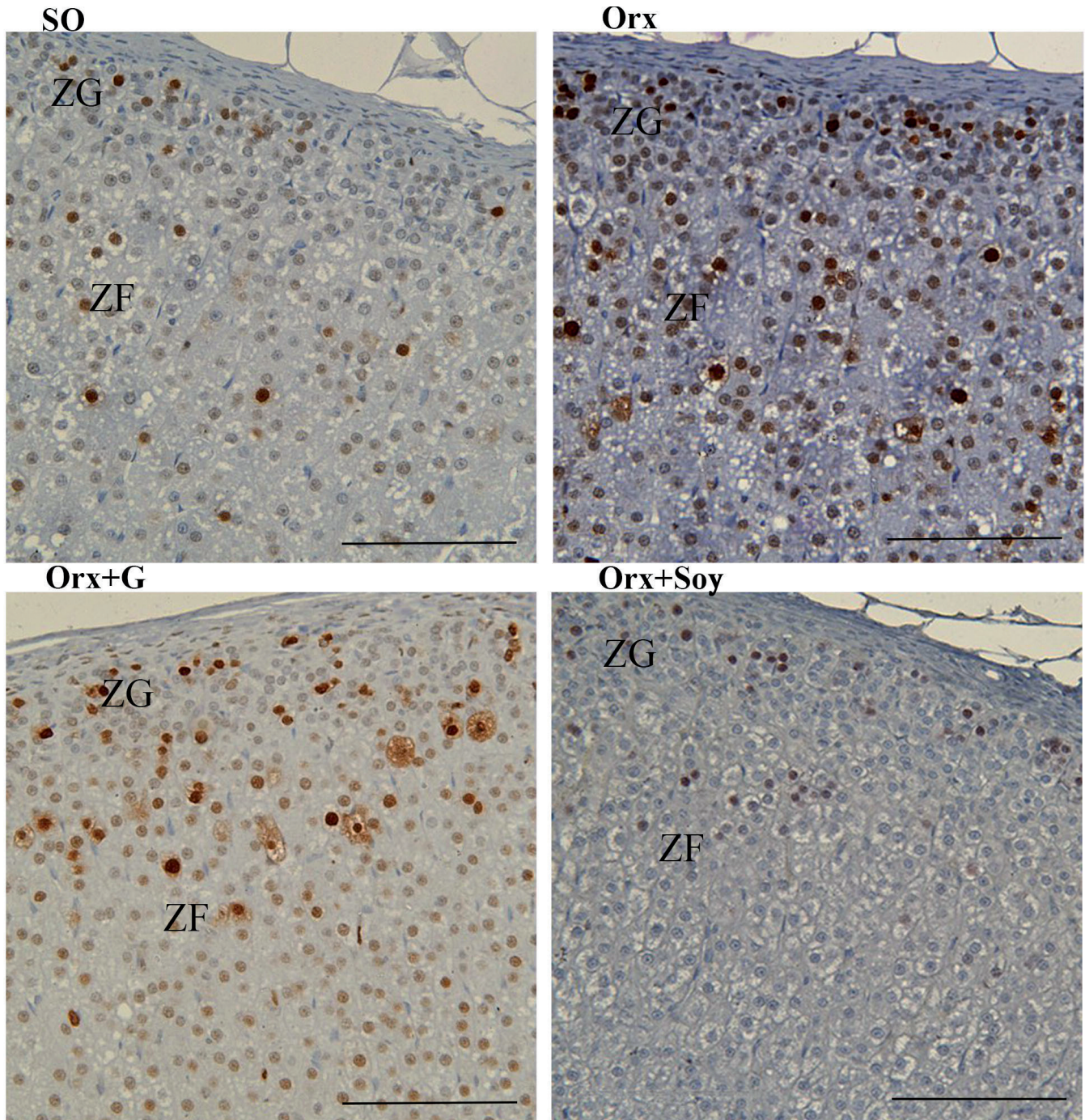


Fig- 2. Proliferating cell nuclear antigen (PCNA) immunohistochemical staining of the zona glomerulosa (ZG) and zona fasciculata (ZF) in the: SO (sham operated), Orx (orchidectomized), Orx+G (orchidectomized and genistein treated) and Orx+Soy (orchidectomized and soy extract treated) group of adult male rats. Scale bars: 100 μ m.

Andropausal adrenals after isoflavones

in ZG and the narrow portion of the ZF, while less labeled cells were found in the inner portion of the ZF and ZR (Fig. 2). Compared to the SO group there was a marked increase in the number of PCNA labeled cells after orchidectomy and subsequent genistein treatment (Fig. 2), while in the Orx+Soy group the number of marked cells was similar to control levels (Fig. 2).

PCNA labeled cell nuclei were generally positioned in the bordering zone between ZR and medulla, located in steroidogenic and chromaffin cells, as well. In relation to SO rats, increased number of PCNA positive cells became evident in Orx and Orx+G group, while in the Orx+Soy group changes in the number of labeled cells were not noticeable (Fig. 3). The highest number of replicating cells expressed *per* 1000 cells in the ZG actually reflects the lower total number of cells in that zone in relation to ZF. The similar number of PCNA positive cells in ZF and ZR reflects the lower total number of cells in ZR compared to ZF.

Quantification of PCNA positive cells expressed *per* 1000 cells *per* zone further confirmed the histological observations that most of the labeled cells are positioned in ZG in all examined groups. Orchidectomy led to a significant ($P<0.05$) increase in the number of labeled cells in ZG, ZF and ZR of the cortex in comparison with SO group. In relation to Orx group, subsequent genistein application to orchidectomized rats further increased ($P<0.05$) the number of PCNA labeled cells in ZG, ZF and ZR. When comparing Orx+G and SO group, the number of PCNA positive cells was markedly increased

in all cortical zones ($P<0.05$, Table 2).

Stereological parameters of the adrenal gland

Orchidectomy significantly ($P<0.05$) increased adrenal cortex volume, as well as the ZG volume by 28.1% and 62.3% respectively, compared to the SO group (Fig. 4a,d). In Orx+G rats a significant ($P<0.05$) increase of adrenal cortex volume by 33.4% occurred compared to the Orx group due to increased ($P<0.05$) ZF volume (22.0%) (Fig. 4a,d). The volume of the adrenal medulla and the volume of total vascular tissue (whole gland) was unchanged compared with the Orx group (Fig. 4b,c). Comparison of Orx+G and SO groups revealed a significant increase ($P<0.05$) of all cortical zones (93.8%, 49.9% and 125.5% respectively), and consequently of the entire adrenal cortex and adrenal medulla volumes by 70.9% and 47.5% ($P<0.05$) respectively (Fig. 4a,b,d). The volume of vascular tissue was notably ($P<0.05$) increased in Orx+G and Orx+Soy group by 120.0% and 58.8%, all relative to SO animals (Fig. 4c).

In comparison with the SO group cell volume was significantly increased ($P<0.05$) in the ZF of the Orx+G and Orx+Soy groups by 10.3% and 8.6% respectively (Fig. 5a). The volume of the cell nuclei of ZG and ZF in the Orx group, as well as the ZF cell nuclei volume in Orx+G and Orx+Soy groups were higher ($P<0.05$) by 9.7%, 10.8%, 7.2% and 3.6% respectively, when compared to the corresponding values in the SO group (Fig. 5b).

Table 3. Serum lipid data.

Group	Total cholesterol	Triglycerides	HDL	LDL	non HDL
SO	1.89±0.02	1.96±0.02	1.08±0.17	0.48±0.01	0.91±0.12
Orx	2.17±0.04	1.15±0.04 ^a a (-41.3%)	1.26±0.20	0.57±0.06	0.83±0.09
Orx+G	2.03±0.20	1.40±0.70	1.26±0.13	0.49±0.11	0.80±0.20
Orx+Soy	2.30±0.10 ^a a (+21.7%)	1.59±0.50	1.28±0.20	0.57±0.14	0.98±0.30

SO (sham operated), Orx (orchidectomized), Orx+G (orchidectomized and genistein treated), Orx+Soy (orchidectomized and soy extract treated) group of adult male rats. All values are the means ± SD, n=8 animals *per* group. ^a $P<0.05$ vs. SO.

Table 4. Hormonal data.

Group	Plasma level of ACTH (ng/L)	Serum level of aldosterone (ng/mL)	Serum level of corticosterone (ng/mL)	Tissue level of corticosterone (ng/mg)	Serum level of DHEA (ng/mL)	Serum level of testosterone (ng/mL)
SO	37.3±2.2	141.6±30.9	14.2±3.3	1.7±0.5	0.71±0.08	1.570±0.050
Orx	58.6±2.6 ^a a (+57.0%)	367.0±77.8 ^a a (+2.6x)	16.3±3.9	1.6±0.3	1.42±0.31 ^a a (+2.0x)	0.034±0.010 ^a a (-46.1x)
Orx+G	85.6±9.0 ^{a,b} a (+2.3x) b (+46.1%)	412.4±37.7 ^a a (+2.9x)	30.1±6.1 ^{a,b} a (+2.1x) b (+84.7%)	3.8±0.5 ^{a,b} a (+2.2x) b (+2.4x)	0.83±0.08 ^b b (-41.5%)	0.138±0.070 ^{a,b} a (-11.0x) b (+4.1x)
Orx+Soy	74.4±6.2 ^{a,b} a (+99.5%) b (+26.9%)	390.2±46.8 ^a a (+2.7x)	25.5±2.9 ^{a,b} a (+79.6%) b (+56.4%)	1.5±0.3	0.49±0.04 ^b b (-65.6%)	0.016±0.008 ^a a (-98.0x) b (-2.1x)

SO (sham operated), Orx (orchidectomized), Orx+G (orchidectomized and genistein treated), Orx+Soy (orchidectomized and soy extract treated) group of adult male rats. All values are the means ± SD, n=8 animals *per* group. ^a $P<0.05$ vs. SO; ^b $P<0.05$ vs. Orx.

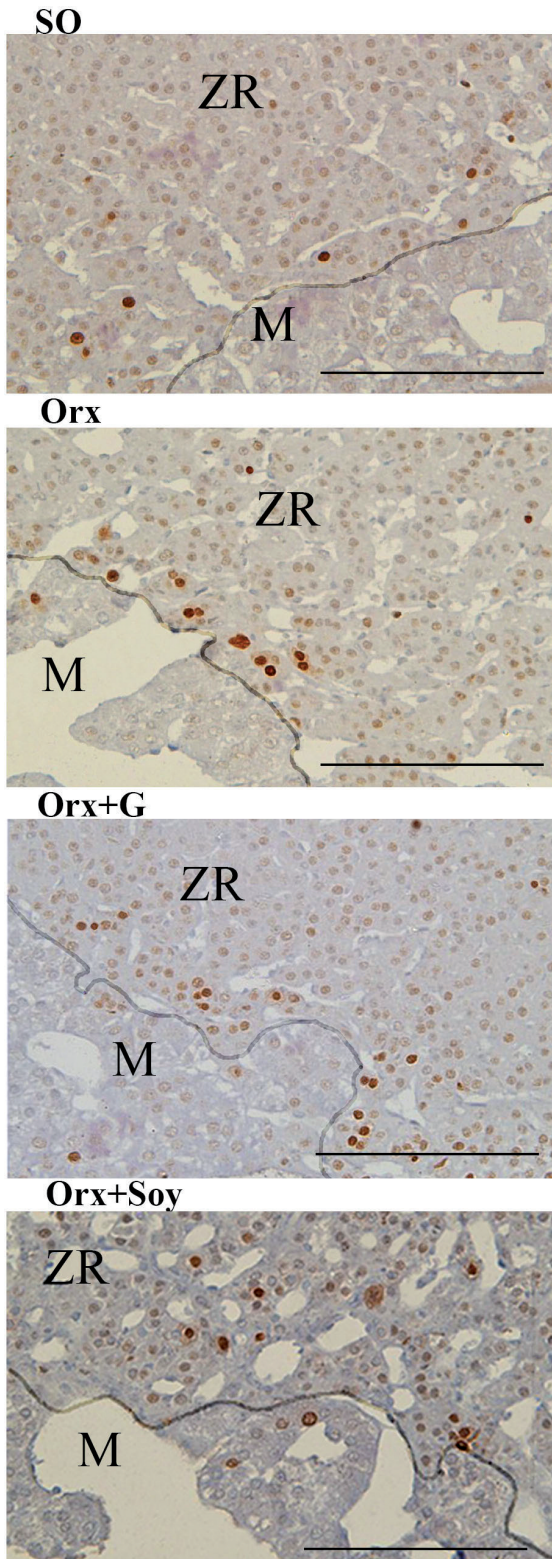


Fig 3. Proliferating cell nuclear antigen (PCNA) immunohistochemical staining of the zona reticularis (ZR) in the: SO (sham operated), Orx (orchidectomized), Orx+G (orchidectomized and genistein treated) and Orx+Soy (orchidectomized and soy extract) treated group of adult male rats. Boundary of the medulla and ZR is delineated; ZR (zona reticularis), M (medulla). Scale bars: 100 μ m.

Serum lipid data

The triglyceride concentration in serum decreased ($P < 0.05$) by 41.3% following orchidectomy compared to the SO group. Treatment of orchidectomized rats with genistein or soy extract did not significantly ($P > 0.05$) affect serum concentrations of total cholesterol, HDL, LDL and nonHDL (Table 3).

Hormonal data

After orchidectomy plasma level of ACTH, as well as serum levels of aldosterone and DHEA were significantly ($P < 0.05$) increased by 57.0%, 2.6 and 2.0 fold respectively, all compared with SO rat. A large decrease ($P < 0.05$) in testosterone levels by 46.1 fold also occurred in the same group. The circulating levels of ACTH and corticosterone as well as the adrenal tissue level of corticosterone continued to increase after treatment of orchidectomized rats with genistein by 46.1%, 84.7% and 2.4 fold respectively, while the level of DHEA was markedly lower (41.5%), all in comparison with the Orx group of animals. Additionally, genistein application to orchidectomized animals increased ($P < 0.05$) the testosterone level in relation to Orx group by 4.1 fold. In the Orx+Soy group, ACTH and circulating corticosterone levels were significantly ($P < 0.05$) increased by 26.9% and 56.4%, whereas the DHEA level was significantly ($P < 0.05$) reduced by 65.6%, all in relation to Orx group (Table 4).

In the Orx+G group the circulating levels of ACTH, aldosterone, corticosterone, as well as the adrenal tissue level of corticosterone, were higher ($P < 0.05$) by 2.3 fold, 2.9 fold, 2.1 and 2.2 fold respectively, while the testosterone level was lower by 11.0 fold, all relative to the corresponding values in the SO group. After soy extract application to orchidectomized rats, a significant ($P < 0.05$) increase of ACTH, aldosterone and corticosterone levels was observed (99.5%, 2.7 fold and 79.6% respectively), as well as a marked ($P < 0.05$) decrease of testosterone levels (98.0 fold), all relative to the SO animals (Table 2).

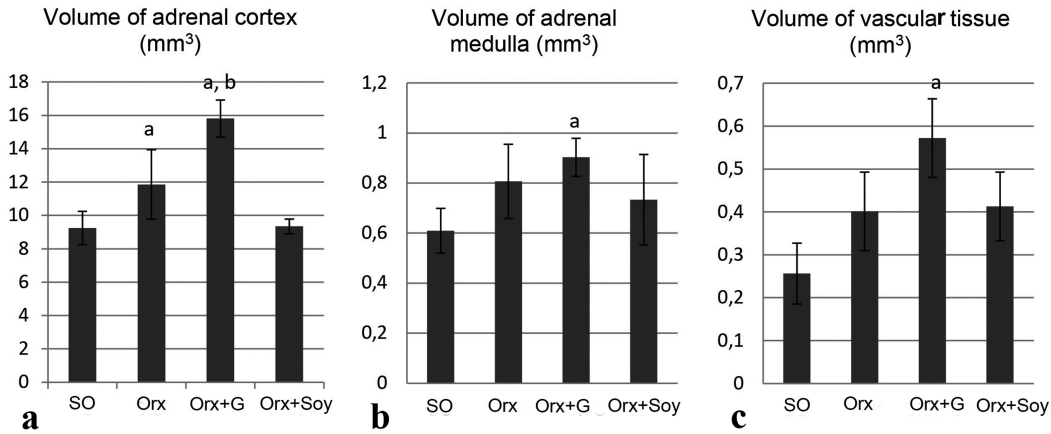
Discussion

In the present study we investigated the histological and steroid hormone-secreting changes of the adrenal gland after administering therapeutically relevant doses of the soy isoflavone, genistein, or the commercial soy extract, to orchidectomized adult rats. This regimen was given for 21 days and, therefore, suggests that a stable physiological and biochemical equilibrium was established. This animal model of androgen deficiency allows examination of the potentially anti-ageing effects of these steroid-like substances on the endocrine events occurring after removal of interfering endogenous sex steroids in a hormonal milieu deprived of endogenous sex steroids (Ajdžanović et al., 2009a,b, 2011, 2015, 2016; Trifunović et al., 2012, 2014). Histological

Andropausal adrenals after isoflavones

procedures, along with design-based stereology, a modern tool of quantitative histology, combined with hormone assays were among the methods employed. Considering the absence of pathological changes in liver weights and normal liver-related macroscopic findings (without superficial anomalies) after soy isoflavones, we conclude the supplementation protocol was essentially

safe at a dose of 30 mg/kg b.m. (Ajđžanović et al., 2009a,b, 2011, 2012, 2014; Filipović et al., 2010; Trifunović et al., 2012, 2014). It should be also noted that the soy isoflavones did not significantly change total circulating cholesterol; thus, the pool of the main precursor for steroid hormone biosynthesis was unaffected after treatment.

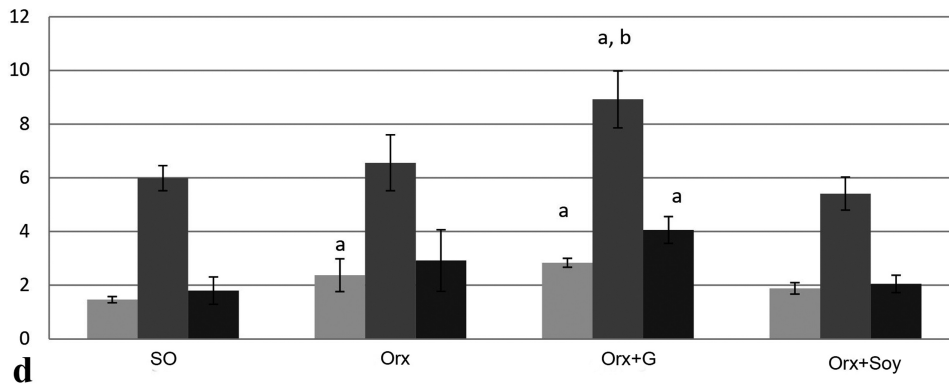


a

b

c

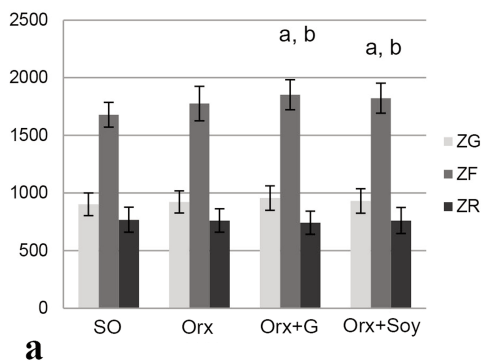
Volume of the cortex zones (mm³)



d

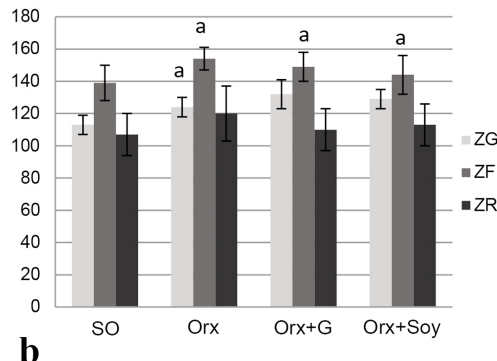
Fig. 4. Volume of the adrenal gland a) cortex (mm³), b) medulla (mm³), c) vascular tissue (mm³) and d) adrenocortical zones (mm³) - zona glomerulosa (ZG), zona fasciculata (ZF) and zona reticularis (ZR) in: SO (sham operated), Orx (orchidectomized), Orx+G (orchidectomized and genistein treated), Orx+Soy (orchidectomized and soy extract) treated group of adult male rats. All values are the means ± SD, n=5 animals per group. ^aP<0.05 vs. SO; ^bP<0.05 vs. Orx.

Adrenal cortex cell volume (μm³)



a

Adrenal cortex cell nuclei volume (μm³)



b

Fig. 5. The volume of adrenocortical a) cells (μm³) and b) their nuclei (μm³) in: SO (sham operated), Orx (orchidectomized), Orx+G (orchidectomized and genistein treated), Orx+Soy (orchidectomized and soy extract) treated group of adult male rats. ZG (zona glomerulosa), ZF (zona fasciculata), ZR (zona reticularis). All values are the means ± SD, n=5 animals per group. ^aP<0.05 vs. SO; ^bP<0.05 vs. Orx.

Orchidectomy profoundly affects the maintenance of adrenal weight and function. The removal of circulating testosterone eliminates its inhibitory effects resulting in an increase of adrenal weight and marked increase of cortical volume. Given that testosterone acts on a multitude of brain regions including the hippocampus, amygdala, and several hypothalamic nuclei that control HPA function, its removal after orchidectomy strongly enhances circulating ACTH as well as structural and functional characteristics of adrenal gland as its target organ (Malendowicz, 1974; Williamson et al., 2005). The increase in relative adrenal weight was a consequence of the intense impact of orchidectomy on reducing body mass relative to the adrenal gland itself. Orchidectomized adult rats display decreased body mass compared to sham operated controls, which agrees with our previous results in orchidectomized middle-aged animals (Ajdžanović et al., 2009a,b), and may reflect skeletal muscle atrophy induced by testosterone deficiency (Antonio et al., 1999). In contrast to orchidectomized middle-aged rats where there were no changes in triglycerides (Šošić-Jurjević et al., 2007), this parameter significantly decreased after orchidectomy in the present study. This is in accord with the data of Ginci and coworkers (1997), who found a decrease of triglycerides in very-low-density lipoproteins (VLDL), in five-week old castrated rats. This suggests an age-dependent effect of orchidectomy on this parameter.

Increased volume of the ZG and ZG cell nuclei, as a consequence of enhanced number of PCNA positive cells (*i.e.* replicating cells) following orchidectomy and subsequent genistein treatment occurred along with enhanced aldosterone circulating levels. Angiotensin II, both systemic as well as *via* an intra-adrenal renin-angiotensin system, is a major factor that regulates, modulates and maintains the ZG cell number and size *via* angiotensin receptor type 1 (Mitani et al., 2003; Vinson, 2003). The increased aldosterone in Orx and Orx+G groups could be an indication of increased angiotensin II that promotes proliferative activity of the ZG cells, reflected as an increased number of PCNA positive cells. This is supported as it is known that ZG cell proliferation increases along with increased aldosterone secretion in response to a low-sodium diet (McEwan et al., 1996). In the present work the ZG and the peripheral region of the ZF were sites with the most intense mitotic activity, and these regions of replicating cells were described as the regions responsible for adrenocortical cytotgenesis (Miyamoto et al., 1999; Mitani, 2014).

Circulation infrastructure is another consideration that significantly affects functionality of the adrenal gland after orchidectomy and genistein exposure, especially since it is an extensively vascularized organ. VEGF is a growth factor with angiogenic, mitotic and antiapoptotic effects and is predominantly synthesized in steroidogenic cells (LeCouter et al., 2001). In the adrenal gland the principal site of VEGF synthesis is the ZG in all groups. This is where the primary branching and

formation of fenestrated capillary networks arise. Histochemistry and VEGF immunohistochemistry show a positive relationship between capillary network appearance and aldosterone concentration in Orx and Orx+G rats due to efficient oxygenation and rapid exchange of nutrients and waste products. In these groups, the impact of elevated ACTH levels on aldosterone increases seem evident because these findings are opposite to those in middle-aged rats, where the aldosterone levels were significantly lower under the same experimental conditions. This may be a consequence of age-related attenuations in ACTH induced increases in plasma aldosterone or of feedback activation (Ait-Chaoui et al., 1995; Ajdžanović et al., 2009a,b). Additionally, genistein caused direct inhibition of the SRC family of tyrosine kinases and the 3 β HSD enzyme in the adrenal cortex (Ajdžanović et al., 2009b). Different mechanisms that involve genistein appear to operate in orchidectomized rats of various ages.

In the Orx+Soy group, the lack of ZG stereological and hormonal changes (*i.e.*, aldosterone levels, zonal cell volumes and proliferation rates) most likely is explained by increased amounts of glycosylated isoflavones in soy extracts (genistin, daidzin and glycitin), with less biological action and lower genistein content.

Deprived of gonadal steroids, the altered baseline hormonal status of adult rats receiving genistein treatment (the most abundant soybean isoflavone) exerted a positive influence on ZF cell proliferation and vascularization due to increased ACTH level as observed herein and in earlier research (Trifunović et al., 2012). Also, there was a pronounced stimulation of the size of the adrenal cortex, especially in the ZF. Overall, this resulted in significantly elevated tissue and circulating corticosterone levels. While orchidectomized middle-aged rats exhibited decreased ACTH and corticosterone production/secretion after genistein treatment when the brain (hippocampal, hypothalamic and limbic) regulation of adrenocortical function was likely diminished (Ajdžanović et al., 2009a,b), in orchidectomized rats of younger age, subjected to the same treatment, the ZF stimulation was assessed. Specifically, genistein in orchidectomized middle-aged rats reduced the level of ACTH through inhibition of tyrosine kinase phosphorylation cascades in ACTH cells and inhibited 3 β HSD enzymes resulting in low corticosterone output (Ajdžanović et al., 2009a,b). Normal brain influence on adrenocortical function in the adult rats in this study suggests that genistein targets, which affect ZF stimulation, may be within the hypothalamic regulatory regions.

Enhanced CRH/cFos in Orx+G rats indicates elevated activity of CRH neurons (Trifunović et al., 2012). The estrogen receptors (ERs) in parvocellular and magnocellular hypothalamic regions (ER β in the CRH neurons) represent the most probable targets of genistein action (LaFlamme et al., 1998; Shughrue and Merchenthaler, 2001; Cho et al., 2007; Trifunović et al., 2012). The consistent genistein-induced hypothalamic

stimulation increased total number of ACTH cells and the circulating ACTH concentration (Trifunović et al., 2012), resulting in an overall stimulation of the ZF. The positive effect on VEGF expression and endothelial cell mitosis and fenestration on the adrenal vascular network, and the stimulation of ZF steroidogenesis by ACTH resulted in elevated tissue and circulating corticosterone level (Gaillard et al., 2000; Thomas et al., 2003). Thus, the age-related difference in genistein effects is also present with regard to regulation of glucocorticoid production and secretion.

The clear increase of ACTH levels in the Orx and Orx+G groups has an essential influence on the ZF/and ZR proliferation rate, so adrenal growth and steroidogenesis are coordinated and the gland is prepared to react promptly (Ulrich-Liau et al., 2006). PCNA, as a marker of replicating cells that provides insight into the cellular dynamics underlying the responsiveness of the adrenal cortex to stimuli, revealed a marked increase of proliferative activity after orchidectomy in outer portion of the adrenal cortex and further rise under genistein influence. A prominent rise in ACTH plasma levels preceded the maximum adrenocortical cell proliferation thereby controlling circadian proliferative variations of the ZF cells (Miyamoto et al., 1999). Additionally, FGF and IGF-1, synthesized under the ACTH stimulation, cause ZF cells to respond in a paracrine manner (Wolkersdörfer and Bornstein, 1998; Hoeflich and Bielohuby, 2009). The influence of other small biologically active peptides generated locally, by the enzymatic cleavage of pituitary proopiomelanocortin (POMC), potentially stimulated adrenal cell proliferation (Hoeflich and Bielohuby, 2009). Moreover, mice lacking the POMC-derived peptides (POMC^{-/-} mutant mice) show signs of adrenal insufficiency (Yaswen et al., 1999).

The effects of soy extract application to orchidectomized rats included a marked rise of ACTH concentration, (although less marked compared to the genistein effect) and consequently increased blood corticosterone levels without disrupting the structural integrity of the gland, as the volume of cortical zones and the adrenocortical cell mitotic activity were unchanged. The stimulatory effect of soy extract on the population of pituitary ACTH cells in orchidectomized adult rats was already reported (Trifunović et al., 2014). A positive relationship was observed between ACTH levels after soy application and VEGF expression, strongly indicating increased adrenal blood flow velocity and drainage that further supports a significant increase in corticosterone synthesis and output. Soy isoflavones, in an environment free of testicular hormones, are able to overcome the adrenocortical cell proliferative changes. Indeed, it was shown that soy isoflavones have potential to inhibit prostate carcinogenesis by modulating the cell cycle (cell survival and cell death), and influence the activity of tyrosine kinase enzymes and/or androgen receptor (AR) expression (Mahmoud et al., 2014).

In the Orx group, serum DHEA levels rose and either genistein or soy extract decreased DHEA levels relative to the Orx rats. Furthermore, genistein significantly increased ZR volume when compared to the SO animals. Considering the relationship between corticosterone and DHEA, products of the inner cortical region, the pool of cholesterol precursors was likely directed toward corticosterone production resulting from a strong trophic ACTH influence rather than being shifted to adrenal androgen synthesis.

The presence of replicating cells in the ZR in all examined groups is shown although it is often considered as a place where the cells have been eliminated by apoptosis (Wolkersdörfer and Bornstein, 1998). Determined increase of proliferation rate *i.e.* PCNA positive cells in this region after orchidectomy and further enhanced after genistein application, correlates with increased cortex volume, presumably due to preserved structural stability of the gland. Taken together zonal theory, that implies zone specific cell proliferation and apoptotic cell death may explain the results (Swann, 1940; Wolkersdörfer and Bornstein, 1998).

In conclusion, the Orx animal model used herein showed stimulation of the adrenal gland along with corticosterone increases as well as inhibition of DHEA production after treatment with therapeutically relevant doses, over a 3 week interval, of the soy isoflavone genistein or a commercial soy extract. Genistein also produced certain structural changes. Middle-aged orchidectomized rats were previously shown to display opposite reactions to genistein administration, likely due to decreased central control by the HPA axis. We conclude that soy isoflavone influences on male aging must be considered in the context of the androgenic status of subjects to ensure the safe usage of this potential therapeutic modality.

Acknowledgements. This work was supported by the Ministry of Science, Education and Technological Development of the Republic of Serbia, Grant number 173009. The authors Verica Milošević and Vladimir Ajdžanović are participating to the COST Action FA 1403 POSITIVE (Interindividual variation in response to consumption of plant food bioactives and determinants involved), supported by COST (European Cooperation in Science and Technology).

References

- Ait-Chaoui A., Rakotondrazafy J. and Brudieux R. (1995). Age-related changes in plasma corticosterone and aldosterone responses to exogenous ACTH in the rat. *Horm. Res.* 43, 181-187.
- Ajdžanović V., Šošić-Jurjević B., Filipović B., Trifunović S., Brkić D., Sekulić M. and Milošević V. (2009a). Genistein affects the morphology of pituitary ACTH cells and decreases circulating levels of ACTH and corticosterone in middle-aged male rats. *Biol. Res.* 42, 13-23.
- Ajdžanović V., Šošić-Jurjević B., Filipović B., Trifunović S., Manojlović-Stojanowski M., Sekulić M. and Milošević V. (2009b). Genistein-induced histomorphometric and hormone secreting changes in the

- adrenal cortex in middle-aged rats. *Exp. Biol. Med.* (Maywood) 234, 148-156.
- Ajdžanović V.Z., Šošić-Jurjević B.T., Filipović B.R., Trifunović S.L. and Milošević V.Lj. (2011). Daidzein effects on ACTH cells: immunohistomorphometric and hormonal study in an animal model of the andropause. *Histol. Histopathol.* 26, 1257-1264.
- Ajdžanović V., Milošević V. and Spasojević I. (2012). Glucocorticoid excess and disturbed hemodynamics in advanced age: the extent to which soy isoflavones may be beneficial. *Gen. Physiol. Biophys.* 31, 367-374.
- Ajdžanović V., Medigović I., Živanović J., Šošić-Jurjević B., Trifunović S., Tanić N. and Milošević V. (2014). Immuno-histomorphometric and -fluorescent characteristics of GH cells after treatment with genistein or daidzein in an animal model of andropause. *Acta Vet. (Beograd)* 64, 93-104.
- Ajdžanović V., Jarić I., Živanović J., Filipović B., Ristić N., Miler M. and Milošević V. (2015). Testosterone application decreases the capacity for ACTH and corticosterone secretion in a rat model of the andropause. *Acta Histochem.* 117, 528-535.
- Ajdžanović V.Z., Jarić I.M., Živanović J.B., Filipović B.R., Šošić-Jurjević B.T., Ristić N.M., Stanković S.D. and Milošević V.Lj. (2016). Histological parameters of the adrenal cortex after testosterone application in a rat model of the andropause. *Histol. Histopathol.* 31, 1209-1220.
- Ajdžanović V., Jarić I., Miler M., Filipović B., Šošić-Jurjević B., Ristić N., Milenković D. and Milošević V. (2017a). Diosgenin-caused changes of the adrenal gland histological parameters in a rat model of the menopause. *Acta Histochem.* 119, 48-56.
- Ajdžanović V.Z., Filipović B.R., Šošić Jurjević B.T. and Milošević V.Lj. (2017b). Testosterone supplementation, glucocorticoid milieu and bone homeostasis in the ageing male. *Fund. Clin. Pharmacol.* 31, 372-382.
- Antonio J., Wilson J.D. and George F.W. (1999). Effects of castration and androgen treatment on androgen receptor levels in rat skeletal muscles. *J. Appl. Physiol.* 87, 2016-2019.
- Blouin S., Libouban H., Moreau M.F. and Chappard D. (2008). Orchidectomy models of osteoporosis. *Methods Mol. Biol.* 455, 125-134.
- Chahal H.S. and Drake W.M. (2007). The endocrine system and ageing. *J. Pathol.* 211, 173-180.
- Cho E.S., Lee S.Y., Park J.Y., Hong S.G. and Ryu P.D. (2007). Organotypic slice culture of the hypothalamic paraventricular nucleus of rat. *J. Vet. Sci.* 8, 15-20.
- da Paz L.H., Jorgetti V. and Yoshinari N.H. (1997). Animal models of osteoporosis. *Rev. Hosp. Clin. Fac. Med. Sao Paulo* 52, 86-89.
- Dorph-Petersen K.A., Nyengaard J.R. and Gundersen H.J. (2001). Tissue shrinkage and unbiased stereological estimation of particle number and size. *J. Microsc.* 204, 232-246.
- Filipović B., Šošić-Jurjević B., Ajdžanović V., Brkić D., Manojlović-Stojanovski M., Milošević V. and Sekulić M. (2010). Daidzein administration positively affects thyroid C cells and bone structure in orchidectomized middle-aged rats. *Osteoporos. Int.* 21, 1609-1616.
- Gaillard I., Keramidas M., Liakos P., Vilgrain I., Feige J.J. and Vittet D. (2000). ACTH-regulated expression of vascular endothelial growth factor in the adult bovine adrenal cortex: a possible role in the maintenance of the microvasculature. *J. Cell Physiol.* 185, 226-234.
- Ginci G., Arezzini L., Terzuoli L., Pizzichini M. and Marinello E. (1997). Effect of estradiol on serum triglyceride lipoprotein levels and fatty acid composition in castrated rats. *Horm. Metab. Res.* 29, 504-506.
- Gundersen H.J. and Jensen E.B. (1987). The efficiency of systematic sampling in stereology and its prediction. *J. Microsc.* 147, 229-263.
- Hatzinger M., Wotjak C.T., Naruo T., Simchen R., Keck M.E., Langraf R., Holsboer F. and Neuman I.D. (2000). Endogenous vasopressin contributes to hypothalamic-pituitary-adrenocortical alterations in aged rats. *J. Endocrinol.* 164, 197-205.
- Hoeflich A. and Bielohuby M. (2009). Mechanisms of adrenal gland growth: signal integration by extracellular signal regulated kinases1/2. *J. Mol. Endocrinol.* 42, 191-203.
- Hsu A., Bray T.M., Helferich W.G., Doerge D.R. and Ho E. (2010). Differential effects of whole soy extract and soy isoflavones on apoptosis in prostate cancer cells. *Exp. Biol. Med.* (Maywood) 235, 90-97.
- Jefferson W.N., Padilla-Banks E. and Newbold R.R. (2007). Disruption of the female reproductive system by the phytoestrogen genistein. *Reprod. Toxicol.* 23, 308-316.
- Jensen E.B. and Gundersen H.J. (1993). The rotator. *J. Microsc.* 170, 35-44.
- Ke H.Z., Qi H., Crawford D.T., Chidsey-Frink K.L., Simmons H.A. and Thompson D.D. (2000). Lasofoxifene (CP-336, 156), a selective estrogen receptor modulator, prevents bone loss induced by aging and orchidectomy in the adult rat. *Endocrinology* 141, 1338-1344.
- LaFlamme N., Nappi R.E., Drolet G., Labrie C. and Rivest S. (1998). Expression and neuropeptidergic characterization of estrogen receptors (ER α and ER β) throughout the rat brain: anatomical evidence of distinct roles of each subtype. *J. Neurobiol.* 36, 357-378.
- LeCouter J., Kowalski J., Foster J., Hass P., Zhang Z., Dillard-Telm L., Frantz G., Rangell L., DeGuzman L., Keller G.A., Peale F., Gurney A., Hillan K.J. and Ferrara N. (2001). Identification of an angiogenic mitogen selective for endocrine gland endothelium. *Nature* 412, 877-884.
- Lephart E.D., Setchell K.D., Handa R.J. and Lund T.D. (2004). Behavioral effects of endocrine disrupting substances: Phytoestrogens. *ILAR J* 45, 443-454.
- Maharaj A.S., Saint-Geniez M., Maldonado A.E. and D'Amore P.A. (2006). Vascular endothelial growth factor localization in the adult. *Am. J. Pathol.* 168, 639-648.
- Mahmoud A.M., Yang W. and Bosland M.C. (2014). Soy isoflavones and prostate cancer: A review of molecular mechanisms. *J. Steroid Biochem. Mol. Biol.* 140, 116-132.
- Malendowicz L.K. (1974). Sex differences in adrenocortical structure and function II. The effects of postpubertal gonadectomy and gonadal hormone replacement on the rat adrenal cortex evaluated by stereology at the light microscope level. *Cell Tissue Res.* 151, 537-547.
- Mazur W. and Adlercreutz H. (2000). Overview of naturally occurring endocrine-active substances in the human diet in relation to human health. *Nutrition* 16, 654-658.
- McEwan P.E., Lindop G.B. and Kenyon C.J. (1996). Control of cell proliferation in the rat adrenal gland in vivo by the renin-angiotensin system. *Am. J. Physiol. Endocrinol. Metab.* 271, E192-E198.
- Mitani F., Mukai K., Miyamoto H., Suematsu M. and Ishimura Y. (1999). Development of functional zonation in the rat adrenal cortex. *Endocrinology* 140, 3342-3353.
- Miyamoto H., Mitani F., Mukai K., Suematsu M. and Ishimura Y. (1999). Studies on cytogenesis in adult rat adrenal cortex: circadian and zonal variations and their modulation by adrenocorticotropic hormone. *J. Biochem.* 126, 1175-1183.
- Morales A. (2004). Andropause (or symptomatic late-onset

Andropausal adrenals after isoflavones

- hypogonadism): facts, fiction and controversies. *Aging Male* 7, 297-303.
- Picherit C., Coxam V., Bennetau-Pelissero C., Kati-Coulibaly S., Davicco M.J., Lebecque P. and Barlet J.P. (2000). Daidzein is more efficient than genistein in preventing ovariectomy-induced bone loss in rats. *J. Nutr.* 130, 1675-1681.
- Setchell K.D. (1998). Phytoestrogens: the biochemistry, physiology, and implications of human health of soy isoflavones. *Am. J. Clin. Nutr.* 68 (suppl), 1333S-1346S.
- Shughrue P.J. and Merchenthaler I. (2001). Distribution of estrogen receptor beta immunoreactivity in the rat central nervous system. *J. Comp. Neurol.* 436, 64-81.
- Šošić-Jurjević B., Filipović B., Ajdžanović V., Brkić D., Ristić N., Manojlović-Stojanoski M., Nestorović N., Trifunović S. and Sekulić M. (2007). Subcutaneously administered genistein and daidzein decrease serum cholesterol and increase triglyceride levels in male middle-aged rats. *Exp. Biol. Med.* (Maywood) 232, 1222-1227.
- Šošić-Jurjević B., Ajdžanović V., Filipović B., Trifunović S., Jarić I., Ristić N. and Milošević V. (2016). Functional morphology of pituitary-thyroid and -adrenocortical axes in middle-aged male rats treated with *Vitex agnus castus* essential oil. *Acta Histochem.* 118, 736-745.
- Swann H. (1940). The pituitary-adrenocortical relationship. *Physiol. Rev.* 20, 493-521.
- Thomas M., Keramidis M., Monchaux E. and Feige J.J. (2003). Role of adrenocorticotrophic hormone in the development and maintenance of the adrenal cortical vasculature. *Microsc. Res. Tech.* 61, 247-251.
- Trifunović S. and Milošević V. (2018). The morpho-functional parameters of rat pituitary hormone producing cells after genistein treatment. *Mac. Vet. Rev.* 41, 5-19.
- Trifunović S., Manojlović-Stojanoski M., Ajdžanović V., Nestorović N., Ristić N., Medigović I. and Milošević V. (2012). Genistein stimulates the hypothalamo-pituitary-adrenal axis in adult rats: morphological and hormonal study. *Histol. Histopathol.* 27, 627-640.
- Trifunović S., Manojlović-Stojanoski M., Ajdžanović V., Nestorović N., Ristić N., Šošić-Jurjević B. and Milošević V. (2014). Soy extract-dependent changes in morphofunctional parameters of the pituitary corticotropes in adult rats. *Acta Histochem.* 116, 717-722.
- Ulrich-Lai Y.M., Figueiredo H.F., Ostrander M.M., Choi D.C., Engeland W.C. and Herman J.P. (2006). Chronic stress induces adrenal hyperplasia and hypertrophy in a subregion-specific manner. *Am. J. Physiol. Endocrinol. Metab.* 291, E965-E973.
- Vinson G.P. (2003). Adrenocortical zonation and ACTH. *Microsc. Res. Tech.* 61, 227-239.
- Wespes E. and Schulman C.C. (2002). Male andropause: myth, reality, and treatment. *Int. J. Impot. Res. (Suppl 1)*, S93-S98.
- Williamson M., Bingham B. and Viau V. (2005). Central organization of androgen-sensitive pathways to the hypothalamic-pituitary-adrenal axis: implications for individual differences in responses to homeostatic threat and predisposition to disease. *Prog. Neuropsychopharmacol. Biol. Psychiatry* 29, 1239-1248.
- Wolkersdörfer G.W. and Bornstein S.R. (1998). Tissue remodelling in the adrenal gland. *Biochem. Pharmacol.* 56, 163-171.
- Yaswen L., Diehl N., Brennan M.B. and Hochgeschwender U. (1999). Obesity in the mouse model of pro-opiomelanocortin deficiency responds to peripheral melanocortin. *Nat. Med.* 5, 1066-1070.

Accepted March 12, 2018