

Digital image analysis of the tissue surface areas of site-designated and bilaterally pooled prostate biopsies

Laura Koivusalo^{1,2}, Antti Kaipia¹, Paula Kujala², Jorma Isola³ and Teemu T. Tolonen^{2,3}

¹Department of Surgery, Satakunta Hospital District, Pori, ²Department of Pathology, Fimlab Laboratories, Tampere University Hospital and ³Department of Cancer Biology, BioMediTech, University of Tampere, Tampere, Finland

Summary. Initial reports about the length of bilaterally pooled biopsies showed alarming tissue loss compared to individual biopsies, but the current understanding of “noodle biopsies” and better embedding techniques may have improved their quality. Here, we implemented digital image analysis to study the differences in tissue surface areas between individual and pooled cores. Prostate biopsy reports from 1242 consecutive patients were reviewed. Urologist-dependent bias on the biopsy quality was eliminated by identifying four urologists who submitted equally individual and bilaterally pooled biopsies. Digital image analysis was applied to the tissue surface areas of 936 virtual slides containing 1440 biopsy cores (12 cores per patient x 120 patients) taken by the four urologists. The median (range) surface areas were 73.8 mm² (40.1-102.5) for the site-designated (n=57) and 77.1 mm² (49.5-119.2) for the bilaterally pooled biopsies (n=63) (p=0.19). For three urologists, the median surface areas were 69.5 mm² (60.4-93.2), 75.5 mm² (48.2-98.7) and 78.2 mm² (47.1-92.7) for the site-designated and 79.2 mm² (49.5-116.4), 69.3 mm² (49.6-119.2) and 79.2 mm² (55.1-96.7) for the pooled biopsies, respectively (p=0.58-0.75). For one urologist, the median surface area was marginally higher for the pooled biopsies, 68.1 mm² (40.1-102.5) vs. 81.6 mm² (62.7-108.8) (p=0.03). In conclusion, the histological yields of individual and pooled prostate biopsies were practically equal. The results should not be considered as

a recommendation to increasingly submit unspecified bilateral cores but to encourage pathology laboratories to embed and cut all received prostate biopsies with special attention, regardless of submission type.

Key words: Prostate needle biopsy, Biopsy quality, Digital image analysis, Guidelines

Introduction

Diagnosis of prostate cancer is based on the histological evaluation of prostate biopsies, and the accuracy of the diagnosis depends on the quality of samples on the microscope slide. The commonly accepted biopsy scheme consists of 10-12 systematic needle cores with additional cores from suspect areas (Presti, 2007; Ukimura et al., 2013), but submission and embedding protocols are variables (Varma et al., 2013). Individually submitted cores are recommended by the international guidelines (Van der Kwast et al., 2003, 2013; Presti, 2007; Ukimura et al., 2013), but some urologists prefer submitting less labor-intensive bilateral biopsies, depending on the clinical situation. According to a recent survey, approximately half of European pathology laboratories still receive bilateral biopsies pooled in two specimen containers, whereas only 40 % received all prostate biopsy cores in separate vials (Varma et al., 2013).

Because of high prevalence of prostate cancer and the large number of cores per biopsy set, pathology laboratories have become increasingly aware of the costs of prostate biopsy handling. Pooling prostate biopsy

Offprint requests to: Teemu T. Tolonen, Department of Pathology, Fimlab Laboratories, Biokatu 4, 33520 Tampere, Finland. e-mail: teemu.tolonen@fimlab.fi
DOI: 10.14670/HH-11-940

cores may reduce the costs of biopsy processing, but it is not encouraged by the international guidelines. One major concern is that the quality obtained from pooled prostate biopsy is not adequate for proper diagnosis, because single cores are easier to align in the paraffin block for maximal surface area representation than multiple cores (Kao et al., 2002; Boccon-Gibod et al., 2004; Gupta et al., 2004). Current guidelines by the ERSPC (European Randomized Study for Screening of Prostate Cancer) committee allow the embedding of up to three cores in the same paraffin block, provided that proper pre-embedding methods are used to avoid curling and floating of the biopsies (Rogatsch et al., 2000; Bertaccini et al., 2007; Van der Kwast et al., 2013). From a narrow quality point of view, the maximum number of biopsies in one block may be a matter of technique as in our previous study, the number of cores (one to nine) embedded to a single paraffin block did not affect the length of the biopsies (Tolonen et al., 2015).

Digital image analysis is increasingly used in pathology due to advancing slide scanner and storage technology and it is presumably the most accurate method for determining biopsy surface area. Because in our previous work, the lengths of bilaterally pooled biopsies were unexpectedly high (Tolonen et al., 2015), we wanted to further evaluate whether embedding six biopsies to a single paraffin block would have an impact on the actual histological yields, and applied digital image analysis to the core slice surface areas of the whole slide images of the prostate biopsies. At Tampere University Hospital (TAUH) district, it is still more common to sample bilaterally pooled biopsies than individual cores, which may potentially introduce a bias to the results. Therefore, we also eliminated the operator-dependent bias on biopsy quality (Van der Kwast et al., 2013) by identifying urologists who took both specimen types equally, and by analyzing their specimens individually according to the urologist.

Materials and methods

The study was conducted under approval of the Ethical Committee of Tampere University Hospital, reference number R03203.

We retrospectively screened 1242 consecutive prostate needle biopsy cases evaluated in the Department of Pathology at Fimlab Laboratories between March 2013 and September 2014 from the pathology database of Fimlab Laboratories. The biopsies had been taken from patients with elevated PSA-values and/or suspect findings in digital rectal examination. All biopsies had been taken under transrectal ultrasound guidance using an 18-gauge needle biopsy gun with an 18-mm sample notch (Bard Peripheral Vascular, Temple, AZ, U.S.A., ref no. MC 1825) and were placed into 10% buffered formalin vials directly from the biopsy needle. All prostate biopsies were processed at Fimlab Laboratories. The contents of each specimen vial were straightened in the tissue cassette between two sponges with forceps and

processed between two sponges pre-reated with formalin. The embedding process was “as usual” and essentially the same for both individually submitted and pooled cores: the metallic tissue mold was partly filled with hot paraffin and placed on the heated plate of the embedding station, and then the straightened biopsy cores were transferred to the bottom of the mold with forceps and cooled down on the cold plate. No special equipment for embedding was used. Tissue ink was not utilized to identify biopsy location. The contents of one cassette were embedded into one block, resulting in 12 blocks for individually submitted cores and two blocks for pooled cores. The blocks were sectioned and stained routinely with hematoxylin-eosin stain (H&E).

The biopsy cases in the pathology database were categorized based on the submission and embedding method (12 individual cores, 6+6 pooled cores, or other). The cases were categorized based on both urologists' referrals and pathologists' reports in the TAUH pathology database. Four urologists who had submitted approximately equal amounts of both individual cores and bilaterally pooled biopsy cores were identified, and their samples were retrieved from the sample archives. The type of biopsy was verified from the original microscope slides, and only cases containing exactly 12 cores were included in the study. The inclusion scheme and typical sets of microscope slides for individually submitted and unspecified bilateral biopsies are illustrated in (Fig. 1).

The microscope slides of individual cores contained usually two or three, but occasionally up to six slices per core, always resulting in one microscope slide. Pooled cores were consistently cut on four levels, resulting in two microscope slides. The microscope slides were scanned using an Aperio AT2 whole slide scanner (Leica Biosystems, Nussloch, Germany) using 20x magnification with a resolution of 0.5 $\mu\text{m}/\text{pixel}$. The scanned virtual slides were converted into JPEG2000-files using JP2 WSI Converter software, version 1.0.2 (BioMediTech, University of Tampere, Tampere, Finland). The JPEG2000-files were then opened using JVSview virtual microscope software, version 1.2 (University of Tampere, Tampere, Finland), which allowed exportation of the images to the image analysis software ImageJ, version 1.48v (National Institute of Health, USA). With ImageJ, the snapshot images from virtual slides were analyzed to determine the total area available for histopathological evaluation.

Image analysis

To transform the images into a form that could be analyzed, we created a macro script for ImageJ. The function of the macro is illustrated step by step in Fig. 2, and the full macro is provided in Table 1. First, to separate the tissue sample from the background, a threshold was applied to the image. We used experimentally determined threshold values to remove most artifacts and to recognize the maximum amount of

Digital image analysis of the tissue surface areas of prostate biopsies

tissue. Second, the pixels remaining outside of the sample area after thresholding were removed as outliers. We defined the maximum size of outliers to be 2 pixels. Third, we used the “Fill holes” function to fill the empty spaces in the sample area because the gland structures of prostate tissue are part of the core surface area.

The actual surface area measurements were performed separately for each paraffin block slice image utilizing the “Analyze particles” function of ImageJ. All of the slice images obtained from each block were analyzed. Because the number of slices from each block varied, we used the average of the two best (i.e., largest surface area) slices from each to obtain the least biased estimate for comparing the biopsy quality of the two sample types. For individual cores, the average area measurement for each core was summed to give the total surface area of the biopsy. For the pooled cores, the average combined area of the six cores from the left and the right were summed.

Statistical analysis

The statistical significance between the surface area measurements of individually submitted and bilaterally pooled cores was determined using the Wilcoxon-Mann-Whitney U-test at 95 % confidence level ($p=0.05$). To account for operator-dependent variation, the significance testing was performed between each urologist’s 12 individual and pooled samples. The statistical analysis was performed with IBM SPSS Statistics, version 22.

Results

Based on the written reports of the pathology database, 202 (16.3 %) of the total 1242 cases were identified as individually submitted biopsies, and 613 (49.4 %) were categorized as pooled bilateral biopsies. A total of 427 (34.4 %) cases were categorized as “other”,

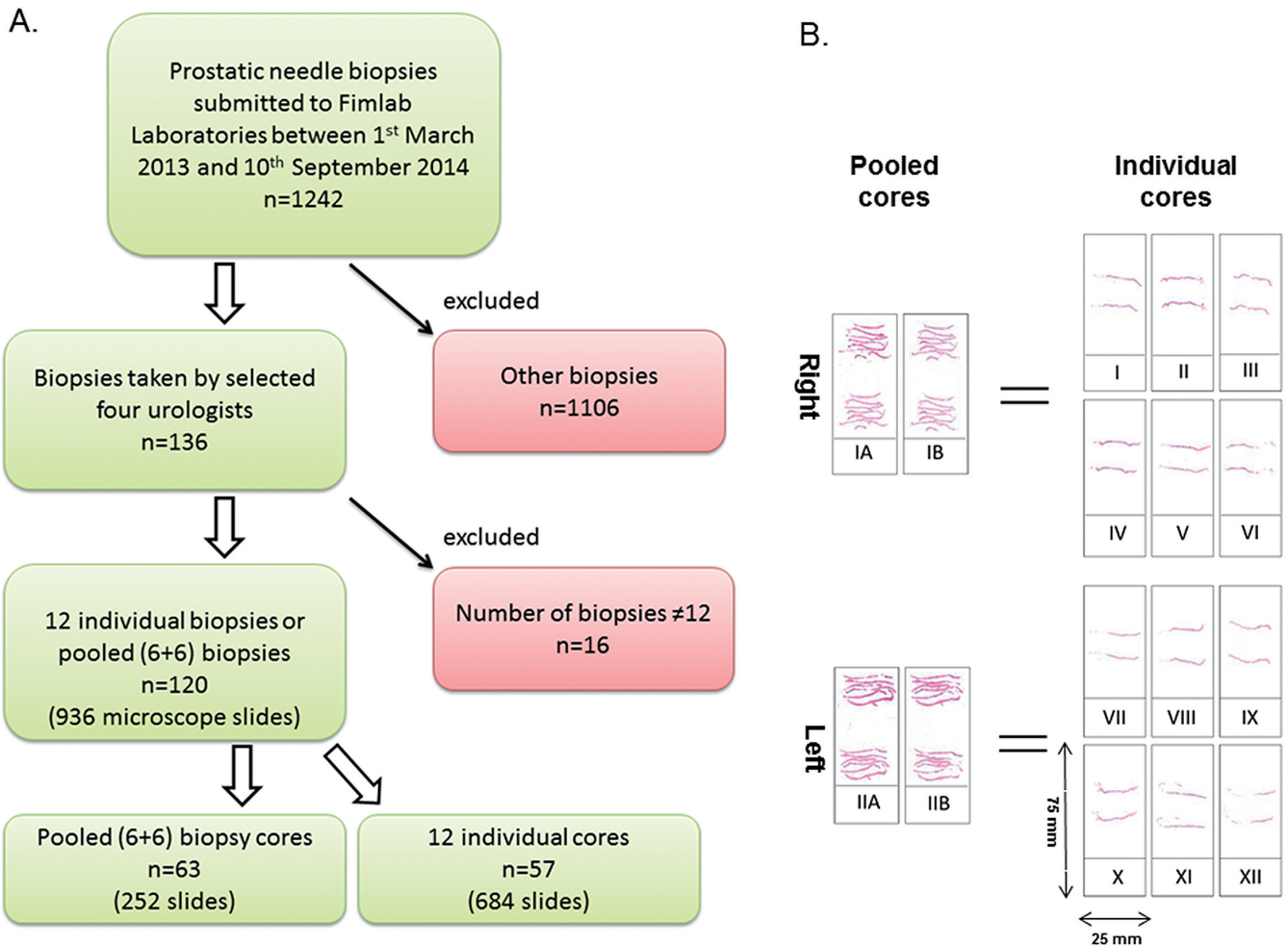


Fig. 1. A. Inclusion scheme of the cases for the study. B. An example of a typical microscope slide arrays bilaterally pooled and site-designated prostate biopsies.

including cases where the number and submission type of biopsy cores was unavailable (37 cases).

Over 20 different urologists from Tampere University Hospital district contributed to the 1242 samples submitted for evaluation at Fimlab Laboratories during the period of investigation. The four urologists whose samples were included in the study are denoted by the numbers 1-4. The four urologists contributed 16% of all of the samples during this time. Urologists 1-4 were all experienced in taking prostate needle biopsies with 10, 22, 16 and 6 years of experience, respectively.

The overall median (range) surface areas were similar for both submission types, 73.8 mm² (40.1-102.5) for the site-designated (n=57) and 77.1 mm² (49.5-119.2) for the bilaterally pooled biopsies (n=63) (p=0.19). In addition, statistical significance was

calculated separately for each urologist's samples (Fig. 3). The only statistically significant difference was found in urologist 4's biopsies, with the pooled core biopsies having marginally larger tissue surface areas than the individual cores (p=0.03).

Discussion

Site-designated individual prostatic needle biopsies are favored by all current international guidelines, but depending on the pathology laboratory and region, it is not uncommon to receive pooled biopsies submitted by the urologists (Biedrzycki et al., 2003; Varma et al., 2013; Tolonen et al., 2015). Although poor multi-embedding technique can lead to severely reduced biopsy length (Yfantis et al., 2002), current awareness of the "noodle biopsies" and paying more attention to the embedding process should have improved the quality of pooled biopsies. Our aim was to compare the tissue surface areas of individual vs. pooled cores in a pathology laboratory with experience in handling both submission types.

With the emerging digital pathology, there is an ongoing paradigm shift from a ruler to high-resolution image analysis of digitized slides. In the present study, we applied digital image analysis to the tissue surface areas of 936 virtual slides containing 684 individually embedded and 756 bilaterally pooled biopsy cores sliced in 2-4 planes. In addition, we tried to eliminate the operator-dependent bias (Van der Kwast et al., 2013) by selecting urologists performing equally both submission types, and comparing surface areas of separately embedded and pooled biopsies individually according to the urologist.

The overall median tissue surface areas were similar for 12 individually submitted (73.8 mm²) and bilaterally pooled 6+6 cores (77.1 mm²) (p=0.19), and there were no significant differences between each urologists individual and pooled biopsy areas, except for one urologist, who had marginally higher surface areas on pooled biopsies (p=0.03). Although pooled biopsies performed unexpectedly well, possibly due to compensatory slices according to our laboratory instructions (2-3 slices from individual biopsies, four from pooled biopsies), the results are concordant with our previous work in which we did not find significant differences in the biopsy core lengths between the two submission types (Tolonen et al., 2015). In our laboratory, the biopsies are straightened and processed between sponges that have been pre-moistured with formalin. The contents of each biopsy container are processed and embedded together, individual biopsies leading to 12 paraffin blocks, and pooled biopsies leading to two blocks per case. It is especially important to embed biopsies carefully to the bottom of the metal mold, and to not tolerate any overlapping of the cores. Slicing should target to the central axis of the biopsy (or biopsies), which can affect the slice surface areas significantly. In addition, some material should be

Table 1. ImageJ macro for analyzing surface area of a sample.

```
//Surface area of prostate samples
//run("Threshold...");
min=newArray(3);
max=newArray(3);
filter=newArray(3);
a=getTitle();
run("HSB Stack");
run("Convert Stack to Images");
selectWindow("Hue");
rename("0");
selectWindow("Saturation");
rename("1");
selectWindow("Brightness");
rename("2");
min[0]=0;
max[0]=255;
filter[0]="pass";
min[1]=15;
max[1]=255;
filter[1]="pass";
min[2]=0;
max[2]=238;
filter[2]="pass";
for (i=0;i<3;i++){
  selectWindow(i);
  setThreshold(min[i], max[i]);
  run("Convert to Mask");
  if (filter[i]=="stop") run("Invert");
}
imageCalculator("AND create", "0","1");
imageCalculator("AND create", "Result of 0","2");
for (i=0;i<3;i++){
  selectWindow(i);
  close();
}
selectWindow("Result of 0");
close();
selectWindow("Result of Result of 0");
rename(a);
// Colour Thresholding-----
makeLine(0, 0, 0, 0);
setOption("BlackBackground", false);
run("Remove Outliers...", "radius=2 threshold=50 which=Dark");
run("Fill Holes");
```

Digital image analysis of the tissue surface areas of prostate biopsies

spared for possible immunohistochemical stainings. All this makes it quite a difficult task, and needs an experienced technician with good visuospatial skills.

There are multiple reasons in favor of site-designated biopsies. The cores submitted in separate vials are less prone to fragmentation and tissue entanglement than pooled cores, which enables reporting the number of positive cores to be more accurate (Fajardo and Epstein, 2010). In addition, individual biopsies are easier to embed into a single plane for maximal tissue representation (Gupta et al., 2004), which can influence the detection rate of cancer and small atypical lesions (Iczkowski et al., 2002; Öbek et al., 2012). Most importantly, individually submitted biopsies spare biopsy location information, which is pivotal for the planning of the robotic surgery and act as a guide for re-biopsy sites in active surveillance (Kao et al., 2002; Van der Kwast et al., 2003, 2013; Boccon-Gibod et al., 2004). On the other hand, some authorities have pointed out that a widespread use of individual core submission would increase the workload of already stretched pathology laboratories. For instance, Bostwick and Kahane have recommended submitting three biopsy cores per cassette for economic reasons (Bostwick and Kahane, 2013). Although the exact locus information will be lost using suggested three-cores-three-slices system, the authors did not find evidence of lowered diagnostic rate for atypical small acinar proliferation,

high grade prostatic intraepithelial neoplasia or adenocarcinoma (Bostwick and Kahane, 2013). Accordingly, the results of the present study suggest that higher histological yield alone seems to be a weak argument for favoring individual cores. Therefore, it seems reasonable that pooled 6+6 biopsies might be utilized to reduce the pathology laboratory workload in selected cases in eg. patients out of radical treatment due to high age or PSA, or with advanced disease. Fimlab Laboratories receives both individual and pooled prostate biopsies from approximately 1000 patients annually. Receiving all biopsies separately would yield 12 000 paraffin blocks compared to 2000 blocks using bilateral 6+6 biopsies. Although the multi-embedding of the latter may be more difficult and time consuming, it can aid reducing the workload later in the process. We estimate that cutting 10 000 extra blocks would take about 100 labor days (or 5 months) from an experienced technician.

Although our aim was not to compare operating urologists, there was some operator-dependent variation in the results, as proposed by Van der Kwast et al. (2013). The total surface area measurements span large ranges, but there is no overall trend in the dispersions of the total surface areas between pooled and individually submitted biopsies. The size of the range for urologist 1's pooled biopsies (66.90 mm²) is much larger than for individual biopsies (32.85 mm²). Conversely, for

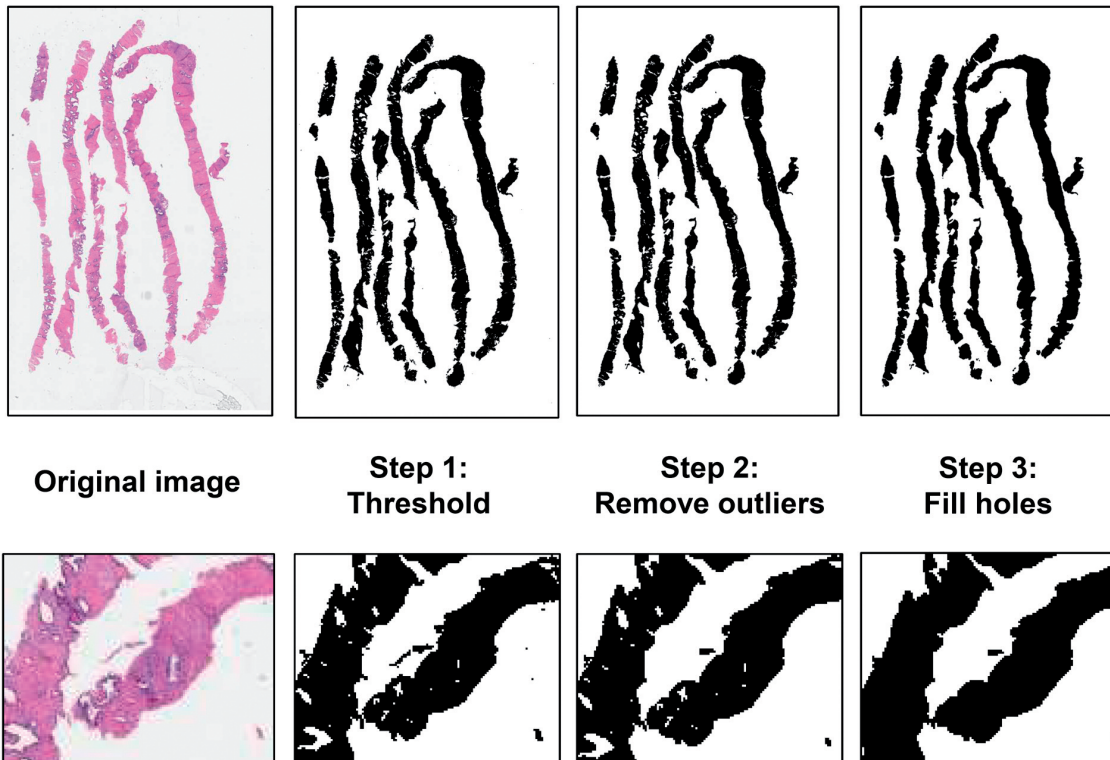


Fig. 2. The functions performed by the ImageJ macro on the image of a pooled prostate biopsy sample.

Digital image analysis of the tissue surface areas of prostate biopsies

urologist 4, the range of values is larger for individual biopsies (62.40 mm²) than for pooled biopsies (46.13 mm²). For urologists 2 and 3, the sizes of the value ranges are approximately equal for both types of samples. The largest total surface area value is found in the pooled biopsies group for all urologists, which may indicate that the total surface area determination technique is biased towards pooled biopsies. It seems likely that measuring the actual biopsy area in mm² instead of just measuring their length highlights this variation. As mentioned earlier, site-designated biopsies were generally sliced on two to three levels and pooled biopsies at four levels, which may introduce the aforementioned bias. However, it seems to be a justified practice as the histological yields were similar while at the same time the total number of slides remain low (Fig. 1).

The ImageJ macro may have induced some error in the surface area measurements. First, the value of the measured area depends on the resolution (i.e., pixel size) because we modify the image on a pixel level. The effects of the “Remove outliers” and “Fill holes” functions especially depend on the image resolution.

However, we used the same image resolution throughout the study, so the resultant error is systematic and should not affect the comparability of the results. Second, the “Fill holes” function works for enclosed regions, whereas open glands are not taken into account. Meanwhile, if a core has stretched, leaving empty space inside the area of a sample, it is filled and influences the area measurement. This may cause random error in the measurements.

Conclusions

Digital image analysis of the tissue surface area of prostate biopsies is the ultimate way to measure their histologic yield. Although a wide intra-operator variation was seen in image analysis of the tissue surface areas of both individual and pooled prostate biopsies, the median tissue surface areas were equal regardless of the submission type. Our results suggest that the histologic yields of carefully embedded bilaterally pooled prostate biopsies can approach the level of individually embedded biopsies; at least they seem to have done so at our institute. To confirm these results, a multicenter

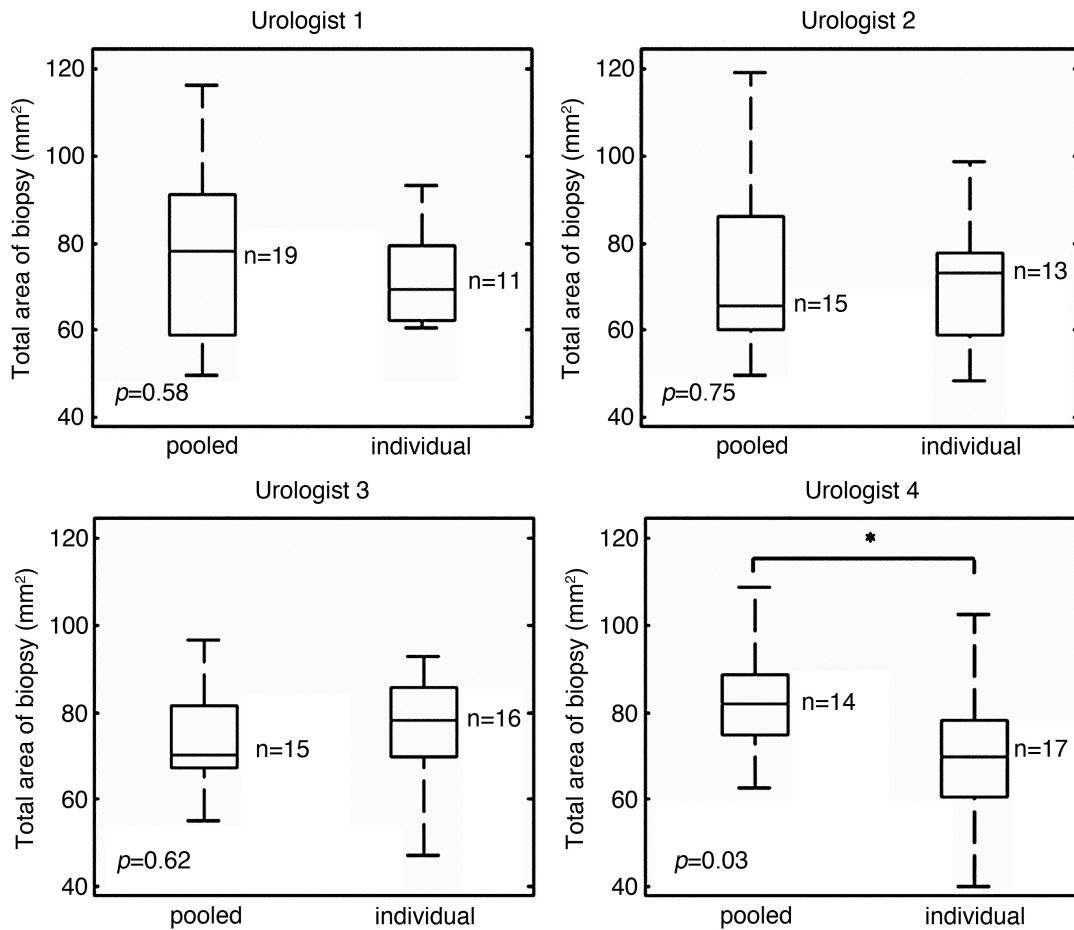


Fig. 3. Boxplots showing the distributions of the surface areas of the pooled and individually submitted prostate samples according to the operating urologist. *significance at p=0.05.

Digital image analysis of the tissue surface areas of prostate biopsies

study would be necessary. Finally, the results should not be considered as a recommendation to increasingly submit unspecified bilateral cores but to encourage pathology laboratories to embed and slice all received prostate biopsies with special attention, regardless of submission type.

Acknowledgements: We would like to thank Tampere University Hospital urologists M. Aho, J. Koskimäki, A. Kotsar and T. Murtola (in alphabetical order) for providing the samples used in this study and Satakunta and Pirkanmaa Hospital Districts for funding the research. We would also like to thank Ph.D. Pekka Ruusuvoori for his valuable comments. Finally, we would like to thank the dedicated laboratory technicians of Fimlab Laboratories.

Authors' contribution: L Koivusalo: Data collection, image analysis development, data analysis, manuscript writing; A Kaipia: Project development, manuscript editing; P Kujala: Project development, manuscript editing; J Isola: Image analysis development, manuscript editing; TT Tolonen: Project development, manuscript writing

This article does not contain any studies with human participants or animals performed by any of the authors.

Conflicts of interest: The authors declare that they have no conflicts of interest.

References

- Bertaccini A., Fandella A., Prayer-Galetti T., Scattoni, V., Galosi, A. B., Ficarra, V., Trombetta C., Gion M. and Martorana G. (2007). Systematic development of clinical practice guidelines for prostate biopsies: A 3-year italian project. *Anticancer Res.* 27, 659-666.
- Biedrzycki O., Varma M. and Berney D.M. (2003). Variations in the processing of prostatic needle cores in the UK; what is safe?. *J. Clin. Pathol.* 56, 341-343.
- Boccon-Gibod L., van der Kwast T.H., Montironi R., Boccon-Gibod L. and Bono A. (2004). Handling and pathology reporting of prostate biopsies. *Eur. Urol.* 46, 177-181.
- Bostwick D.G. and Kahane H. (2013). Adequate histologic sectioning of prostate needle biopsies. *Ann. Diagn. Pathol.* 17, 357-360.
- Fajardo D.A. and Epstein J.I. (2010). Fragmentation of prostatic needle biopsy cores containing adenocarcinoma: the role of specimen submission. *BJU Int.* 105, 172-175.
- Gupta C., Ren J.Z. and Wojno K.J. (2004). Individual submission and embedding of prostate biopsies decreases rates of equivocal pathology reports. *Urology* 63, 83-86.
- Iczkowski K.A., Casella G., Seppala R.J., Jones G.L., Mishler B.A., Qian J. and Bostwick D.G. (2002). Needle core length in sextant biopsy influences prostate cancer detection rate. *Urology* 59, 698-703.
- Kao J., Upton M., Zhang P. and Rosen S. (2002). Individual prostate biopsy core embedding facilitates maximal tissue representation. *J. Urol.* 168, 496-499.
- Öbek C.I., Doğanca T., Erdal S., Erdoğan S. and Durak H. (2012). Core length in prostate biopsy: size matters. *J. Urol.* 187, 2051-2055.
- Presti J.C. (2007). Prostate biopsy: Current status and limitations. *Rev. Urol.* 9, 93-98.
- Rogatsch H., Mairinger T., Horninger W., Gschwendtner A., Bartsch G. and Mikuz G. (2000). Optimized preembedding method improves the histologic yield of prostatic core needle biopsies. *Prostate* 42, 124-129.
- Tolonen T.T., Isola J., Kaipia A., Riikonen J., Koivusalo L., Huovinen S., Laurila M., Porre S., Tirkkonen M. and Kujala P. (2015). Length of prostate biopsies is not necessarily compromised by pooling multiple cores in one paraffin block: an observational study. *BMC Clin. Pathol.* 15, 4.
- Ukimura O., Coleman J.A., de la Taille A., Emberton M., Epstein J.I., Freedland S.J., Giannarini G., Kibel A.S., Montironi R., Ploussard G., Roobol M.J., Scattoni V. and Jones J.S. (2013). Contemporary role of systematic prostate biopsies: Indications, techniques, and implications for patient care. *Eur. Urol.* 63, 214-230.
- Van der Kwast T.H., Lopes C., Santonja C., Pihl C.G., Neetens I., Martikainen P., Di Lollo S., Bubendorf L. and Hoedemaeker R.F. (2003). Guidelines for processing and reporting of prostatic needle biopsies. *J. Clin. Pathol.* 56, 336-340.
- Van der Kwast T., Bubendorf L., Mazerolles C., Raspollini M.R., Van Leenders G.J., Pihl C.G. and Kujala P. (2013). Guidelines on processing and reporting of prostate biopsies: the 2013 update of the pathology committee of the European Randomized Study of Screening for Prostate Cancer (ERSPC). *Virchows Arch.* 463, 367-377.
- Varma M., Berney D.M., Algaba F., Camparo P., Compérat E., Griffiths D.F., Kristiansen G., Lopez-Beltran A., Montironi R. and Egevad L. (2013). Prostate needle biopsy processing: a survey of laboratory practice across Europe. *J. Clin. Pathol.* 66, 120-123.
- Yfantis H.G., Loffe O.B. and Silverberg S.G. (2002). Prostate core biopsies processing: Evaluating current practice. *USCAP annual meeting, Chicago*, p 347 A., Abstract 1447.

Accepted October 23, 2017