

Anti-inflammatory effects of enemas containing an oily extract of curcumin in an experimental model of diversion colitis

Caled Jaoudat Kadri¹, José Aires Pereira¹, Fábio Guilherme Campos²,
Manoela Marques Ortega¹, Celene Benediti Bragion¹ and Carlos Augusto Real Martinez³

¹Laboratory of Medical Investigation, São Francisco University (USF), Bragança Paulista, ²Department of Surgery, Faculty of Medicine of São Paulo University (FMUSP), São Paulo and ³Laboratory of Medical Investigation, São Francisco University (USF), Bragança Paulista and Department of Surgery, University of Campinas (UNICAMP), Campinas, SP, Brazil

Summary. Curcumin has powerful anti-inflammatory and antioxidant effects and it has been used for treatment of distal ulcerative colitis. The therapeutic effects of curcumin have not yet been evaluated in diversion colitis. The aim of the present study was to evaluate the anti-inflammatory effects of curcumin on colonic mucosa devoid of a faecal stream. Thirty-six rats were subjected to a proximal colostomy and distal colonic fistulation. They were divided into two groups, which were sacrificed two or four weeks after the intervention. Each group was divided into three subgroups treated with the daily application of enemas containing saline or an oily extract of curcumin at 50 mg/kg/day or 200 mg/kg/day. Colitis was diagnosed by histological analysis. Inflammatory grades were assessed using a previously validated scoring system. The infiltration of neutrophils was evaluated based on the tissue expression of myeloperoxidase (MPO), as determined by immunohistochemistry, and a computer-assisted image analysis program. The Mann-Whitney test was used to compare inflammation grades and myeloperoxidase levels among groups, and ANOVA was used to verify the variance over time, with the level of significance set at 5% ($p < 0.05$) for both tests. Enemas containing curcumin improved the inflammation of the mucosa without a faecal stream and reduced the tissue contents

of MPO. MPO tissue levels did not vary with time or between the concentrations of curcumin used. Enemas with curcumin improved the inflammation of the colonic mucosa, reduced the inflammatory grade and decreased the tissue content of MPO in colon segments without a faecal stream.

Key words: Colitis, Fatty Acids, Volatile, Curcumin, Image Processing, Computer-Assisted

Introduction

Glotzer et al. (1981) were the first to describe the development of an inflammatory process in the mucosa of colon segments devoid of a faecal stream (Glotzer et al., 1981). They termed this new form of inflammatory bowel disease (IBD) diversion colitis (DC). Short-chain fatty acids (SCFAs), particularly butyrate, are the main energy source for colonocytes (Roediger and Nance, 1990). SCFAs account for more than 80% of the energy fuel needs in the cells of the colonic epithelium and are required to maintain their energetic metabolism and other specialized functions, such as cell signalling, gene transcription and protein synthesis (Oliveira-Neto and Aguilar-Nascimento, 2004). In colon segments devoid of a faecal stream, the absence of dietary fibres prevents the formation of SCFAs and their absorption and use by epithelial cells (Oliveira-Neto and Aguilar-Nascimento, 2004).

The molecular mechanisms by which the deficiency of SCFAs leads to the appearance of DC are still controversial (Martinez et al., 2010a). Recent studies

Offprint requests to: Carlos Augusto Real Martinez, Laboratory of Medical Investigation, Postgraduate Program in Health Science, São Francisco University, Rua José Raposo de Medeiros, 474 apto. 602., Bragança Paulista - CEP: 12.914-450 - São Paulo - Brasil. e-mail: carmartinez@uol.com.br

DOI: 10.14670/HH-11-783

have shown that absence of SCFAs modifies the energetic metabolism of the mitochondrial respiratory chain of colonocytes, leading to an increase in the production of reactive oxygen species (ROS) (Martinez et al., 2010a). ROS are harmful to the cells of the colonic mucosa and may cause dysfunction in various defence systems that are present in the barrier of the colonic epithelium (Nonose et al., 2009; Martinez et al., 2010b; Kadri et al., 2013). The intestinal epithelium has intrinsic antioxidant systems to neutralize the increased production of ROS and avoid oxidative stress. However, it has been shown that the antioxidant systems present in the colonic mucosa are deficient compared with those in other organs and tissues, resulting in a greater vulnerability of the colonic mucosa to oxidative stress (Tham et al., 2002). The resulting oxidative stress can break down the different lines of defence that form the epithelial barrier of the colonic mucosa. Other studies have shown that oxidative stress can lead to reductions of the mucus layer and modifications of the mucin types that cover the colonic mucosa in experimental models of DC (Nonose et al., 2009; Martinez et al., 2010b). It has also been shown that the overproduction of ROS can damage the protein constituents of tight and adherence junctions, allowing bacterial infiltration into the sterile submucosa to trigger an inflammatory response (Martinez et al., 2012; Kadri et al., 2013). The application of enemas containing substances with antioxidant activity to colon segments with colitis can reduce the levels of oxidative stress and preserve the protein constituents of the epithelial barrier (Caltabiano et al., 2011; Cunha et al., 2011; Martinez et al., 2015; Trujillo et al., 2016).

Curcumin is a substance derived from the rhizome of *Curcuma longa* and has been shown to be one of the most promising natural antioxidants (Aggarwal et al., 2007; Samuhasaneeto et al., 2009). Curcumin is able to relieve symptoms, reduce inflammatory activity and maintain sustained clinical responses in patients with IBD (Ali et al., 2012; Vecchi Brumatti et al., 2014). Although the effects of curcumin administration have been evaluated in patients and experimental models of chemical-induced colitis, to the best of our knowledge, the topical effects of curcumin have not been evaluated in an experimental model of DC (Zeng et al., 2013; Lang et al., 2015). Thus, the objective of this study was to evaluate the effects of enemas containing curcumin on the colonic mucosa in an experimental model of DC.

Materials and methods

Ethics

The experiments were performed in accordance with the principles outlined by Federal Law number 11,794 (10/08/2008) and the Brazilian College for Animal Experimentation (COBEA) and were approved by the Ethics Committee in Animal Research of São Francisco University (Number 22.11/07).

Animals

Thirty-six male specific pathogen-free Wistar rats (300-350g) were obtained from the São Francisco University School of Medicine barrier facility and were maintained on a light/dark cycle of 12 hours and fed a standard rodent chow diet. The rats were deprived of food, but not water, for 12 h prior to the surgical procedure.

Surgical technique

The diversion of the faecal stream was performed in all animals under general anaesthesia, which was induced by an intramuscular administration of 0.1 ml/100 g of a 1:1 (v/v) solution of ketamine (50 mg/ml) and xylazine (20 mg/ml). The abdomen was shaved, and a 3-cm midline incision was made. The left colon was exteriorized and sectioned in its mid-portion, corresponding to the descending colon, approximately 3 cm above the Peyer's lymphoid patch located in the rectal-sigmoid transition. Two circular skin pellets, 3 mm in diameter and 3 cm apart, were made in the left side of the abdominal wall at the same vertical level. The proximal end of the colon was exteriorized through the cranial cutaneous orifice, and the distal stoma was exteriorized through the caudal skin opening after splitting the abdominal wall muscles. The proximal end and the distal stoma were fixed to the skin with full-thickness sutures. Before the fixation of the distal stoma to the skin, the distal colon was cleaned by means of an infusion of a physiological saline until the faecal contents were completely removed. The abdominal incision was closed in two stages (the aponeurosis and the skin). In this way, two colostomies were performed: the proximal colostomy, which served as a terminal colostomy with intestinal transit, and the second colostomy, which served as a distal stoma devoid of a faecal stream. Rats were maintained in individual cages, without application of antiseptic ointments in the surgical incision, as well as the use of bandage covering the abdominal incision. The stoma and the surgical scar were left exposed and the fecal wastes around the stoma were removed daily to allow assessment of healing between the stoma and skin. All animals were weighed daily and they did not receive analgesic, antibiotic or anti-inflammatory substances in order to not interfere with the inflammatory neutrophil infiltrate (tissue myeloperoxidase levels).

Experimental groups

Fig. 1 shows the distribution of our experimental groups. Thirty-six animals were divided randomly into three groups of 12 rats each. In the first group, the animals were subjected to an application of enemas with 0.9% saline warmed to room temperature (control group). The second and the third groups of animals (experimental groups) received daily applications of

Curcumin and diversion colitis

enemas containing 20 mL of an oily extract of curcumin (Sigma-Aldrich, St Louis, MO, USA) in two different concentrations (50 mg/kg/day and 200 mg/kg/day, respectively). In all animals, the application of intervention solutions was carried out with the aid of an infusion pump (KD Scientific Inc., Holliston, MA, USA) at a controlled infusion rate of 20 mL/min. In each of the three experimental groups, six animals were sacrificed after two weeks, and the other six after four weeks.

Sample collection

Upon completion of the pre-determined irrigation period (two or four weeks), the animals were anesthetized as described above, and the midline incision was opened again. In both groups, specimens were taken from the intra-abdominal part of the colon without a faecal stream. The removed specimen, which measured approximately 4.0 cm, was longitudinally opened through the anti-mesenteric border, fixed to a piece of cork and subjected to histological and immunohistochemical studies. After removal of the surgical specimen, the anesthetized animals were submitted to euthanasia by intracardiac infusion of lethal doses of thiopental.

Histological techniques

The fragments designated for histological study were kept in 10% formaldehyde for 48 h at room temperature to ensure proper specimen fixation. Then, the specimens were dehydrated by exposure to increasing concentrations of ethanol and were embedded in

paraffin. From each block, two 5- μ m-thick fragments were cut with the aid of a manual microtome (Leica RM 2235, Leica do Brasil Importação e Comércio Ltda., São Paulo, Brazil) for slide mounting. One slide was stained with haematoxylin-eosin (HE) and sent for a histopathological evaluation for the presence of colitis, as well as for an assessment of the degree of tissue inflammation. The second slide was intended for immunohistochemistry studies to detect the tissue expression of myeloperoxidase (MPO).

All slides were analysed using an ordinary optical microscope (Eclipse DS-50, Nikon Inc., Osaka, Japan) by a pathologist with experience in diagnosing IBD who was blinded to the origin of the material and the study objectives. Histological photographs were taken using a digital video camera (DS-Fi-50, Nikon Inc., Osaka, Japan) previously attached to the microscope body. All specimens analysed were photographed with a final magnification of 200 \times . The reading of each slide was always conducted in a histological field showing at least three intact and contiguous colonic glands. For each slide, three distinct histological fields were evaluated. The diagnosis of colitis and the assessment of the degree of tissue inflammation were determined based on histological (modified) criteria that were previously described by Akgun et al., (2005) (Table 1). The following stratification for the histological degree of tissue inflammation was adopted: 0-3, mild; 4-6, moderate; and 7-9, severe.

For the immunohistochemical study, all blocks were sectioned in 5- μ m-thick sections obtained from colon segments treated with the intervention solutions. These sections were deposited on previously salinized slides

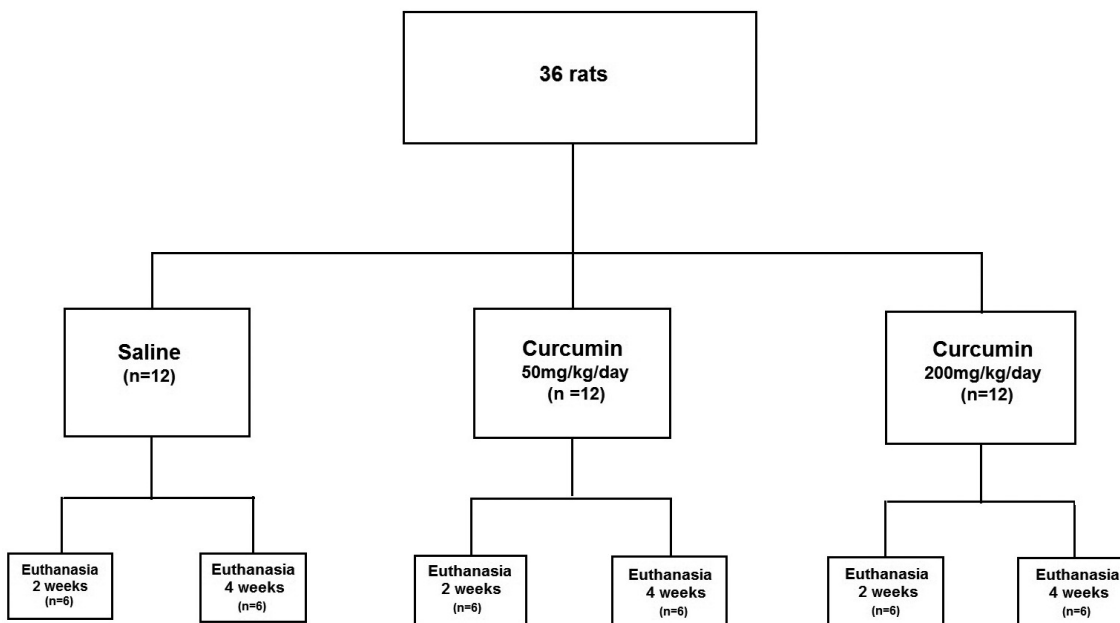


Fig. 1. Experimental groups.

identified with the number of the rat and the group to which it belonged. The slides were diaphanized and rehydrated, and antigen retrieval was performed using Trilogy solution (Cell Mark Inc., Rocklin, CA, USA). Next, the slides were rinsed with distilled water and subsequently immersed in PBS solution for 10 min before being dried with filter paper. Endogenous peroxidases were blocked using 3% hydrogen peroxide (H_2O_2) in a humidified chamber at room temperature for 10 min. Further washing was performed with PBS for 10 min. After this process, the slides were left at room temperature for 10 min and then washed with PBS again for 5 min. The primary polyclonal anti-MPO antibody (Dako do Brasil Ltda., São Paulo, Brasil) with cross-reactivity for rat protein was diluted 1:100 in saline containing bovine serum albumin (1%). All slides were coated with 100 μ L of this solution and left at room temperature for 2 h.

Following exposure to the primary antibody, the slides were rinsed twice with distilled water and twice with PBS buffer (2 min/time). Then the slides were incubated with an avidin-biotin system (secondary antibody) from the LSAB + Kit System-HRP (Dako do Brasil Ltda., São Paulo, Brazil) with a 35-min period of exposure for each reagent, and then the samples washed twice with PBS. The section processing was performed using the Liquid DAB + Substrate Kit (Dako do Brasil Ltda., São Paulo, Brazil) at a dilution of one drop of chromogen solution in 1 μ L of buffer solution. A total of 100 μ L of the chromogen was added over the sections for a period of 5 min at room temperature. After processing, the sections were washed in running water and counterstained with Harris haematoxylin for 30 s. The slides were then washed again in running water to remove excess dye. Finally, the slides were dehydrated in three baths with increasing concentrations of alcohol and two baths of xylene. The slides were then mounted with coverslips and resin.

The results of an immunostaining were considered to

be positive when a diffuse brownish colour with spots of varying intensity and a homogeneous distribution in neutrophils was observed. As recommended by the manufacturer, a negative control slide was prepared without the addition of the primary antibody, and a positive control slide was prepared using human appendix with acute appendicitis.

Computer-assisted image processing

Tissue myeloperoxidase level was quantified using a computer-assisted image processing system, which was always performed in a focal field in which there were at least six complete and contiguous colonic crypts, in samples with a magnification of 200x. The images selected were captured on a video camera that had been coupled to an optical microscope. These images were processed and analysed using the NIS-Elements 3.1 software program (Nikon Inc., Osaka, Japan) installed on a microcomputer. Using coloured histograms in an RGB system, the software determined the colour intensity based on the number of pixels in each field selected and transformed the final data into the percent expression for the analysed fields (%/fields). The final value for each field measured in the colonic segments of the three experimental groups was the mean of the values found in three different fields.

Statistical analysis

The statistical analysis of the results was performed by setting the significance level at 5% ($p < 0.05$). The data from each colon segment analysed in each experimental group were expressed as the mean values with the respective standard error and were analysed using the BioStat for Windows statistical software program (version 5.0). The Mann-Whitney U-test was used to compare the histological inflammatory grade and the tissue content of MPO in the experimental groups. To analyse the variance in MPO expression between the different experimental groups, ANOVA was used with the Newman-Keuls post-test.

Results

In the early days of postoperative, some animals showed transitional periods of piloerection, especially when handled. In the first two or three days they were quieter (with less movement) in the cage. We attribute this piloerection to the stress of handling and maybe some degree of pain. All animals, regardless of the experimental group to which they belonged, showed loss of weight between 15 and 30 g in the first four days after surgery. This weight loss was attributed to the anesthetic and surgical stress and probably the presence of pain, since analgesics and anti-inflammatories were not used. After the 5th day postoperative the animals were gaining weight gradually until the date scheduled for euthanasia (2 or 4 weeks). No animal showed surgical wound

Table 1. Variables used for stratifying the histological degree of tissue inflammation.

Variable	Score	Histological findings
Epithelial loss	0	No epithelial loss
	1	Loss of <5% of the epithelial surface
	2	Loss of 5%-10% of the epithelial surface
	3	Loss of >10% of the epithelial surface
Integrity of colon glands	0	Intact crypts
	1	Loss of <10% of colon glands
	2	Loss of 10%-20% of colon glands
	3	Loss of >20% of colon glands
Inflammatory infiltration	0	Absent
	1	Mild
	2	Moderate
	3	Severe

Modification of the system proposed by Akgun et al. (2005)

Curcumin and diversion colitis

infection, stoma dehiscence or stenosis. There were no deaths in the three experimental subgroups and replacement of animals was not necessary.

Fig. 2A shows the colonic epithelium without a faecal stream that was subjected to saline treatment for four weeks, whereas Fig. 2B shows a colon segment without a faecal stream that was irrigated with an oily extract of curcumin at a concentration of 200 mg/kg/day.

Fig. 3 shows the degree of tissue inflammation in the animals subjected to irrigation with an enema containing saline, an oily extract of curcumin at a concentration of 50 mg/kg/day and an oily extract of curcumin at a concentration of 200 g/kg/day for two or four weeks.

Fig. 4A shows the positive and negative controls and the tissue expression of MPO in the colonic epithelium without a faecal stream that was subjected to treatment with saline for four weeks. Fig. 4B shows the tissue expression of MPO in a colon segment without a faecal stream that was irrigated with the oily extract of curcumin at a concentration of 200 mg/kg/day.

Fig. 5 shows the tissue MPO level found in colon segments without a faecal stream after treatment with saline or an oily extract of curcumin (50 mg/kg/day or 200 mg/kg/day) for two or four weeks. The results showed that irrigation with curcumin at a concentration of 50 mg/kg/day or 200 mg/kg/day in colon segments

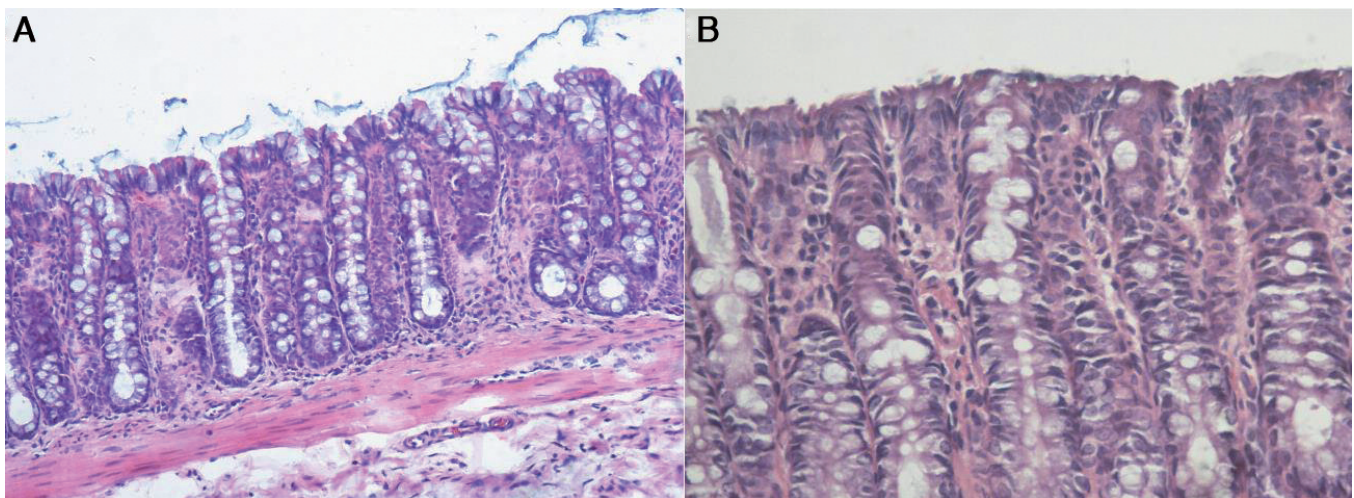


Fig. 2. A. The colonic mucosa devoid of a faecal stream subjected to enema treatment with saline for four weeks. Note the epithelial irregularity with a "brush border" appearance (HE). **B.** The colonic mucosa devoid of a faecal stream exposed to an enema with an oily extract of curcumin (200 mg/kg/day) for four weeks. The epithelial colonic surface was lined and regular (HE). A, x 200; B, x 400

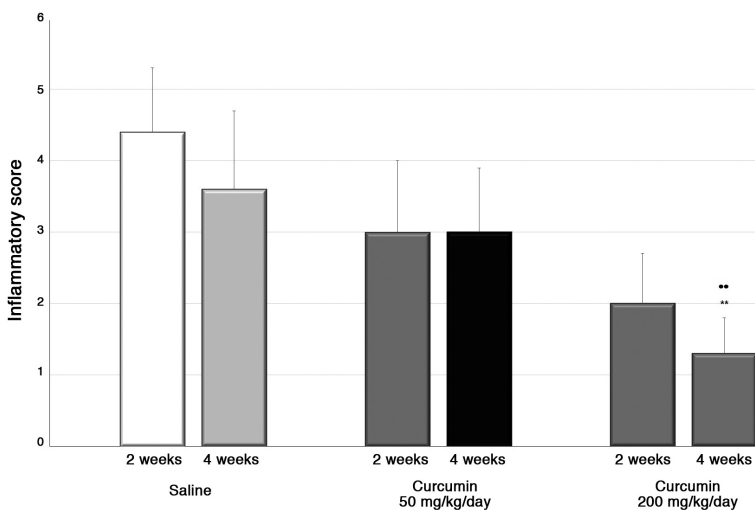


Fig. 3. The degree of inflammation in animals irrigated with enemas containing 0.9% saline, curcumin at 50 mg/kg/day and curcumin at 200 mg/kg/day for two or four weeks. **: Significant: Curcumin 200 mg/kg/day<saline (p<0.01). **: Significant: Curcumin 200 mg /kg /day<Curcumin 50 mg/kg/day) (p<0.01). Mann-Whitney test.

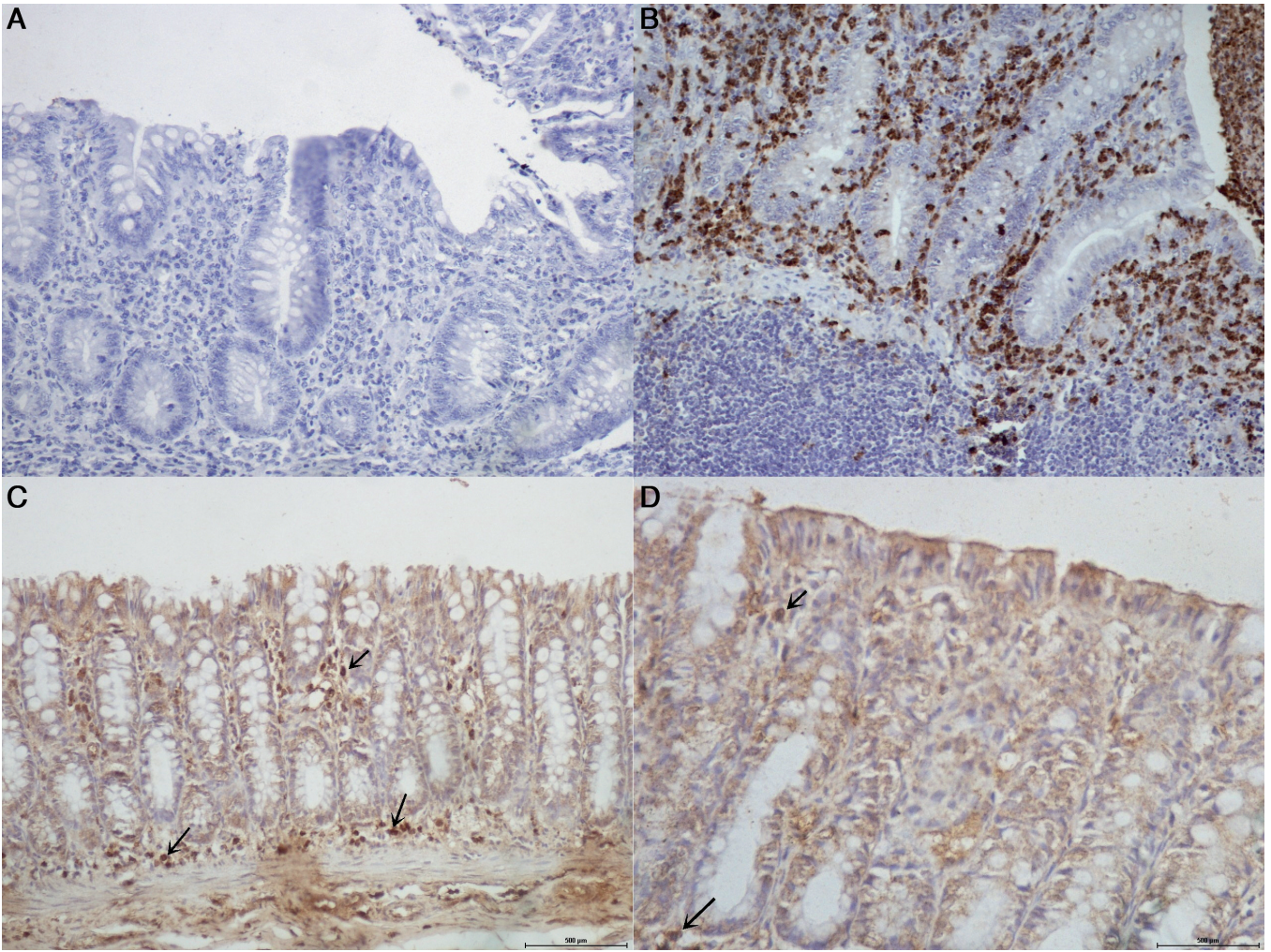


Fig. 4. **A.** Negative control. **B.** Positive control for MPO (acute appendicitis). **C.** Colonic mucosa devoid of a faecal stream subjected to irrigation with saline for four weeks with loss of the integrity of the colonic epithelium. Black arrows show the expression of MPO in neutrophils (IH-MPO). **D.** The colonic mucosa devoid of the faecal stream subjected to irrigation with an oily extract of curcumin (200 mg/kg/day) for four weeks. The colonic epithelium was still intact, and there was reduced MPO tissue expression (black arrow) (IH-MPO). A-C, x 200; D, x 400

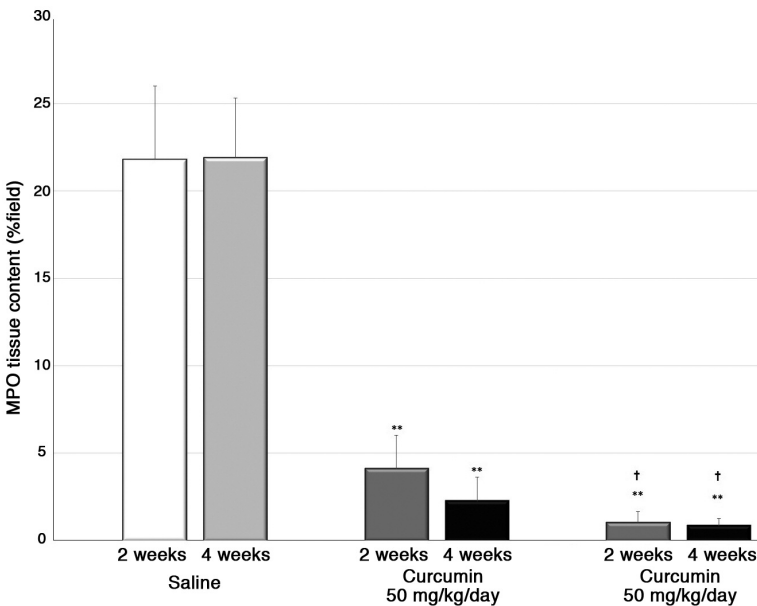


Fig. 5. The tissue contents of MPO in the control group and groups treated with an oily extract of curcumin at a concentration of 50 mg/kg/day or 200 mg/kg/day. **: Significant: Curcumin at 50 mg/kg/day and curcumin at 200 mg/kg/day < saline ($p < 0.01$); †: Significant: Curcumin at 200 mg/kg/day < curcumin at 50 mg/kg/day after both two and four weeks of intervention ($p < 0.05$). Mann-Whitney test.

devoid of a faecal stream significantly reduced the MPO level compared with animals in the saline group after both two and four weeks of treatment ($p < 0.01$).

Discussion

Curcuma longa L. (Zingiberaceae family) rhizomes have been widely used for centuries in Indian and Chinese medicine for the treatment of a variety of inflammatory conditions and other diseases (Vecchi Brumatti et al., 2014). The major active compounds present in the *Curcuma longa* rhizomes are diferuloylmethane (curcumin, 77%), demethoxycurcumin (17%), bisdemethoxycurcumin (3%), and the recently identified cyclocurcumin (<1%). Curcumin was first isolated in 1815 and obtained in crystalline form in 1870. The molecular structure of curcumin was described in 1919, which was also the year that it was first synthesized (Ali et al., 2012; Kumar et al., 2012).

Several experimental studies have shown that curcumin has diverse molecular targets, which supports the notion that curcumin influences numerous biochemical and molecular pathways (Kumar et al., 2012). Among its targets are transcription factors, growth factors and their receptors, cytokines, enzymes, and genes that regulate cell proliferation and apoptosis (Kumar et al., 2012). Curcumin also exhibits strong anti-inflammatory and antioxidant activities that protect against oxidative cell injury by inhibiting lipid degradation, lipid peroxidation and cytolysis (Zeng et al., 2013; Lang et al., 2015).

These numerous mechanisms of action of curcumin seem to confer a broad spectrum of pharmacological actions, including antitumor, anti-inflammatory, and antioxidant effects. The administration of curcumin downregulates the expression of proinflammatory cytokines, such as tumour necrosis factor (TNF- α), interleukin (IL)-1, IL-2, IL-6, IL-8, IL-12, and chemokines, most likely through inactivation of nuclear transcription factor kappa B (NF- κ B). Likewise, there have been reports that curcumin decreases the inflammation associated with experimental colitis, leading to a substantial attenuation of the rise in MPO activity, which is an established marker of inflammatory cells (mainly polymorphonuclear leukocytes), and TNF- α . MPO activity is frequently used as an index of the inflammatory response in the mucosa, and its activity in the colon is linearly related to neutrophil infiltration (Ammon and Wahl, 1991; Akgun et al., 2005). Neutrophilic infiltration represents an important source of ROS, which are cytotoxic due to their cross-linking of proteins, lipids and nucleic acids, which causes cellular damage (Kruidenier et al., 2003).

Oxidative stress plays a major role in the pathogenesis of various diseases including myocardial ischaemia, cerebral ischaemia-reperfusion injury, haemorrhage, shock, neuronal cell injury, hypoxia, IBD and cancer. In inflammatory processes of the colonic mucosa, ROS are produced as part of the host response

to kill bacteria or damage viruses. However, ROS are produced at excessive levels, and their deleterious effects are assumed to contribute to barrier dysfunction, as indicated by a disruption of the composition of the main components of the colonic epithelium (mucous layer, tight junctions and adherens junctions), which are accompanied by functional changes (Kruidenier et al., 2003; John et al., 2011). ROS are also able to oxidize membrane phospholipids, leading to the formation of lipid radicals that can react with molecular oxygen to form peroxy radicals, and these ROS can further oxidize lipids in a chain reaction called lipid peroxidation (John et al., 2011).

Recent studies in experimental models of DC have shown that oxidative stress is related to an initiation process that leads to the breakage of different lines of defence that form the epithelial barrier of the colonic epithelium (Nonose et al., 2009; Martinez et al., 2010a,b; Kadri et al., 2013). It has been shown that the exposure of the colonic mucosa to H₂O₂, a strong oxidant, can cause damage similar to that described in different forms of colitis (Desai and Orledge, 2010; Marques et al., 2010). Conversely, the application of enemas containing substances with antioxidant activity in colon segments without a faecal stream proved to be effective in preventing the development of DC (Caltabiano et al., 2011; Cunha et al., 2011).

Considering that oxidative stress is related to the molecular mechanisms that cause DC, the use of natural substances with antioxidant properties seems to represent a viable alternative for the treatment of the disease. The easy bioavailability, low incidence of side effects and low cost of these substances make it interesting to evaluate their therapeutic potential. Curcumin was previously shown to be a potent scavenger of a variety of ROS, including superoxide anion radicals, hydroxyl radicals and nitrogen dioxide radicals (Reddy and Lokesh, 1994; Samuhasaneeto et al., 2009). It was also shown that curcumin can protect against oxidative cell injury by inhibiting lipid degradation, lipid peroxidation and cytolysis in different animal models (Samuhasaneeto et al., 2009). A study that evaluated an experimental model of DSS induced-colitis showed that the anti-inflammatory effects of curcumin involve a reduction in MPO activity and a reduction in the number of infiltrating neutrophils, as well as reduced expression of the IL-1 β (Liu et al., 2013).

The results of the present study seem to confirm these findings. To the best of our knowledge, we have herein provided the first evidence that the daily application of enemas containing an oily extract of *Curcuma longa* effectively prevents the development of the inflammatory changes described in DC. We found that animals subjected to the daily application of curcumin (at either concentration used) showed less epithelial loss, with the preservation of the regularity of the colonic luminal epithelium. In contrast, the animals receiving saline lost cells from the epithelial surface,

which was irregular and showed an appearance similar to a "brush border".

When we compared the changes in the morphology of the colonic glands, we verified that the animals in the control group showed irregular colonic glands, with the highest concentration of mucus within the goblet cells; in some locations, there was complete loss of the apical portion of the glands. In the animals subjected to intervention with an oily extract of curcumin, the colonic glands were aligned and juxtaposed. When we analysed the presence of neutrophils in the colonic mucosa, we found that animals subjected to intervention with curcumin presented with less neutrophilic infiltration. When epithelial loss, changes in colonic gland architecture, and neutrophils that were assessed by a histological study were assessed together with the aim of stratifying the findings based on the overall inflammatory score, we found that irrigation for four weeks with curcumin led to a significant reduction in inflammatory scores. These findings suggest that the improvement in inflammation was related to the use of curcumin, with better results observed when it was administered for a longer period of time and at a higher dose. These results were consistent with the results of other studies showing that there is increased production of ROS with the time of diversion of the faecal stream (Nonose et al., 2009; Martinez et al., 2010a,b; Kadri et al., 2013).

Neutrophil infiltration represents one of the different mechanisms to increase the production of ROS that act as cytotoxic agents by cross-linking proteins, lipids and nucleic acids, thus causing cellular damage (Holma et al., 2001; Salh et al., 2003; Goel et al., 2008). A previous study showed that in colonic mucosa devoid from faecal stream the overproduction of ROS are related to increase in MPO activity (Longatti et al., 2010). The results of the present study show that the application of enemas containing curcumin can reduce the intensity of neutrophil infiltrate measured by tissue level of MPO. When the infiltration of neutrophils was assessed based on the expression and tissue content of MPO, we observed a significant reduction after treatment with curcumin for two weeks, regardless of the concentration used. This reduction was more evident when the higher concentration was applied for a longer period of time. These results suggest that curcumin is effective for the treatment of DC and that it can reduce the inflammation in colonic mucosa devoid from the faecal stream. The marked reduction of the inflammatory score in colon tissue sections irrigated with curcumin is correlated with the reduction in the MPO tissue content. Different mechanisms can increase the production of ROS in colon lumen, such as the presence of bacteria as well as substances derived from cellular metabolism (Jones et al., 2012). Studies have shown that the simple derivation of the intestinal tract by modifying the metabolism of colonic epithelial cells also increases ROS production (Martinez et al., 2010b; Caltabiano et al., 2011). Although in this study the tissue levels of ROS have not

been measured, it is possible that the effects of curcumin may be related to its anti-inflammatory and antioxidant activities previously demonstrated by other authors (Samuhasaneeto et al., 2009; Trujillo et al., 2016).

Conclusion

The results of this study confirm the anti-inflammatory effects of curcumin and suggest that the topical application of the oil extract of curcumin may represent a new strategy for the treatment of DC.

References

- Aggarwal B.B., Sundaram C., Malani N. and Ichikaw H. (2007). Curcumin: the Indian solid gold. *Adv. Exp. Med. Biol.* 595, 1-75.
- Akgun E., Caliskan C., Celik H.A., Ozutemiz A.O., Tuncyurek M. and Aydin H.H. (2005). Effects of N-acetylcysteine treatment on oxidative stress in acetic acid-induced experimental colitis in rats. *Int. Med. Res.* 33, 196-206.
- Ali T., Shakir F. and Morton J. (2012). Curcumin and inflammatory bowel disease: biological mechanisms and clinical implication. *Digestion* 85, 249-255.
- Ammon H.P. and Wahl M.A. (1991). Pharmacology of *Curcuma longa*. *Planta Medica.* 57, 1-7.
- Caltabiano C., Máximo F.R., Spadari A.P., da Conceição Miranda D.D., Serra M.M., Ribeiro M.L. and Martinez C.A. (2011). 5-aminosalicylic acid (5-ASA) can reduce levels of oxidative DNA damage in cells of colonic mucosa with and without fecal stream. *Dig. Dis. Sci.* 56, 1037-1046.
- Cunha F.L., Silva C.M., Almeida M.G., Lameiro T.M., Marques L.H., Margarido N.F. and Martinez C.A. (2011). Reduction in oxidative stress levels in the colonic mucosa without fecal stream after the application of enemas containing aqueous *Ilex paraguariensis* extract. *Acta Cir. Bras.* 26, 289-296.
- Desai Y. and Orledge J. (2010). Chemical colitis from a hydrogen peroxide enema. *J. Miss. State Med. Assoc.* 51, 314-316.
- Glotzer D.J., Glick M.E. and Goldman H. (1981). Proctitis following diversion of fecal stream. *Gastroenterology* 80, 438-441.
- Goel A., Kunnumakkara A.B. and Aggarwal B.B. (2008). Curcumin as "Curcumin": from kitchen to clinic. *Biochem. Pharmacol.* 75, 787-809.
- Holma R., Salmenperä P., Riutta A., Virtanen I., Korpela R. and Vapaatalo H. (2001). Acute effects of the cys-leukotriene-1 receptor antagonist, montelukast, on experimental colitis in rats. *Eur. J. Pharmacol.* 429, 309-318.
- John L.J., Fromm M. and Schulzke J.D. (2011). Epithelial barriers in intestinal inflammation. *Antioxid. Redox Signal.* 15, 1255-1270.
- Jones R.M., Mercante J.W. and Neish A.S. (2012). Reactive oxygen production induced by the gut microbiota: pharmacotherapeutic implications. *Curr. Med. Chem.* 19, 1519-1529.
- Kadri C.J., Pereira J.A., da Silva C.M., Nonose R., Nascimento E.F., Jácomo A.L. and Martinez C.A. (2013). E-cadherin expression in colonic mucosa with and without fecal stream. *J. Invest. Surg.* 26, 72-79.
- Kruidenier L., Kuiper I., Lamers C.B. and Verspaget H.W. (2003). Intestinal oxidative damage in inflammatory bowel disease: Semi-quantification, localization, and association with mucosal antioxidants. *J. Pathol.* 201, 28-36.

Curcumin and diversion colitis

- Kumar S., Ahuja V., Sankar M.J., Kumar A. and Moss A.C. (2012). Curcumin for maintenance of remission in ulcerative colitis. *Cochrane Database Syst. Rev.* 10, CD008424.
- Lang A., Salomon N., Wu J.C., Kopylov U., Lahat A., Har-Noy O., Ching J.Y., Cheong P.K., Avidan B., Gamus D., Kaimakliotis I., Eliakim R., Ng S.C. and Ben-Horin S. (2015). Curcumin in combination with mesalamine induces remission in patients with mild-to-moderate ulcerative colitis in a randomized controlled trial. *Clin. Gastroenterol. Hepatol.* 13, 1444-1449.
- Liu L., Liu Y.L., Liu G.X., Chen X., Yang K., Yang Y.X., Xie Q., Gan H.K., Huang X.L. and Gan H.T. (2013). Curcumin ameliorates dextran sulfate sodium-induced experimental colitis by blocking STAT3 signaling pathway. *Int. Immunopharmacol.* 17, 314-320.
- Longatti T.S., Acedo S.C., de Oliveira C.C., Miranda D.D., Priolli D.G., Ribeiro M.L., Gambero A. and Martinez C.A. (2010). Inflammatory alterations in excluded colon in rats: a comparison with chemically induced colitis. *Scand. J. Gastroenterol.* 45, 315-324.
- Marques L.H.S., Silva C.M.G., Lameiro T.M.M., Almeida M.G., Cunha F.L., Pereira J.A. and Martinez C.A.R. (2010). Evaluation of lipid peroxidation levels on mucosa colonic cells after application of hydrogen peroxide in enemas. Experimental study in rats. *Rev. Bras. colo-proctol.* 30, 272-280.
- Martinez C.A.R., Nonose R., Spadari A.P.P., Máximo F.R., Priolli D.G., Pereira J.A. and Margarido N.F. (2010a). Quantification by computerized morphometry of tissue levels of sulfomucins and sialomucins in diversion colitis in rats. *Acta Cir. Bras.* 25, 231-240.
- Martinez C.A.R., Ribeiro M.L., Gambero A., Miranda D.D.C., Pereira J.A. and Nadal S.R. (2010b). The importance of oxygen free radicals in the etiopathogenesis of diversion colitis in rats. *Acta Cir. Bras.* 25, 387-395.
- Martinez C.A.R., Fabris F.M., Silva C.M.G., Rodrigues M.R., Sato D.T., Ribeiro M.L. and Pereira J.A. (2012). Oxidative stress and changes in the content and pattern of tissue expression of β -catenin protein in diversion colitis. *J. Coloproctol. (Rio J.)* 32, 343-358.
- Martinez C.A., de Campos F.G., de Carvalho V.R., de Castro Ferreira C., Rodrigues M.R., Sato D.T. and Pereira J.A. (2015). Claudin-3 and occludin tissue content in the glands of colonic mucosa with and without a fecal stream. *J. Mol. Histol.* 46, 183-194.
- Nonose R., Spadari A.P.P., Priolli D.G., Máximo F.R., Pereira J.A. and Martinez C.A.R. (2009). Tissue quantification of neutral and acid mucins in the mucosa of the colon with and without fecal stream in rats. *Acta Cir. Bras.* 24, 267-275.
- Oliveira-Neto J.P. and Aguilar-Nascimento J.E. (2004). Intraluminal irrigations with fibres improves inflammation and atrophy in diversion colitis. *Nutrition* 20, 197-199.
- Reddy A.C. and Lokesh B.R. (1994). Studies on the inhibitory effects of curcumin and eugenol on the formation of reactive oxygen species and the oxidation of ferrous iron. *Moll. Cell. Biochem.* 137, 1-8.
- Roediger W.E. and Nance S. (1990). Selective reduction of fatty acid oxidation in colonocytes: correlation with ulcerative colitis. *Lipids* 25, 646-652.
- Salh B., Assi K., Templeman V., Parhar K., Owen D., Gómez-Muñoz A., and Jacobson K. (2003). Curcumin attenuates DNB-induced murine colitis. *Am. J. Physiol. Gastrointest. Liver Physiol.* 285, G235-243.
- Samuhasaneeto S., Thong-Ngam D., Kulaputana O., Suyasunanont D. and Klaikeaw N. (2009). Curcumin decreased oxidative stress, inhibited NF- κ B activation, and improved liver pathology in ethanol-induced liver injury in rats. *J. Biomed. Biotechnol.* 2009, 981963.
- Tham D.M., Within J.C. and Cohen H.J. (2002). Increased expression of extracellular glutathione peroxidase in mice with dextran sodium sulfate-induced experimental colitis. *Pediatric. Res.* 51, 641-646.
- Trujillo J., Molina-Jijón E., Medina-Campos O.N., Rodríguez-Muñoz R., Reyes J.L., Loredó M.L., Barrera-Oviedo D., Pinzón E., Rodríguez-Rangel D.S. and Pedraza-Chaverri J. (2016). Curcumin prevents cisplatin-induced decrease in the tight and adherens junctions: relation to oxidative stress. *Food Funct.* 7, 279-293.
- Vecchi Brumatti L., Marcuzzi A., Tricarico P.M., Zanin V., Girardelli M. and Bianco A.M. (2014). Curcumin and inflammatory bowel disease: potential and limits of innovative treatments. *Molecules* 19, 21127-21153.
- Zeng Z., Zhan L., Liao H., Chen L. and Lv X. (2013). Curcumin improves TNBS-induced colitis in rats by inhibiting IL-27 expression via the TLR4/NF- κ B signalling pathway. *Planta Med.* 79, 102-109.

Accepted May 30, 2016