

Effects of low dose of tibolone on steroid receptors and Bcl-2 on the postmenopausal endometrium

Benedito Fabiano Reis^{1,2}, Sonia Maria Rolim R. Lima¹, Gustavo Maximiliano D. Silva¹, Antonio Marcos C. Francisco², Lyliana Coutinho R. Barbosa², Silvania C. Vieira Archangelo² and Rogerio M. Grande³

¹Department of Gynecology and Obstetrics, Santa Casa of Sao Paulo Medical School, Sao Paulo, ²Department of Gynecology and Obstetrics and ³Department of Pathology, Vale do Sapucaí University, Pouso Alegre, Minas Gerais, Brazil

Summary. Objective: A prospective randomized controlled trial was conducted to evaluate the effect of low dose of tibolone on the histology, expression of estrogen (ER) and progesterone receptors (PR) and Bcl-2 protein, in endometrium of postmenopausal women.

Method: Forty postmenopausal women consented to treatment and were allocated into two groups of 20 women: Group 1 (Control) without hormone replacement therapy (HRT); Group 2 (Tibolone) treatment at the dose of 1.25 mg/day of oral tibolone administered for a 24-week period. The effect on the endometrium was assessed by histology and the apoptosis marker Bcl-2. The immunoeexpression of ER and PR were also measured.

Results: Tibolone group showed higher expression of ER, PR and Bcl-2 protein in glandular epithelium and stroma compared to control group.

Conclusion: Tibolone in a daily dose of 1.25 mg during 24 weeks demonstrated endometrial action that resulted in low proliferation and was shown to lead to atrophic endometrium. It had favorable effects on the postmenopausal endometrium due to its higher immunoeexpression of PR and Bcl-2 protein in endometrial glandular epithelium, thereby creating a balance between pro-apoptotic and anti-apoptotic actions.

Key words: Menopause, Endometrium, Steroid receptors, Bcl-2, Tibolone

Introduction

Tibolone (Tib), one of the 19-nor synthetic steroids [(7a, 17a)-17OH-7-methyl-19-norpregn-5(10)-en-20-yn-3-one] has been used for hormone replacement therapy (HRT) in postmenopausal women (de Villiers et al., 2013). Tib is a selective tissue estrogenic activity regulator that is effective in the prevention of osteoporosis and treatment of climacteric symptoms and does not stimulate endometrial and breast tissue (Modelska and Cummings, 2002; Kloosterboer, 2004). After oral administration, tibolone is bioconverted in the intestine and the liver to metabolites that have estrogenic (3 α and 3 β hydroxytibolone) and progestogenic/androgenic (Δ 4 isomer) properties (Gooyer et al., 2001, 2003).

Bcl-2 promotes cell survival by inhibiting adapters needed for the activation of proteases that dismantle the cell. Thus, the apoptotic signals, the balance between Bcl-2 family members plays a key role in determining whether apoptosis or cell survival is a final outcome in postmenopausal endometrium (Rogers et al., 2000; Gokaslan et al., 2003; Lima et al., 2011).

The objective of this study was to evaluate the effects of low dose of tibolone on the histology and immunolocalization of progesterone and estradiol receptors, as well as of the Bcl-2 protein, in postmenopausal endometrium.

Materials and methods

A randomized, prospective and double-blind study was carried out at Vale do Sapucaí University, Minas

Gerais, and Santa Casa of Sao Paulo Medical School, Sao Paulo, both in Brazil. Protocol 598.391/2007 was approved by the “Irmandade da Santa Casa de Misericordia de Sao Paulo”, Sao Paulo, Brazil, from January 2009 to January 2013, Registration number from “Plataforma Brazil” was CAAE: 10979112.1.3001.5479. All women involved in the study provided written informed consent according to the regulations of the participating institution. The study was conducted according to Good Clinical Practice, in full compliance with the Declaration of Helsinki plus revisions.

Healthy postmenopausal women, amenorrhic for 1-10 years, aged 45-60 years. The postmenopausal status was confirmed by follicle stimulating hormone levels ≥ 30 mIU/mL. Inclusion criteria were an intact uterus, a washout period of 8 weeks for oral estrogens with or without progestogens, androgens, or selective estrogen receptor modulators (SERMs), four weeks for transdermal or local sex steroids. The exclusion criteria were: neoplastic, metabolic and infectious diseases, a uterine size greater than that consistent with a 12-week gestation, any abnormality on bimanual pelvic examination, concomitant use of any hormonal drug, body mass index (BMI) >30 kg/m², cigarette smoking and an endometrial thickness >5 mm or the presence of any endometrial abnormalities on transvaginal ultrasound (TV-US). No subjects had present or past history of venous thrombosis, cerebrovascular or cardiovascular disease, and women were excluded if they had any condition that could alter the pharmacokinetics or hypersensitivity to tibolone.

Of the 60 women initially evaluated, 15 did not meet the inclusion and exclusion criteria, while five refused to participate, giving a final total of 40 patients for inclusion in the study (Fig. 1). The sample size was determined by a biostatistician according to previously published studies (Klaassens et al., 2006; Lima et al., 2011).

The women were allocated into two groups: Group I: control group - 20 patients (no hormonal treatment); Group II: 20 patients - tibolone 1.25 mg (low dose) was administered daily. Tib was purchased from Biolab™, Brazil. The duration of the treatment was 24 weeks. Randomization was done with the aid of computer software in order to prevent bias in the selection process. The endometrial thickness was determined by TV-USG at study baseline and after 24 weeks of treatment in all women. Scans were performed by the same experienced operator with a real-time scanner, Hitachi™ 405 ultrasound system equipped with a 5.0-MHz vaginal transducer. An endometrial thickness ≤ 4 mm was interpreted as not supporting a diagnosis of endometrial cancer (Doren et al., 1999; Affinito et al., 2001; Huber et al., 2002).

Endometrial biopsy and sampling were performed at the end of the treatment course using a Pipelle curette de Cornier, placed high into the upper fundus of the uterus. An aliquot of the endometrial sample was pushed from the pipelle into a polypropylene vial (Wagaarachchi and Sirisena, 2000). The vial was capped, immediately frozen, and then stored at -20°C until shipping in dry ice for measurement of PR and ER receptors as well as Bcl-

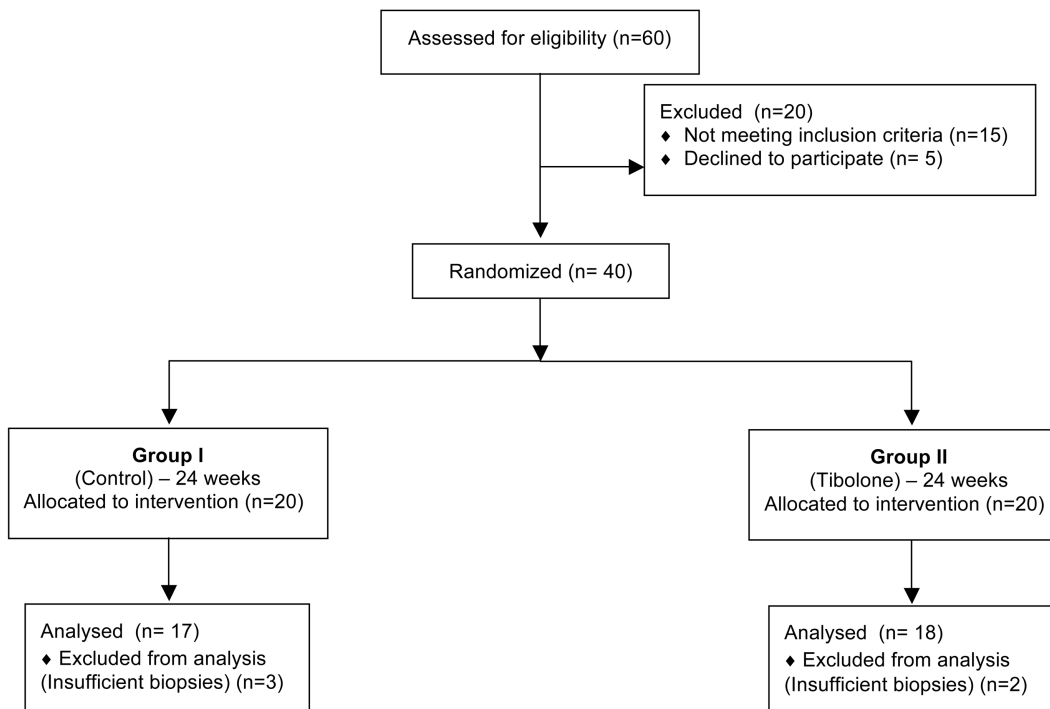


Fig. 1. Study flowchart illustrating enrollment, number of women in the intent-to-treat population, randomization into treatment groups, and follow-up of study participants.

Effects of tibolone on the endometrium

2 protein. The remaining endometrial tissue was fixed in 10% neutral buffered formalin for 6-48 h and then processed into paraffin blocks.

Histological and immunohistochemical assessment

Histology classification was carried out by two pathologists who made a blind reading of different tissue sections of the same block-sample. After staining with hematoxylin/eosin and Schiff Periodic Acid (PAS), each specimen was classified into: tissue insufficient for diagnosis, atrophic and/or inactive endometrium, proliferative or weakly proliferative endometrium and progesterogenic (Mutter and Ferenczy, 2002).

Immunohistochemical detection of Bcl-2 protein was performed after antigen retrieval and blocking of non-specific sites with normal serum using the Avidin/Biotin Blocking kit (Vector Laboratories, Inc, Burlingame, California, USA), the sections were incubated overnight at 4°C with anti-Bcl-2 mouse monoclonal antibody (1:100, Clone 124, DAKO, Denmark). The tissue-bound antibody was incubated for 30 min at room temperature with the Envision System. Staining was visualized by use of Envision (Kit N1587, DAKO, Denmark). The cellular staining pattern for this antibody is cytoplasmic. The presence of ER and PR was detected by the technique described previously (Campaner and Longo Galvão, 2009). The primary antibodies used were anti-human PR (Ab-8 cocktail; Neomarkers, Fremont, CA) and ER (Clone 1D5, DAKO, Denmark) mouse monoclonal antibodies. The cellular staining patterns for these antibodies are nuclear. A breast cancer specimen was used as a positive control for the steroid receptors. Examinations and photography were performed using an Axioskop 40 - Zeiss light microscope equipped with a Canon™ D30 digital camera (Tokyo, Japan) and video monitor (LG 14”

LCD) according to the procedures of the Pathology Department from Santa Casa of Sao Paulo Medical School, Sao Paulo, Brazil (Campaner and Longo Galvão, 2009).

The morphometric technique for immunohistochemistry quantification was done with the aid of a Neubauer graduated chamber (Smith-Bindman et al., 1998; Campaner and Longo Galvão, 2009; Lima et al., 2011). The number of Bcl-2-positive cells and immunoreactivity for PR and ER expression was quantified manually by two trained observers, blinded to the experiment, and evaluated separately for glandular and stromal cells. The immunohistochemical staining index (numerical density) was defined as the mean number of positive immunoreaction cells per mm², calculated in 10 different fields.

Statistical analysis

Statistical analysis was performed using the Statistix Package™ (Statistical Power for Microsoft Excel™ version 1.8). Differences in demographic parameters, immunohistochemical staining index of ER, PR and Bcl-2 protein expression (numerical density), as well as baseline and treatment end-point endometrial thickness, were analyzed by the paired Student's t-test in the different groups. The relationships between ER, PR and Bcl-2 protein expression in stroma and glandular epithelium were analyzed using Spearman's test. Statistical significance was set at p<0.05. Data were expressed as mean + standard deviation (SD).

Results

The treatment was well tolerated. No relevant drug-related, adverse events or bleeding were observed during the study. There were no significant differences among the groups in terms of age, BMI or time since menopause at study baseline (Table 1). Ultrasonographic measurements of endometrial thickness taken at baseline

Table 1. Clinical characteristics of postmenopausal women at study baseline and end-point by Group. Data expressed as mean ± standard deviation or n.

	Group I (Control) (n: 20)	Group II (Tib) (n: 20)	p
Age (years)	50.81±2.55	49.78±2.19	0.19
Time since menopause (years)	3.01±1.97	3.11±2.20	0.88
Body mass index (kg/m ²)			
Time 0 (Baseline)	27.63±2.71	26.97±2.58	0.07
Endometrial thickness (mm)			
Time 0 (Baseline)	3.36±1.2	3.86±0.90	0.01
After 24 weeks (End-point)	3.46±0.84	3.77±0.92	0.02
Histological classification (n)			
Proliferative	2 (10%)	3 (15%)	0.66
Atrophic	15 (75%)	15 (75%)	1
Insufficient	3 (15%)	2 (10%)	0.66

Tib: 1.25 mg Tibolone. *P<0.05 (Student's t-test).

Table 2. Immunohistochemical parameter quantification (numerical density) of Groups I and II. Values expressed as mean ± standard deviation (cells/mm²).

	Group I (Control)		Group II (Tib)		p*
	cell/mm ²	SD	cell/mm ²	SD	
ER†					
Glandular epithelium	158.32	53.71	740.54	291.78	0.000
Stroma	106.38	50.18	460.40	192.63	0.000
PR‡					
Glandular epithelium	321.65	114.86	657.21	201.87	0.000
Stroma	110.14	70.96	293.14	150.19	0.000
Bcl-2					
Glandular epithelium	449.94	186.81	997.64	313.99	0.000
Stroma	207.13	112.28	347.52	166.42	0.006

*: p<0.05 (Student's t Test). †ER: Estrogen Receptor. Tib: 1.25 mg Tibolone. ‡PR: Progesterone Receptor.

and after treatment detected no significant differences between the groups in average endometrial thickness (Table 1).

Endometrial histology biopsies were successfully performed in 40 out of the 40 women at treatment endpoint, with insufficient endometrial sampling for five women (three from Group I and two from Group II). The most frequent category in both groups was atrophic endometrium and the histological classification by group is summarized in Table 1.

Results of the immunohistochemical and morphometric studies of postmenopausal endometrium in Groups I and II are shown in Table 2 and 3, and they were quantified in 35 out of the 40 biopsies tested. Analysis was carried out utilizing the immunohistochemical staining index (numerical density) in tissue slides.

Discussion

In the present study, the effects of HRT with 1.25 mg tibolone continuously for 24 weeks on endometrial thickness, proliferation and immunoreexpression of ER, PR and Bcl-2 in postmenopausal endometrium, was assessed. No patients in the study period showed uterine bleeding or uterus and breast cancer (Doren et al., 1999). The sonographic findings revealed no endometrial stimulation and showed that endometrial thickness did not exceed five millimeters. These observations are in agreement with results of the studies by Doren et al. (1999), Huber et al. (2002) and Morais-Socorro et al. (2012). After six months of follow up, all women underwent endometrial biopsy with the Pipelle curette (Wagaarachchi and Sirisena, 2000; Elsandabesee and Greenwood, 2005) and the endometrium showed atrophic in 75%, proliferative in 15% and insufficient samples in 2%. It can be explained by the fact that keeping the endometrium atrophic is one of the

mechanisms of $\Delta 4$ isomer to adequately counteract the proliferative effect of 3α and 3β hydroxy-tibolone metabolites and these findings are in agreement with Sitruk-Ware (2004) and Szlendak-Sauer et al. (2008).

Pantaleão et al. (2009) evaluated the effect of long-term use of tibolone on the morphology of the endometrium of castrated female rats and concluded that high doses of tibolone, given for 20 weeks, have an estrogenic effect which can be dose-dependent, causing proliferation in the endometrium and changes in cell differentiation (squamous metaplasia), but do not lead to hyperplasia. This fact was similar in our study, however we used a low-dose of tibolone (1.25 mg/day), since it had been proven that the lowest effective dose produces less side effects (Modelska and Cummings, 2002).

We found that progesterone receptors in tibolone group presented higher immunoreexpression in both glandular epithelium and stroma compared to the control group, these findings are in agreement with the study Klaassens et al. (2006), but differs in ER immunostaining, since our tibolone group showed a significant difference in both glandular epithelium and stroma compared to the control group (Table 2).

Disturbances in the regulation of apoptosis and proliferation can contribute to endometrial carcinogenesis, and this balance must be maintained during HRT (Greene et al., 1986; Borner, 2003; Dahmoun et al., 2004). Bcl-2 oncoprotein product of the gene, located on chromosome 18, is known to block physiologically programmed cell death and prolong cell survival. Wide variations in positivity rates for bcl-2 in invasive carcinoma have been described, ranging from 25% to 85.7% (Zheng et al., 1996).

We found that Bcl-2 protein was significantly higher in both stroma ($p=0.000$) and glandular endometrium ($p=0.006$) of Group II (Tib) samples compared to Group I (Control) samples. But these observations differed from Klaassens (2006) study, because the antiapoptosis marker Bcl-2 in Tibolone treatment did not resulted in increased staining in glandular and stromal cells, these could be justified by the technique that was performed on the basis of percentage of positive cells as well as the intensity of staining (Campaner and Longo Galvão, 2009).

Regarding the comparison between glandular epithelium and stroma in the different groups: a greater immunostaining of ER in glandular epithelium of Group I ($p=0.006$) and Group II ($p=0.04$), on the other hand a higher PR expression was found on glandular epithelium in Group I ($p=0.000$). And when we analyzed the immunoreactivity of Bcl-2, it was found to have a higher expression in the glandular epithelium of Group I ($p=0.000$). This demonstrates the importance of considering the endometrium not as a single histological tissue, but as glandular epithelium and the stroma. Klaassens et al. (2006) found no significant difference in immunostaining of ER and PR in the stroma and glandular epithelium in six women studied, findings different from ours, perhaps by the small number of

Table 3. Immunohistochemical quantification reported as mean \pm standard deviation (cells/mm²) of ER, PR and Bcl-2 comparing stroma and glandular epithelium of postmenopausal women in Groups I and II after 24 weeks.

Parameter	Group	Cell type (cel/mm ²)		P*	r**
		Glandular	Stroma		
ER+	I	158.32 (53.71)	106.38 (50.18)	0.006	0.30
	II	740.54 (291.78)	460.40 (192.63)	0.046	0.47
PR++	I	321.65 (114.86)	110.14 (70.96)	0.000	0.82
	II	657.21 (210.87)	293.14 (150.19)	0.056	0.46
Bcl-2	I	449.93 (186.81)	207.13 (112.28)	0.000	0.86
	II	997.60 (313.99)	347.50 (166.40)	0.151	0.35

*: $p < 0.05$ (Student t Test). + ER: Estrogen receptor. **: $r = -1$ a 1 (Spearman coefficient). ++ PR: Progesterone receptor. Group I: Control. Group II: Tibolone.

cases studied.

Hyperplasia and endometrial cancer were not observed in either of the treatment groups. Thus, both estrogen and progesterone regulate apoptosis in the endometrium, since it is negatively correlated with the serum concentration of estrogen in the proliferative phase (Mosselman et al., 1996; Vaskivuo et al., 2002; Dahmoun et al., 2004). According to observations by Gokaslan et al. (2003), who measured apoptosis in endometrium of 2.5 mg/day tibolone-treated women compared with nontreated women and failed to show regulation of apoptosis by tibolone, because tibolone treatment did not affect Bcl-2 expression. However, our results contrast with these findings, showing changes in Bcl-2 immunoreactivity with tibolone use in both stroma and glandular epithelium, perhaps this finding is explained by the sensitivity of our immunohistochemical technique (Campaner and Longo Galvão, 2009).

In conclusion, our findings suggested that 24 weeks of 1.25 mg/day of tibolone treatment resulted in low proliferation and was shown to lead to atrophic endometrium. The tibolone group showed higher expression of estrogen and progesterone receptors and Bcl-2 protein in both stroma and glandular epithelium compared to the control group. Tibolone first displays a more estrogenic mode of action, which becomes increasingly counterbalanced by the induction of its progestagenic properties, thereby creating a balance between pro-apoptotic and anti-apoptotic actions. Limitations of this study include the relatively short-term assessment of the safety data and patients' samples are low. Long-term outcomes now need to be assessed over a longer period of time to confirm the mechanisms of endometrial action of tibolone.

Acknowledgements. The Pathology Department from Santa Casa of Sao Paulo Medical School, Sao Paulo, Brazil and the Pathology Department from Vale do Sapucaí University, Pouso Alegre, Brazil, both for help and assistance.

Conflict of interest: The authors report no conflicts of interest. The authors alone are responsible for the content and writing of this paper.

Source of funding: none.

References

- Affinito P., Palomba S., Sammartino A., Bonifacio M. and Nappi C. (2001). Ultrasonographic endometrial monitoring during continuous-sequential hormonal replacement therapy regimen in postmenopausal women. *Maturitas* 39, 239-244.
- Borner C. (2003). The Bcl-2 family: sensors and checkpoints for life or death decisions. *Mol. Immunol.* 39, 615-647.
- Campaner A.B. and Longo Galvão M.A. (2009). Application of an easy and useful morphometric technique for immunohistochemistry counting. *Gynecol. Oncol.* 112, 280-283.
- Dahmoun M., Odmark I.S., Risberg B., Karlsson M.G., Pavlenko T. and Backstrom T. (2004). Apoptosis, proliferation and sex steroid receptors in postmenopausal endometrium before and during HRT. *Maturitas* 49, 114-123.
- de Villiers T.J., Gass M.L., Haines C.J., Hall J.E., Lobo R.A., Pierroz D.D. and Rees M. (2013). Global Consensus Statement on menopausal hormone therapy. *Maturitas* 74, 391-393.
- Doren M., Rubig A., Coelingh B.H.J. and Holzgreve W. (1999). Impact on uterine bleeding and endometrium thickness: tibolone compared with continuous combined estradiol and norethisterone acetate replacement therapy. *Menopause* 6, 299-306.
- Elsandabesee D. and Greenwood P. (2005). The performance of Pipelle endometrial sampling in a dedicated postmenopausal bleeding clinic. *J. Obstet. Gynecol.* 25, 32-34.
- Gokaslan H., Oktem O., Durmusoglu F. and Eren F. (2003). Apoptosis in the endometrium of postmenopausal women receiving tibolone. *Gynecol. Obstet. Invest.* 56, 124-127.
- Gooyer de M.E., Overklift Vaupel Kleyn G.T., Smits K.C., Ederveen A.G.H., Verheul H.A.M. and Kloosterboer H.J. (2001). Tibolone: a compound with tissue specific inhibitory effects on sulfatase. *Mol. Cell. Endocrinol.* 183, 55-62.
- Gooyer de M.E., Deckers G.H., Schoonen W.G.E.J., Verheul H.A.M. and Kloosterboer H.J. (2003). Receptor profiling and endocrine interactions of tibolone. *Steroids* 68, 21-30.
- Greene G.L., Gilna P., Walterfield M., Baker A., Hort Y. and Shine J. (1986). Sequence and expression of human estrogen receptors cDNA. *Science* 231, 1150-1154.
- Huber J., Palacios S., Berglund L., Hänggi W., Sathanandan S.M., Christau S. and Helmond F. (2002). Effects of tibolone and continuous combined hormone replacement therapy on bleeding rates, quality of life and tolerability in postmenopausal women. *Br. J. Obstet. Gynaecol.* 109, 886-893.
- Klaassens A.H., van Wijk F.H., Hanifi-Moghaddam P., Sijmons B., Ewing P.C., Ten Kate-Booij M.J., Kooi G.S., Kloosterboer H.J., Blok L.J. and Burger C.W. (2006). Histological and immunohistochemical evaluation of postmenopausal endometrium after 3 weeks of treatment with tibolone, estrogen only, or estrogen plus progestagen. *Fertil. Steril.* 86, 352-361.
- Kloosterboer H.J. (2004). Tissue-selectivity: the mechanism of action of tibolone. *Maturitas* 48 (Suppl 1), S30-40.
- Lima S.M.R.R., Reis B.F., Yamada S.S., Postigo S., Grande R.M., Botogoski S.R., Campaner A.B., Hueb C.K. and Longo Galvão M.A. (2011). Effects of drospirenone/estradiol on steroid receptors and Bcl-2 in the postmenopausal endometrium. *Climacteric* 14, 551-557.
- Modelska K. and Cummings S. (2002). Tibolone for postmenopausal women: systematic review of randomized trials. *J. Clin. Endocrinol. Metab.* 87, 16-23.
- Morais-Socorro M., Cavalcanti M.A., Martins R., Neto Francisco P., Rezende A., Azevedo G. and Almeida M. (2012). Safety and efficacy of tibolone and menopausal transition: a randomized, double-blind placebo-controlled trial. *Gynecol. Endocrinol.* 28, 483-487.
- Mosselman S., Polman J. and Dijkema R. (1996). ER- β Identification and characterization of a novel human estrogen receptor. *FEBS J.* 392, 49-53.
- Mutter G.L. and Ferenczy A. (2002). Anatomy and histology of the uterine corpus. In: Kurman R.J. Blaustein's pathology of the female genital tract. 5th ed. New York. Springer-Verlag. pp 383-419.
- Pantaleão J.A.S., Henriques H.N., Carvalho A.C.B., Pollastri C.E., Soares Filho P.J. and Guzmán-Silva M.A. (2009). Efeito da tibolona sobre o endométrio de ratas castradas. *Rev. Bras. Ginecol. Obstet.* 31, 124-130.
- Rogers P.A.W., Lederman F., Plunkett D. and Affandi B. (2000). Bcl-2,

Effects of tibolone on the endometrium

- Fas and caspase 3 expression in endometrium from levonorgestrel implant users with and without breakthrough bleeding. *Hum. Reprod.* 15 (Suppl. 3), 152-161.
- Sitruk-Ware R. (2004). New progestogens: a review of their effects in perimenopausal and postmenopausal women. *Drugs Aging* 21, 865-883.
- Smith-Bindman R., Kerlikowske K., Feldstein V., Subak L., Scheidler J., Segal M., Brand R. and Grady D. (1998). Endovaginal ultrasound to exclude endometrial cancer and other endometrial abnormalities. *JAMA* 280, 1510-1517.
- Szlendak-Sauer K., Wierzba W. and Radowicki S. (2008). The influence of a tibolone therapy on endometrium in postmenopausal women. *Ginekol. Pol.* 79, 758-761.
- Vaskivuo T.E., Stenback F. and Tapanainen J.S. (2002). Apoptosis and apoptosis related factors Bcl-2, Bax, tumor necrosis factor-alpha, and NF-kappaB in human endometrial hyperplasia and carcinoma. *Cancer* 95, 1463-1471.
- Wagaarachchi P.T. and Sirisena J. (2000). Efficiency of Pipelle device in sampling endometrium. *Acta. Obstet. Gynecol. Scand.* 79, 793-796.
- Zheng W., Cao P., Zheng M., Kramer E.E. and Godwin T.A. (1996). p53 overexpression and Bcl-2 persistence in endometrial carcinoma: comparison of papillary serous and endometrioid subtypes. *Gynecol. Oncol.* 61, 167-174.

Accepted December 16, 2015