

Histopathological alterations in the striatum caused by *Karwinskia humboldtiana* (Buckthorn) fruit in an experimental model of peripheral neuropathy

R.N. Díaz-Pérez¹, J.A. Castillo-González¹, K. Carcaño-Díaz¹, J. García-Juárez¹, M.E. Salazar-Leal², G.E. Muñoz-Maldonado³, R. Montes-de-Oca-Luna¹, O. Saucedo-Cárdenas^{1,4} and A. Soto-Domínguez¹

¹Department of Histology, Faculty of Medicine, University Autonomous of Nuevo León, ²Department of Pharmacology and Toxicology, Faculty of Medicine, University Autonomous of Nuevo León, ³General Surgery Service, Faculty of Medicine and University Hospital "Dr. José Eleuterio González", University Autonomous of Nuevo León and ⁴Northeast Biomedical Research Centre (CIBIN) of the IMSS, Monterrey, N.L., México

Summary. The accidental ingestion of *Karwinskia humboldtiana* (*Kh*) fruit in humans and animals causes chronic or acute intoxication. Acute poisoning induces respiratory failure that progresses rapidly to death. Studies in animals intoxicated with *Kh* describe lesions in cerebral cortex, cerebellum, spinal cord, hippocampus and caudate nucleus. *Kh* intoxication in Wistar rats models the sub-lethal clinical phase observed in humans. Considering these reports, the present study analyzed the histopathological alterations within the striatum following experimental *Kh* intoxication. Twenty Wistar rats were divided into three groups (n=5) and were intoxicated with *Kh* fruit. A control group (n=5) was included. Animals were euthanized at several time points (48, 58 and 170 days post-intoxication). The brain was collected, divided and processed for conventional histology or electron microscopy. Sections were stained with hematoxylin and eosin, cresyl violet, Klüver-Barrera, and toluidine blue. Immunolabeling was performed for glial cells in the striatum, and the samples were analyzed with light microscopy. Morphometric and statistical analyses were performed. In control group, neurons, axon bundles and neuropil had a normal appearance. At 48 days, hyperchromic neurons with apparent decreased size were observed interspersed

among the normal neurons. At 58 days, we observed an increased number of hyperchromic neurons and disorganization of the myelin sheath and neuropil. At 170 days, these alterations persisted in the paralysis group. In treated groups, we observed signs of gliosis and increased axonal diameters. This study is the first report that describes the histopathological alterations within the striatum caused by chronic intoxication with *Kh* fruit in the Wistar rat.

Key words: *Karwinskia humboldtiana*, Chronic intoxication model, Striatum, Neuronal damage, Gliosis

Introduction

Karwinskia humboldtiana (*Kh*), commonly known as tullidora, capulin tullidor, cacachila, chanchanote, tuvii, pimientillo, or Coyotillo of Texas (Escobar and Nieto, 1965; Fernández-Nava, 1992), is a poisonous tree that grows extensively in Mexico, the southern United States, Central America, Caribbean countries, and northern Colombia (Knight and Watter, 2001). The immature fruit is green and becomes dark violet when matured (Padrón et al., 1951; Arreola-Nava et al., 2000). Dihydroxyanthracenone toxic compounds, known as T-514 or Peroxisomicine (PA1), T-544, T-496, and T-516 (according to their molecular weight), can be isolated from the seed and are responsible for its toxicity (Dreyer et al., 1975; Waksman et al., 1989; Rivas et al., 1990;

Bermúdez et al., 1992; Waksman and Ramirez, 1992). Depending on the amount of accidental fruit consumption, both humans and animals present acute or chronic intoxication. Signs of chronic poisoning occur 3 to 4 weeks after fruit consumption. The initial symptom is weakness in the lower extremities, which gradually ascends and finally causes a progressive, symmetrical, afebrile paralysis (Escobar and Nieto, 1965). When the affected subject survives, the recovery is gradual and spontaneous and occurs more than one year after fruit consumption (Escobar and Nieto, 1965; Aguilar and Zolla, 1982). Acute intoxication with *Kh* causes respiratory failure and rapid progression to death in the first 24-48 hours post-intoxication (Bermúdez et al., 1986). In experimental animals, severe damage to the lung, liver and kidney has been described in the absence of paralysis signs (Bermúdez et al., 1986, 1992). Most of the published reports described myelination and axonal changes in the peripheral nervous system (PNS) (Escobar and Nieto, 1965; Charlton and Pierce, 1970; Muñoz and Chávez, 1979; Muñoz et al., 1983; Bermúdez et al., 1986; Salazar et al., 2006); however, few studies have described damage in the central nervous system (CNS) during acute or chronic *Kh* intoxication in animals. These studies reported lesions in the cerebral cortex (Padrón and Velázquez, 1956; Ortíz et al., 1991; Becerra et al., 2009), cerebellum (Padrón and Velázquez, 1956; Escobar and Nieto, 1965; Charlton and Pierce, 1970; Becerra et al., 2009), spinal cord (Padrón and Velázquez, 1956; Escobar and Nieto, 1965; Charlton and Pierce, 1970; Becerra et al., 2009), hippocampus (Ortíz et al., 1991), caudate nucleus (Ortíz et al., 1991), vestibular nuclei (Becerra et al., 2009), and pons (Padrón and Velázquez, 1956; Becerra et al., 2009). Among these experimental studies, there are many animal species, routes of administration, and doses; however, the same histopathological lesions are observed: hyperchromic neurons with reduced volumes; decreased number of neurons, and neuronal chromatolysis and tigrolisis. Other findings include gliosis, segmental demyelination with axon thickening, and Wallerian degeneration. In a previous study, we reported that *Kh* intoxication in the Wistar rat models the sub-lethal clinical phase in humans (Salazar et al., 2006), and several studies have used this model to investigate alterations in the CNS (Becerra et al., 2009); damage in the liver, kidney and lung (García, 2013; García et al., 2013a,b); and the effect of lipoic acid treatment (García-Juárez et al., 2012). The striatum, part of the basal ganglia, is related to the control of movement, behavior, memory and learning. The striatum receives inputs from the cerebral cortex and other areas of the CNS, such as the thalamus and brainstem. Additionally, the fibers are topographically represented from the cerebral cortex to the striatum (McGeorge and Faull, 1989). Histologically, the striatum is composed of gray matter with neuronal cell bodies and neuroglial cells immersed in neuropil with multiple myelinated nerve fascicles that correspond to the afferent and efferent projections to other areas of

the CNS, such as the cerebral cortex (Haber and Johnson, 2004). Because the motor pathway of the CNS demonstrate morphological alterations in this experimental model of *Kh* intoxication (Becerra et al., 2009), we analyzed the striatum as an integrating center of different areas of the CNS in this model of peripheral neuropathy.

Materials and methods

Kh fruit collection

In this study, the *Kh* fruit was collected in Hidalgo, Nuevo León in northern México in November 2012. The biological activity was confirmed by the Department of Analytical Chemistry, Faculty of Medicine, UANL.

Experimental animals

The experimental model was produced according to the method described by Salazar et al. (2006). Twenty female Wistar rats weighing 195 ± 25 g were divided into four groups. Three experimental groups ($n=5$) were intoxicated with dried, ground and sieved fruit that was dissolved in water and administered through an orogastric tube. The first dose was 1.5g/kg weight, and 4 subsequent doses of 0.5 g/kg were administered on days 3, 7, 10 and 14. The day of the first *Kh* fruit administration was considered to be day 0. The control group (AC; $n=5$) received water.

The rats were maintained on a standard laboratory diet with *ad libitum* water access and a 12 hour light and dark cycle in the animal facility of the Department of Histology, Faculty of Medicine, UANL. The experiments were performed in accordance with the International Guidelines on the Appropriate Use of Experimental Animals and according to the Mexican Norm NOM-062-ZOO-1999 on the Technical Specifications for the Production, Care and Use of Laboratory Animals (SAGARPA, 1999). The protocol was approved by the Bioethical Committee of the Faculty of Medicine, UANL in Monterrey, Nuevo León, México.

Evaluation of clinical manifestations

Clinical manifestations, such as weight loss, piloerection, weakness in the lower and upper limbs, paralysis, and respiratory difficulty, were evaluated and recorded throughout the experiment.

Tissue collection

The rats were euthanized with a single dose of pentobarbital (80 mg/kg) intraperitoneally at 48 (group of paresis), 58 (group of paralysis) and 170 days (recovery group). The animals were perfused through the left ventricle with a perfusion pump with PBS (1X) followed by paraformaldehyde (4% in PBS1X).The

Striatal alterations caused by *Karwinskia humboldtiana* fruit

brains were collected and divided into left and right hemispheres that were immersed in 4% paraformaldehyde until processing.

Histological and histochemical analyses

The right hemispheres were processed for conventional histology and embedded in paraffin blocks. The striatum was identified according to the Paxinos coordinate description (Paxinos and Watson, 2005). Histological sections (5 μ m thickness) were stained with hematoxylin and eosin (H&E) for histological analysis.

For the histochemical evaluation, 10- μ m sections were stained with Cresyl Violet (CV) (Einarson, 1932) to evaluate the neuronal bodies or with the Klüver–Barrera method (Klüver and Barrera, 1953) to evaluate the myelin within the nerve tracts.

Semi-thin sections

From the left hemisphere, the striatum was dissected, minced and fixed by immersion in Karnovsky-Ito fixative (Ito and Karnovsky, 1968). Then, the samples were post-fixed in osmium tetroxide and processed for transmission electron microscopy and placed in epoxy resins blocks. Semi-thin sections were obtained by ultramicrotomy; stained with 1% toluidine blue; and analyzed by light microscopy.

Identification of neuroglial populations in striatum

To determine whether *Kh* intoxication induced changes in the glial cells within the striatum, histological sections (4- μ m thickness) were incubated with specific antibodies to identify each population: anti-Glial Fibrillary Acidic Protein (GFAP) (1:200) for astrocytes; anti-S-100 protein (1:200) for oligodendrocytes; and anti-ionized calcium binding adapter molecule-1 (Iba1) (1:200) for microglia. The Envision[®] system was used for detection. Positivity was identified with 3, 3'-diaminobenzidine (DAB), and the nuclei were contrasted with Mayer's hematoxylin. As a negative control, the monoclonal antibody was omitted. The samples were analyzed by light microscopy. The GFAP and S-100 antibodies and the detection system were purchased from Dako Cytomation, Inc[®] (Carpinteria, California; USA). The Iba1 antibody was purchased from Abcam[®] (Cambridge, Massachusetts; USA).

Morphometric analysis

The morphometric evaluation for every item was performed as follows. To quantify damaged neurons, twenty-four random fields were chosen from sections stained with CV at 40x (eight fields/slide; three slides/rat; three rats/group).

We also analyzed changes in axonal diameter. To distinguish between thick and thin axons in semi-thin sections, 2,500 axons/group were counted (500

axons/field at 100x; five fields/rat; five rats/group).

For immunolabeled sections of astrocytes, oligodendrocytes and microglia, sixteen fields at 40x (eight fields/slide; one slide rat; two rats/group) were imaged to quantify the number of positive cells/field. We compared the variations of these cell populations within the striatum. Digital high-resolution images were obtained with a Nikon Microscope Eclipse 50i, and an image analysis system Digital Sight dDS-2Mu. Standard deviations and variances were calculated, and Student's t-tests were performed with the statistics software SPSS program v.16. We compared the control vs experimental groups, and a value of $p \leq 0.05$ was considered significant.

Results

Clinical manifestations

The control group did not exhibit any clinical manifestations, such as weight loss, piloerection, weakness in the lower and upper limbs, paralysis, respiratory difficulty, or other signs. However, animals treated with *Kh* fruit exhibited these manifestations at 48 and 58 days. At 170 days post-intoxication, only piloerection remained in the clinically recovered animals (Table 1).

Histological and histochemical evaluations

In sections from the control group stained with H&E and CV, we observed normal histology of the striatum, including groups of rounded neurons with scant cytoplasm and euchromatic nuclei with prominent nucleoli. Smaller nuclei with compact chromatin and little cytoplasm (corresponding to glial cells) were also observed (Fig. 1A). In animals treated with *Kh* fruit, we observed progressive increments of damaged neurons compared to the control group. In the paresis group,

Table 1. Clinical manifestations of the rats during intoxication with *Kh* fruit.

Clinical manifestations	Paresis (48 days)	Paralysis (58 days)	Recovery (170 days)
Piloerection	+	+	+
Respiratory difficult	+	+	-
Weakness	+	+	-
Walk alterations	+	+	-
Muscular atrophy	+	+	-
General sickness	+	+	-
Spinal deformity	+	+	-
Claw hand	-	+	-
Paralysis	-	+	-
Polineuropathy disappears	-	-	+
Improvement of the general condition	-	-	+

(+) present, (-) absent

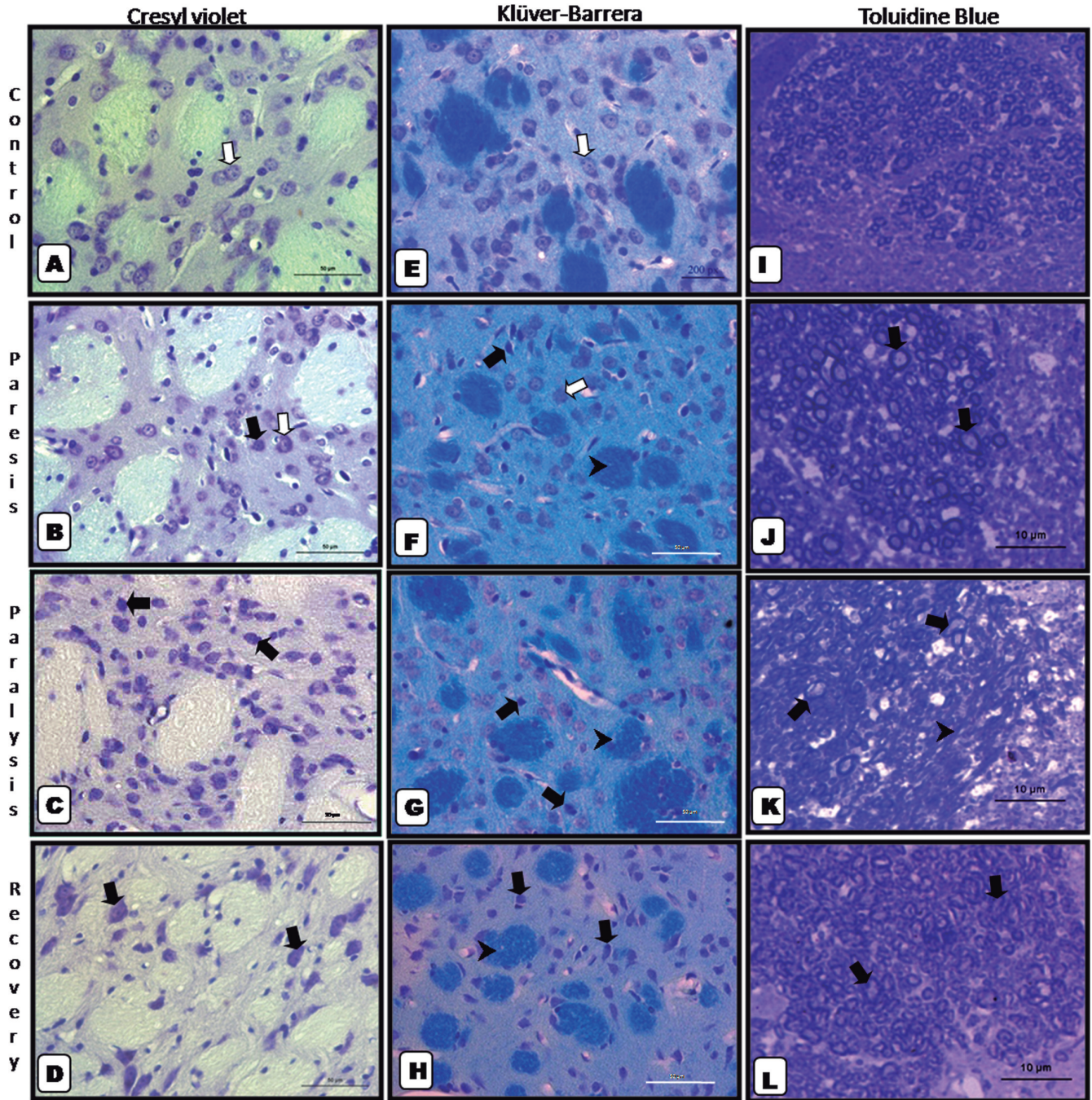


Fig. 1. Histopathological alterations in neurons of the striatum. **A.** Control group: neuronal bodies with normal appearance (white arrow). **B.** Paresis group: hyperchromic neurons with decreased size (black arrow) and normal-appearing neurons (white arrow). **C.** Paralysis group: predominance of normal neurons with few hyperchromic neurons (black arrows). **D.** Recovery group: damaged neuronal bodies persist (black arrows). Alterations in myelin sheath. **E.** Control group: bundles of axons with intact myelin and normal neurons (white arrow). **F.** Paresis group: bundles of axons with clear vesicles (arrowhead), hyperchromic neurons (black arrow), and normal-appearing neurons (white arrow). **G.** Paralysis group: fascicles of axons with increased clear vesicles (arrowhead) and hyperchromic neurons (black arrows). **H.** Recovery group: persistence of axon bundles with white vesicles (arrowhead) and hyperchromic neurons (black arrows). Alterations in axonal diameter. **I.** Control group: fascicles of axons with normal appearance. **J.** Paresis group: fascicles with increased diameters (black arrows) among normal-appearing axons. **K.** Paralysis group: axons with increased caliber, disruption of the myelin sheath (black arrows) and areas of axonal lysis (arrowhead). **L.** Recovery group: disruption of the myelin sheaths and axons with increased sizes (black arrows). **A-D:** Cresyl violet, **E-H:** Klüver-Barrera. Paraffin-embedded, light micrograph, 50- μ m bar. **I-L:** Toluidine blue. Epoxy-embedded, light micrograph. Scale bar: 10 μ m.

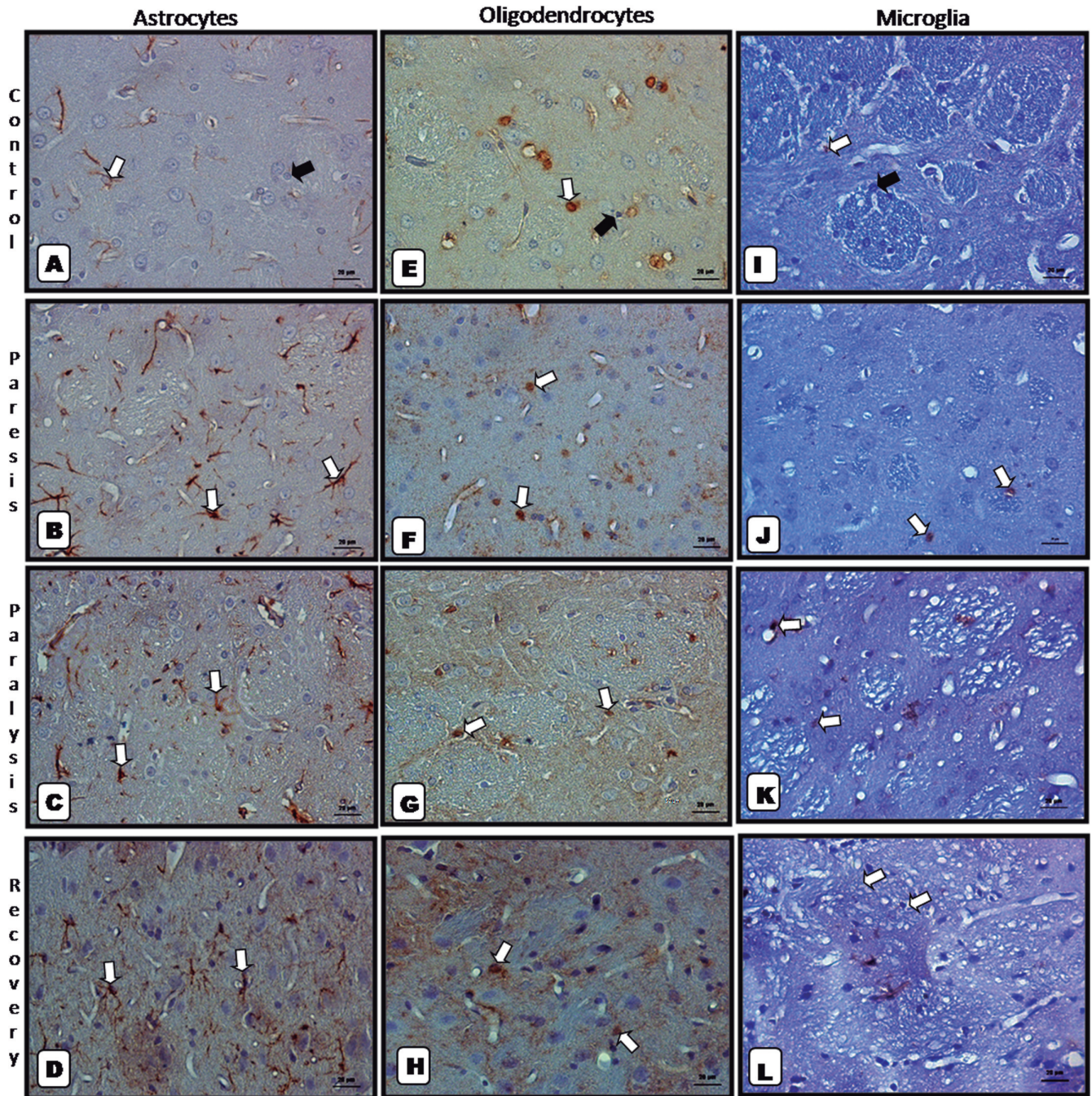


Fig. 2. Immunolabeling of glial cells within the striatum demonstrating gliosis. **A.** Control group: astrocytes positive for GFAP protein (white arrow) and negative cells (black arrow). **B.** Paresis group: increased number of positive cells (white arrows). **C.** Paralysis group: positive cells (white arrows). **D.** Recovery group: remaining abundant positive cells (white arrows). Identification of oligodendrocytes. **E.** Control group: oligodendrocytes positive for S-100 protein (white arrow) and negative cells (black arrow). **F.** Paresis group: positive cells without an apparent increase in labeling (white arrows). **G.** Paralysis group: positive oligodendrocytes without changes in quantity (white arrows). **H.** Recovery Group: positive cells (white arrows). Identification of microglia. **I.** Control group: microglia positive for Iba1 protein (white arrow) and negative cells (black arrow). **J.** Paresis group: few positive cells (white arrows). **K.** Paralysis group: positive cells (white arrows). **L.** Recovery group: positive cells remained scarce (white arrows). Paraffin-embedded, light micrograph, Immunohistochemistry. Scale bar: 20 μ m.

normal neurons were interspersed among hyperchromic neurons that appeared obviously decreased in size (Fig. 1B). In the paralysis group, hyperchromic damaged neurons with pyknotic nuclei and decreased size increased (Fig. 1C). In the recovery group, hyperchromatic damaged neurons persisted (Fig. 1D).

In sections stained with the Klüver-Barrera method, the control group displayed fascicles of axons with uniform blue-stained myelin and organized neuropil with normal appearances (Fig. 1E). The paresis group displayed fascicles of axons with vacuoles in the myelin and a disorganized neuropil (Fig. 1F). In the paralysis group, these alterations worsened (Fig. 2G). In the recovery group, these alterations persisted (Fig. 1H).

Semi-thin evaluation

In the semi-thin sections of the control group stained with toluidine blue, we observed nerve fascicles of axons with different calibers and normal histologic characteristics; this group also displayed an organized myelin sheath (Fig. 1I). The paresis group displayed fascicles of axons with normal appearances alternated with axons that were increased in caliber and vacuoles in the myelin sheath (Fig. 1J). In the paralysis group, we observed more alterations in the myelin sheath with thinning of the sheath in some areas and axonal lysis (Fig. 1K). In the recovery group, we observed increased axonal sizes and disorganization of the myelin sheath (Fig. 1L).

Immunohistochemical evaluation

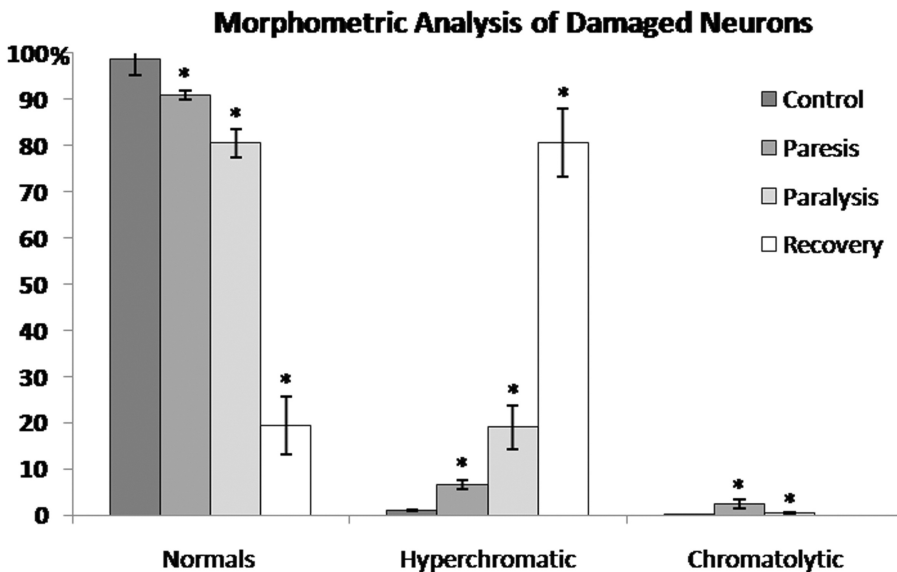
In the control and treated groups, dark brown positive glial cells were detected, and the negative cells were stained only with Mayer's hematoxylin. The

astrocytes exhibited the characteristic star-shape with long, thin projections that contacted the continuous capillaries of the striatum (Fig. 2A). Additionally, oligodendrocytes were observed with rounded nuclei and some projections (Fig. 2E), and microglia cells demonstrated an ovoid morphology with triangular nuclei and some projections (Fig. 2I) (all with normal appearances).

In the paresis and paralysis groups, gliosis was observed. Specifically, an apparent increase in the number of gliotic astrocytes was evident in the recovery group (Fig. 2B-D). The appearance of the oligodendrocytes (Fig. 2F-H) and microglia resembled the control group (Fig. 2J-L).

Morphometric analysis

We observed progressive damage to neurons in rats treated with *Kh* fruit. The changes in normal neurons were observed with the histological and histochemical analyses. The control group demonstrated $98.58\% \pm 3.50$; the paresis group demonstrated $90.89\% \pm 5.25$; the paralysis group demonstrated $80.45\% \pm 3.02$; and the recovery group demonstrated $19.39\% \pm 6.34$. Quantification of the damaged neurons indicated increasing numbers of hyperchromic neurons that was time-dependent in the intoxication groups. Hyperchromic neurons were the predominating population in the recovery group compared to the control group. The percentages of hyperchromic neurons were $1.09\% \pm 0.08$, $6.68\% \pm 2.27$, $19.02\% \pm 4.72$, and $80.60\% \pm 7.30$ in the control, paresis, paralysis, and recovery groups, respectively. Finally, the number of neurons with chromatolysis was very low ($0.32\% \pm 0.04$, $2.41\% \pm 1.31$, $0.52\% \pm 0.18$, and 0% in the control, paresis, paralysis, and recovery groups, respectively). The experimental



Graph 1. Morphometric analysis of damaged neurons: control group, paresis, paralysis, recovery. We observed a gradual decrease in the percentage of normal neurons in the paresis and paralysis groups, which was more evident in the recovery group. An increasing percentage of hyperchromic neurons was observed in these same groups. There were few neurons exhibiting chromatolysis (all groups). When comparing the experimental groups vs the control group, significance was set at $p \leq 0.05$.

Striatal alterations caused by *Karwinskia humboldtiana* fruit

groups were significantly different the control group (Graph. 1).

We quantified the diameter of the axons with semi-thin sections. We observed a greater number of thin axons in the recovery group, and the paresis group demonstrated a significant decrease in the number of thin axons. The percentages of thin axons were $77.84\% \pm 6.42$, $67.40\% \pm 2.98$, $69.90\% \pm 5.58$, and $80.46\% \pm 4.11$ in the control, paresis, paralysis, and recovery groups, respectively. The paresis and paralysis groups were significantly different ($p \leq 0.05$) from the control group.

We also quantified the number of thick axons. Only the paresis group demonstrated more thick axons than the control group. The percentages of thick axons were $21.24\% \pm 6.56$, $32.72\% \pm 2.92$, $29.85\% \pm 5.28$, and $26.05\% \pm 4.11$ in the control, paresis, paralysis, and recovery groups, respectively. The number of thick axons tended to increase in the paresis and paralysis groups, and gradually decreased (to the recovery group values). This difference was not significant (Graph. 2).

The morphometric analysis of the glial subpopulations identified with specific antibodies revealed a progressive increase in the number of astrocytes in the treated groups. The control group demonstrated an average of $14.00\% \pm 4.24$. The paresis group demonstrated an average of $21.00\% \pm 0.70$. The paralysis group demonstrated an average of $48.00\% \pm 8.48$. The recovery group demonstrated an average of $31.00\% \pm 7.07$. All treated groups were significantly different from the control group ($p \leq 0.05$; Graph. 3A).

The percentage of oligodendrocytes in the control group was $51.00\% \pm 15.55$. The percentage of oligodendrocytes increased in the paresis group to $84.00\% \pm 16.26$, but decreased in the paralysis group to

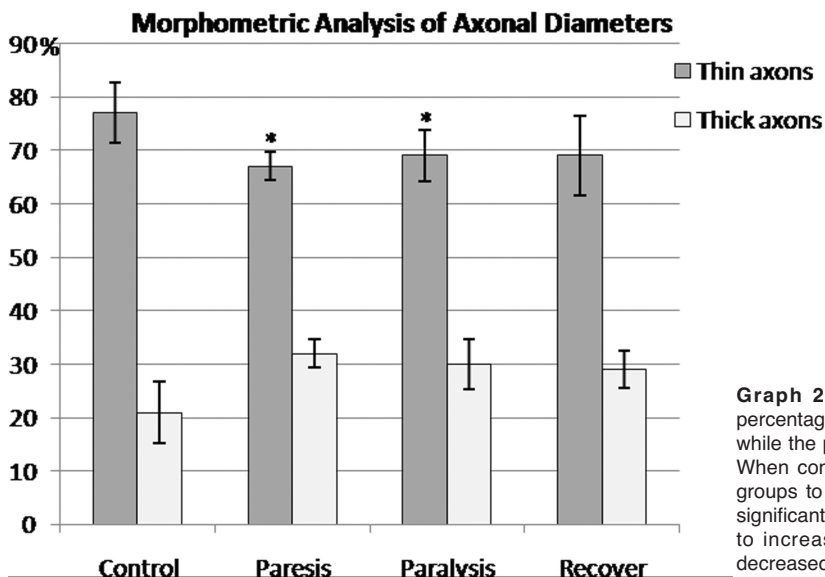
$68.00\% \pm 9.19$. The percentage of oligodendrocytes in the recovery group was $54.00\% \pm 7.07$. Only the paresis group was significantly different from the control group ($p \leq 0.05$; Graph. 3B).

The percentage of microglia in the control group was $16.00\% \pm 3.53$. The paresis group demonstrated a decreased percentage of microglia ($11.00\% \pm 2.82$). The percentage of microglia in the paralysis group was $18.00\% \pm 0$. The percentage of microglia in the recovery group was $13.00\% \pm 2.82$. Only the paresis group was significantly different from the control group ($p \leq 0.05$; Graph. 3C).

Discussion

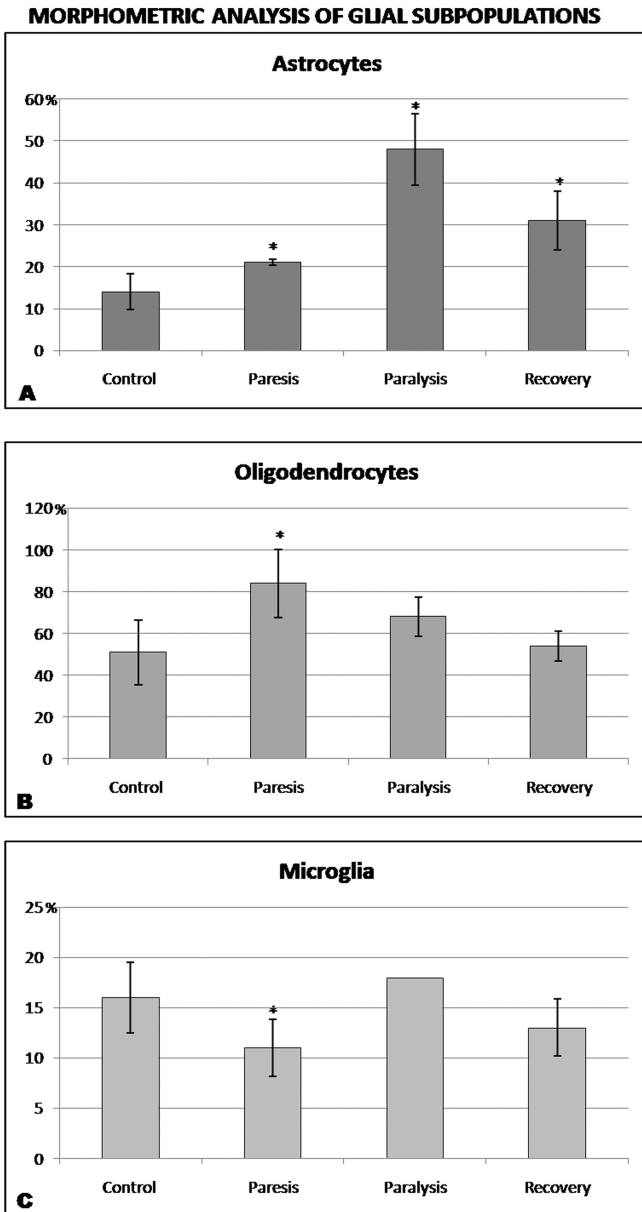
This study is the first to describe the histopathological alterations in the striatum caused by *Kh* fruit in an experimental model of peripheral neuropathy. These alterations began at 24 hours post-intoxication and remained at 170 days post-intoxication. We observed an increased number of hyperchromic and chromatolytic neurons, abundant vacuolated spaces in the axon bundles, axonal swelling, disorganization of the neuropil, and gliosis. These signs agree with the findings reported by Becerra et al. (2009) in other areas of the CNS, such as the motor cortex, cerebellum, spinal cord, vestibular nucleus, and corticopontocerebellar tract (Becerra et al., 2009). Our study also demonstrates that intoxication with *Kh* fruit affects other areas of the CNS differently than the PNS (Salazar et al., 2006).

Clinical manifestations, such as weight loss, ocular secretion, hair bristling, weakness, and respiratory difficulty, were analyzed in rats intoxicated with *Kh* fruit. These manifestations were present in the paresis group at 48 days, were more evident at 58 days in the paralysis group, and almost all of the symptoms resolved



Graph 2. Morphometric analysis of axonal diameters: The percentage of thin axons decreased in groups treated with *Kh* fruit, while the percentage of thick axons increased in these same groups. When comparing the percentage of thin axons in the experimental groups to the control group, the paresis and paralysis groups were significantly different ($p \leq 0.05$). The percentage of thick axons tended to increase in the paresis and paralysis groups, and gradually decreased toward the recovery group (not significant).

in the recovery group, which only presented with piloerection. These results agree with other studies regarding the clinical signs in humans and animals



Graph. 3. Morphometric analysis of glial subpopulations. **A.** Average of astrocytes positive to GFAP in study groups. A gradual increase of astrocytes is observed in the intoxicated groups vs control group. All intoxicated groups presented statistical difference ($p \leq 0.05$). **B.** Average of oligodendrocytes positive to S-100 protein in control group and experimental groups. Only the paresis group showed an increase of oligodendrocytes that gradually decreased in paralysis and recovery groups. Paresis group presents statistical difference vs control group, ($p \leq 0.05$). **C.** Average of microglial cells positive to Iba1 in control and experimental groups. Group of paresis showed a statistical significance decrease in this population. The paralysis and recovery groups did not show statistically significant difference ($p \leq 0.05$).

intoxicated with *Kh* fruit (Padrón, 1951; Padrón and Velázquez, 1956; Bermúdez et al., 1986, 1992; Salazar et al., 2006, García-Juárez et al., 2012).

One of the notable features of this intoxication is weakness and paralysis in the lower and upper limbs (Escobar and Nieto, 1965). The striatum is associated with the control of movements (McGeorge and Faull, 1989; Buffone and Dalto, 2013). The histopathological alterations observed in neurons in this region may be related to the weakness, gait alterations and paralysis.

In this study, we also observed progressively increased numbers of hyperchromic neurons with decreased size in the paresis and paralysis groups. These hyperchromic neurons remained present in the recovery groups. The degenerating neurons are characterized at the light microscopic level by cell body shrinkage, loss of Nissl substance, intensely stained cytoplasm, and a small/shrunken darkly stained (pyknotic) nucleus that may eventually fragment (Garman, 2011). Similar results (hyperchromic and chromatolytic neurons) have been described in experimental animals intoxicated with *Kh* by investigators studying others areas of the CNS, such as the spinal cord (Padrón and Velázquez, 1956; Escobar and Nieto, 1965; Charlton and Pierce, 1970; Becerra et al., 2009), cerebral cortex (Padrón and Velázquez, 1956; Ortíz et al., 1991; Becerra et al., 2009), cerebellum (Padrón and Velázquez, 1956; Escobar and Nieto, 1965; Charlton and Pierce, 1970; Becerra et al., 2009), hippocampus (Ortíz et al., 1991), caudate nucleus (Ortíz et al., 1991), vestibular nuclei (Becerra et al., 2009), and pons (Padrón and Velázquez, 1956; Becerra et al., 2009).

Previously, were ported alterations in the cerebral cortex in this model of intoxication (Becerra et al., 2009), which was characterized by an increased number of hyperchromic neurons in the paresis group compared to the paralysis and recovery groups. In this study, we observed fewer hyperchromic neurons in the paresis group and more in the paralysis group. These hyperchromic neurons remained present in the recovery group. Additionally, Becerra et al. (2009) described that chromatolytic neurons were present during paresis, increased during paralysis and peaked during recovery. This finding suggests that alterations in neurons within the striatum might be secondary to cerebral cortex alterations, because no changes were observed in chromatolytic neurons.

Furthermore, chromatolysis appears as a reaction to axonal injury (Schwab and Bartholdi, 1996). The striatum is crossed by multiple bundles of myelinated axons corresponding to the afferent and efferent nerve projections from other CNS areas, such as the cerebral cortex (Haber and Johnson, 2004). Previously, we reported alterations in myelin and axons in the cerebral cortex (Becerra et al., 2009); therefore, this observation could be related to the spaces in the myelin, swelling axons in the striatum, and changes in the linear parallel array of axons in the experimental groups. Similar alterations in the striatum have been described for

Striatal alterations caused by *Karwinskia humboldtiana* fruit

several toxic compounds (Flint-Beal et al., 1993; Spencer et al., 1993; Santoyo et al., 2007; Ríos et al., 2009; Zarazúa et al., 2010; Fuentes-Bello et al., 2013).

Another histopathological alteration observed in the striatum was gliosis characterized by an increased number of astrocytes in the treated groups. In animals intoxicated with *Kh*, gliosis has been reported in the CNS with hyperchromic and pyknotic neurons (Escobar and Nieto, 1965; Ortíz et al., 1991; Becerra et al., 2009). This proliferation of glial cells could be related to the spaces present following the shrinkage of damaged neurons, and/or the vacuolization of myelinated axon bundles. Plant toxins can cause gliosis in the CNS (Pomilio et al., 1989; Flint-Beal et al., 1993; Carod-Artal, 2003; Soto-Blanco and Lima-Górniak, 2010; Dikibo et al., 2012; Gotardo et al., 2012; Bhasker et al., 2014) similar to the gliosis described in this study.

The histopathological alterations observed in the striatum agree with reports of damage in other areas of the CNS in experimental animals intoxicated with *Kh* fruit with distinct doses and administrations. These results will help determine whether this intoxication also affects other areas of the CNS that are related to the striatum, such as the substantia nigra, thalamus and brainstem. Future studies will be required to elucidate the sequence of events in the analyzed areas of the CNS and/or the mechanism of damage. Currently, studies (*in vitro* and *in vivo*) related to the aforementioned observations are being performed in our laboratory and others to evaluate the effect of toxins isolated from the *Kh* seed, such as T-514.

Acknowledgements. This study was supported by a grant from PROMEP/103.5/12/7884 apoyo a la incorporación de nuevos PTC. We acknowledge Luis I. Botello Soto and Lorenzo Rada Castañeda for their technical assistance during the sample processing and Patricia W. for reviewing the English manuscript.

Conflicts of interest: none.

References

- Aguilar A. and Zolla C. (1982). Plantas tóxicas de México. Instituto Mexicano del Seguro Social. México. D. F. 271p.
- Arreola Nava M.E., Vázquez Castellanos J.L. and González Castañeda M.E. (2000). Factores geográficos en la epidemiología de la intoxicación por *Karwinskia* (tullidora) en México. *Cad. Saúde Pùb, Río de Janeiro*. 16, 255-260.
- Bhasker A.S., Sant B., Yadav P., Agrawal M. and Lakshmana Rao P.V. (2014). Plant toxin abrin induced oxidative stress mediated neurodegenerative changes in mice. *Neurotoxicol.* 44, 194-203.
- Becerra-Verdín E.M., Bermúdez-Barba M.V., Salazar-Leal M.E., Ancer Rodríguez J., Romero-Díaz V., Soto-Domínguez A., Ballesteros-Eliozondo R.G., Saucedo-Cardenas O., Piñeyro Lopez A. and Sepúlveda-Saavedra J. (2009). *Karwinskia humboldtiana* (buckthorn) fruit causes Central Nervous System damage during chronic intoxication in the rat. *Toxicon* 53, 645-651.
- Bermúdez M.V., González-Spencer D., Guerrero M., Waksman N. and Piñeyro A. (1986). Experimental intoxication with fruit and purified toxins of buckthorn (*Karwinskia humboldtiana*). *Toxicon* 24, 1091-1097.
- Bermúdez M.V., Martínez F.J., Salazar M.E., Waksman N. and Piñeyro A. (1992). Experimental acute intoxication with ripe fruit of *Karwinskia humboldtiana* (tullidora) in rat, guinea-pig hamster and dog. *Toxicon* 30, 1493-1496.
- Buffone G.D. and Dalto D. (2013). Anatomía funcional del cuerpo estriado y la corteza cerebral: su relación con el movimiento. 10° Congreso Argentino y 5° Latinoamericano de Educación Física y Ciencias. La Plata, September 9-13, 2013.
- Carod-Artal F.J. (2003). Síndromes neurológicos asociados con el consumo de plantas y hongos con componente tóxico (I). Síndromes neurotóxicos por ingesta de plantas, semillas y frutos. *Rev. Neurol.* 36, 860-871.
- Charlton K.M. and Pierce K.R. (1970). A neuropathy in goats caused by experimental Coyotillo (*Karwinskia-humboldtiana*). Poisoning, part V: lesions in the central nervous system. *Pathol. Vet.* 7, 435-447.
- Dikibo E., Ehimigbai J., Eloka C.C.V., Ekoh S.N., Ezeah G.A.C. and Okoro C.J. (2012). The effect of mondia whitei on the histology of the brain of wistar rat. *Int. J. Herbs Pharmacol. Res.* 1, 62-67.
- Dreyer D.L., Arai I., Bachman C.D., Anderson W.R., Smith R.G. and Daves G.D. (1975). Toxins causing non inflammatory paralytic neuropathy. Isolation and structure elucidation. *J. Am. Chem. Soc.* 97, 4985-4990.
- Escobar A. and Nieto D. (1965). Aspectos neuropatológicos de la intoxicación con *Karwinskia humboldtiana*. Estudio experimental. *Gac. Med. Mex.* 95, 163-177.
- Einarson L. (1932). A method for progressive selective staining of Nissl and nucleus substance in nerve cells. *Am. J. Pathol.* 8, 295-308.
- Fernández-Nava R. (1992). Nombres comunes, usos y distribución geográfica del género *Karwinskia* (Rhamnaceae) en México. *Anales Inst. Biol. Univ. Nac. Autón. México, Ser. Bot.* 63, 1-23.
- Flint Beal M., Brouillet E., Jenkins B.G., Ferrante R.J., Kowall N.W., Miller J.M., Storey E., Srivastava R., Rosen B.F. and Hyman B.T. (1993). Neurochemical and histologic characterization of striatal excitotoxic lesions Produced by the mitochondrial toxin 3-nitropropionic Acid. *J. Neurosc.* 13, 4181-4192.
- Fuentes-Bello A.C., Pérez-Carrera D., Pérez-de la Cruz V., Santamaría-del Ángel A. and Carrillo-Mora P. (2013). Efectos a largo plazo de la coadministración subtóxica de ácido 3-nitropropiónico y ácido quinolínico en el estriado de rata. *Invest. Discap.* 2, 3-11.
- García G.R. (2013). Evaluación morfológica de hígado, riñón y pulmón en un modelo de intoxicación crónica con el fruto maduro de *Karwinskia humboldtiana* en la Rata Wistar. Tesis de Doctorado. Facultad de Medicina. UANL. <http://www.remeri.org.mx/portal/REMERI.jsp?id=oai:tesis.uanl.mx:1080240827>.
- García G.R., Salazar L.M.E., Becerra V.E.M., Romero D.V., García J.J., Soto D.A. and Sepúlveda S.J. (2013a). Células cebadas en pulmón y nervio periférico en la intoxicación crónica con *Karwinskia humboldtiana* en rata wistar: estudio histológico e histoquímico. *Int. J. Morphol.* 31, 1216-1222.
- García G.R., Salazar L.M.E., Romero D.V., García J.J., Soto D.A., Juárez R.O.A. and Sepúlveda S.J. (2013b). Intoxicación crónica con el fruto maduro de *Karwinskia humboldtiana* en ratas wistar: daño renal. *Int. J. Morphol.* 31, 1449-1454.
- García-Juárez J., Salazar-Leal M.E., Guzmán-López S., Romero-Díaz V.J., Ramírez-Durón R. and Sepúlveda-Saavedra J. (2012). Evaluación del efecto del tratamiento con ácido lipoico administrado a la Rata Wistar intoxicada con el Fruto de *Karwinskia*

Striatal alterations caused by Karwinskia humboldtiana fruit

- humboldtiana. *Int. J. Morphol.* 30, 572-578.
- Garman R.H. (2011). Histology of the central nervous system. *Toxicol. Pathol.* 39, 22-35.
- Gotardo A.T., Schumacher B.H., Pfister J.A., Traldi A.S., Maiorka P.C., Spinosa H.S. and Górnica S.L. (2012). The use of ultrasonography to study teratogenicity in ruminants: evaluation of *Ipomoea carnea* in goats. *Birth Defects Res. B Dev. Reprod. Toxicol.* 95, 289-295.
- Haber S.N. and Johnson M. (2004). The basal ganglia. In: *The human nervous system*, Second ed. Chapter 21. pp 676-737.
- Ito S. and Karnowsky M. (1968). Formaldehyde-glutaraldehyde fixative containing trinitro compounds. *J. Cell Biol.* 39, 168a-9a.
- Knight A.P. and Watter R.G. (2001). *A guide to plant poisoning of animals in North America*. Teton New Media Jackson.
- Klüver H. and Barrera E. (1953). A method for the combined staining of cells and fibres of nervous system. *J. Neuropathol. Exp. Neurol.* 12, 400-403.
- Mc George A.J. and Faull R.L. (1989). The organization of the projection from the cerebral cortex to the striatum in the rat. *Neuroscience* 29, 503-537.
- Muñoz M.E. and Chávez B. (1979). Conduction block and functional denervation caused by *tullidora* (*Karwinskia humboldtiana*). *Exp. Neurol.* 65, 255-270.
- Muñoz M.E., Chavez B. and Nathan J. (1983). Denervation caused by *tullidora* (*Karwinskia humboldtiana*). *Neuropathol. Appl. Neurobiol.* 9, 121-134
- Ortiz G.G., González B.J. and Feria V.A. (1991). Structural study of the acute effect of *Karwinskia humboldtiana* on cerebral motor cortex, hippocampus and caudate nucleus of the rat. *Gen. Pharmacol.* 23, 543-547.
- Padrón F. (1951). Estudio clínico experimental de la parálisis por *Karwinskia humboldtiana* (*tullidora*) en niños. *Gac. Med. Mex.* 81, 300-311.
- Padrón F. and Velázquez T. (1956). Patología experimental y clínica de la parálisis por *Karwinskia humboldtiana*. *Rev. Mex. Ped.* 25, 225-237.
- Paxinos G. and Watson C. (2005). *The brain in stereotaxic coordinates*, fifth ed. Elsevier Academic Press, San Diego California.
- Pomilio A.B., Rofi R.D., Gambino M.P., Mazzini C.A. and Debenedetti de Langenheime R.T. (1989). The lethal principle of *Poa huecu* (Coiron Blanco): a plant indigenous to Argentina. *Toxicon.* 27, 1251-1262.
- Ríos R., Santoyo M.E., Sepúlveda-Saavedra J., Romero-Díaz V., Jiménez V., Delgado J.M. and Jiménez-Capdeville M.E. (2009). Morphological changes in the striatum of arsenic exposed rats. *J. Neurochem.* 110, 226.
- Rivas V., Torres R. and Waksman N. (1990). Dimeric anthracenones from *Karwinskia* species. *J. Med. Plant. Res.* 56, 562-564.
- SAGARPA (1999). Norma Oficial Mexicana NOM-062-ZOO-1999, Especificaciones técnicas para la producción, cuidado y uso de los animales de laboratorio.
- Salazar L.M., Flores M.S., Sepúlveda S.J., Romero-Díaz V.J., Becerra-Verdin E.M., Tamez-Rodríguez V.A., Martínez H.R., Piñeyro-Lopez A. and Bermudez M.V. (2006). An experimental model of peripheral neuropathy induced in rats by *Karwinskia humboldtiana* (buckthorn) fruit. *J. Peripher. Nerv. Syst.* 11, 253-261.
- Santoyo M.E., Sepúlveda-Saavedra J., Zarazúa S., Pérez-Severiano F., Romero-Díaz V.J., Ceballos F., Juárez B.I. and Jiménez-Capdeville M.E. (2007). Neurochemical and morphological alterations in the rat brain associated with chronic arsenic exposure. In: *New perspectives on brain cell damage, neurodegeneration and neuroprotective strategies*. Santamaría A. and Jiménez-Capdeville M.E. (eds) Research Signpost.
- Schwab M.E. and Bartholdi D. (1996). Degeneration and regeneration of axons lesioned spinal cord. *Physiol. Rev.* 76, 319-370.
- Spencer P.S., Ludolph A.C. and Kisby G.E. (1993). Neurological diseases associated with use of plant components with toxic potential. *Environ. Res.* 62, 106-113.
- Soto-Blanco B. and Lima-Górnica S. (2010). Toxic effects of prolonged administration of leaves of cassava (*Manihot esculenta* Crantz) to goats. *Exp. Toxicol. Pathol.* 62, 361-366.
- Waksman N. and Ramirez R. (1992). Isolation of a new dimeric anthracenone from *Karwinskia parvifolia*. *Rev. Latinoamer. Quim.* 23, 25-27.
- Waksman N., Martínez L. and Fernández R. (1989). Chemical and toxicological screening in genus *Karwinskia*. *Rev. Latinoamer. Quim.* 20, 27-29.
- Zarazúa S., Ríos R., Delgado J.M., Santoyo M.E., Ortiz-Pérez D. and Jiménez-Capdeville M.E. (2010). Decreased arginine methylation and myelin alterations in arsenic exposed rats. *NeuroToxicology* 31, 94-100.